

Agenesia ductus venoso con drenaje extrahepático

A PROPÓSITO DE UN CASO

Angela Ruiz Pons; Itziar Callejo Iribarren; Laura Fuertes Cortés; Laia Vila Homs; Miriam Crespo Rodriguez; Andrea Alegre Garcia; Maria Vila Cortés; Marta Forteza Torrens; Marina Sanmartin Novell; Maria del Mar Mas Morey; Inés Maria Pomar Mora; Maria Helena Tur Torres; Celia Garrido Palmer; Rebeca Sánchez Salmador; Ana Arias Medina; Rosa Maria Ruiz de Gopegui Valero; Octavi Córdoba Cardona

Hospital Universitari Son Espases. Illes Balears.

CASO CLÍNICO



Mujer de 30 años
FO: 0.0.0.0
AP: DM1 bien controlada
Fumadora 5-6 cig

H. Inca



Eco 12s

CRL
TNp>99
DV Ausente

**Biopsia
corial**

Cariotipo: normal
Arrays: normal
Exoma: normal

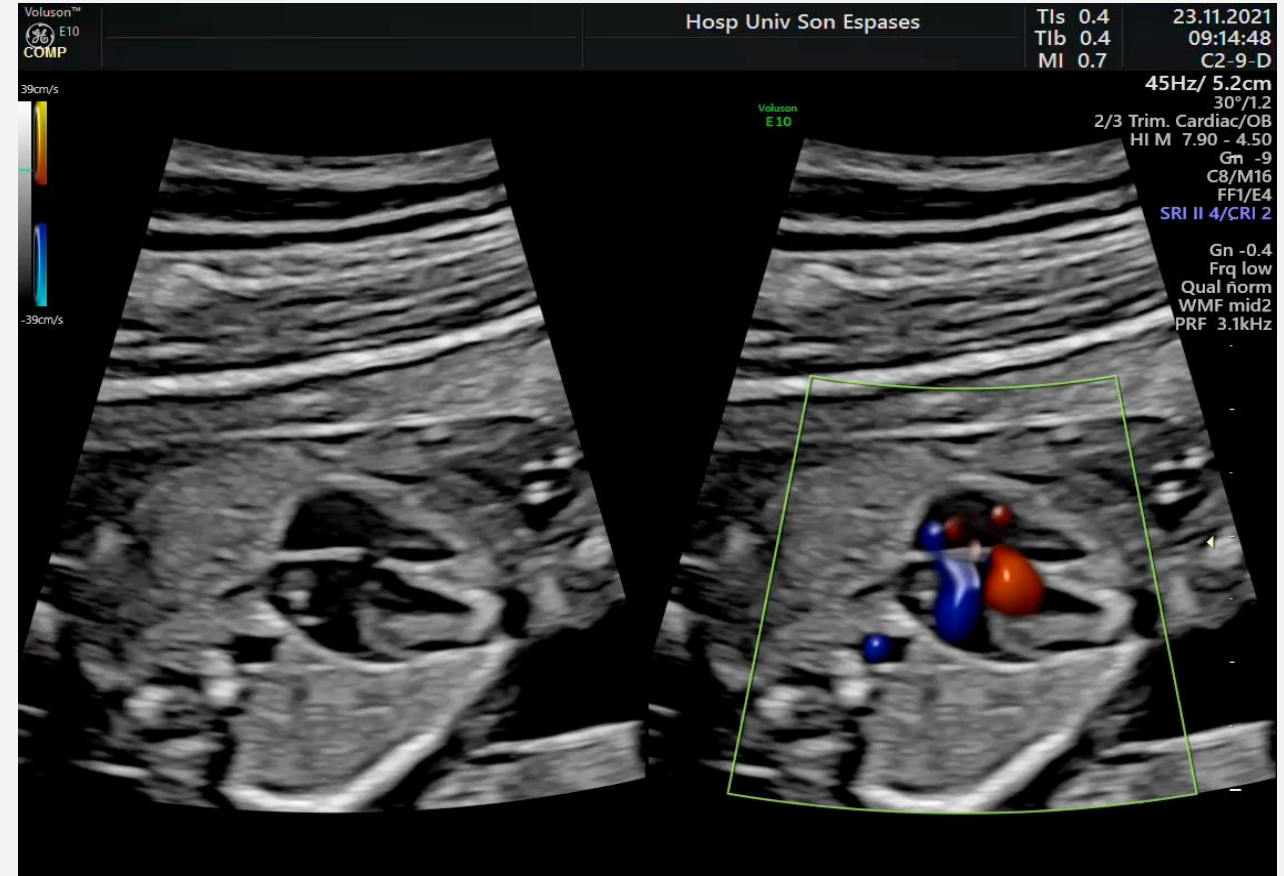
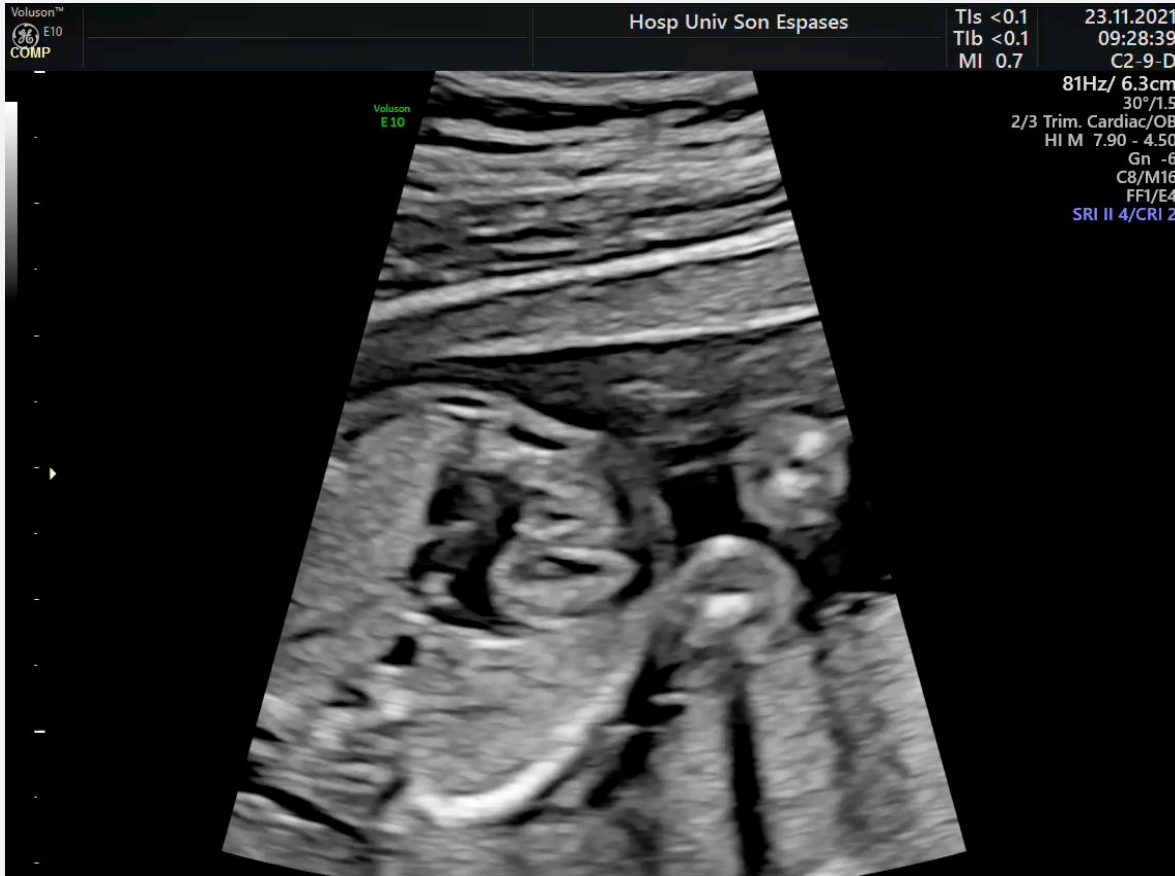Eco 16s

Sospecha canal
Aurículo-
ventricular

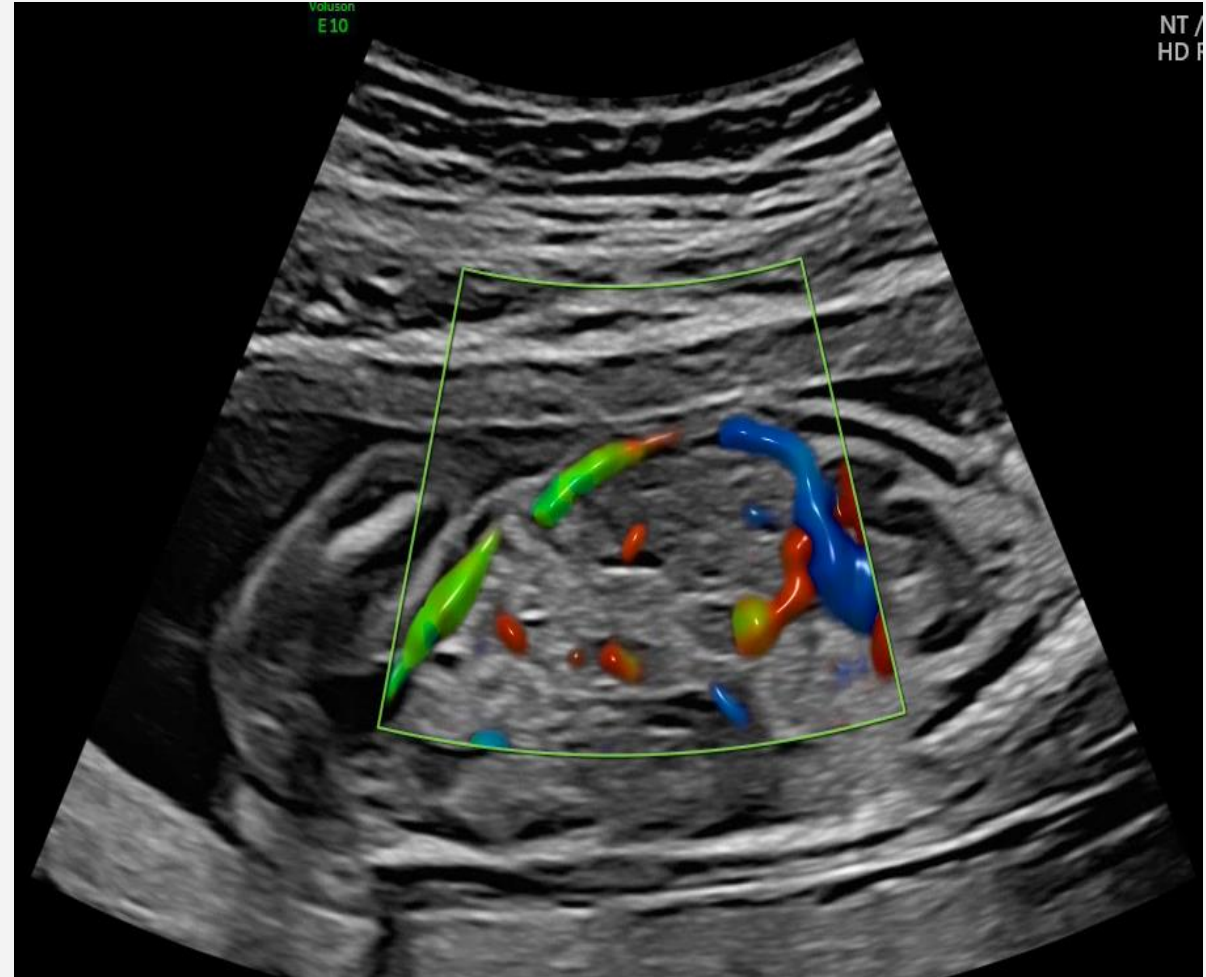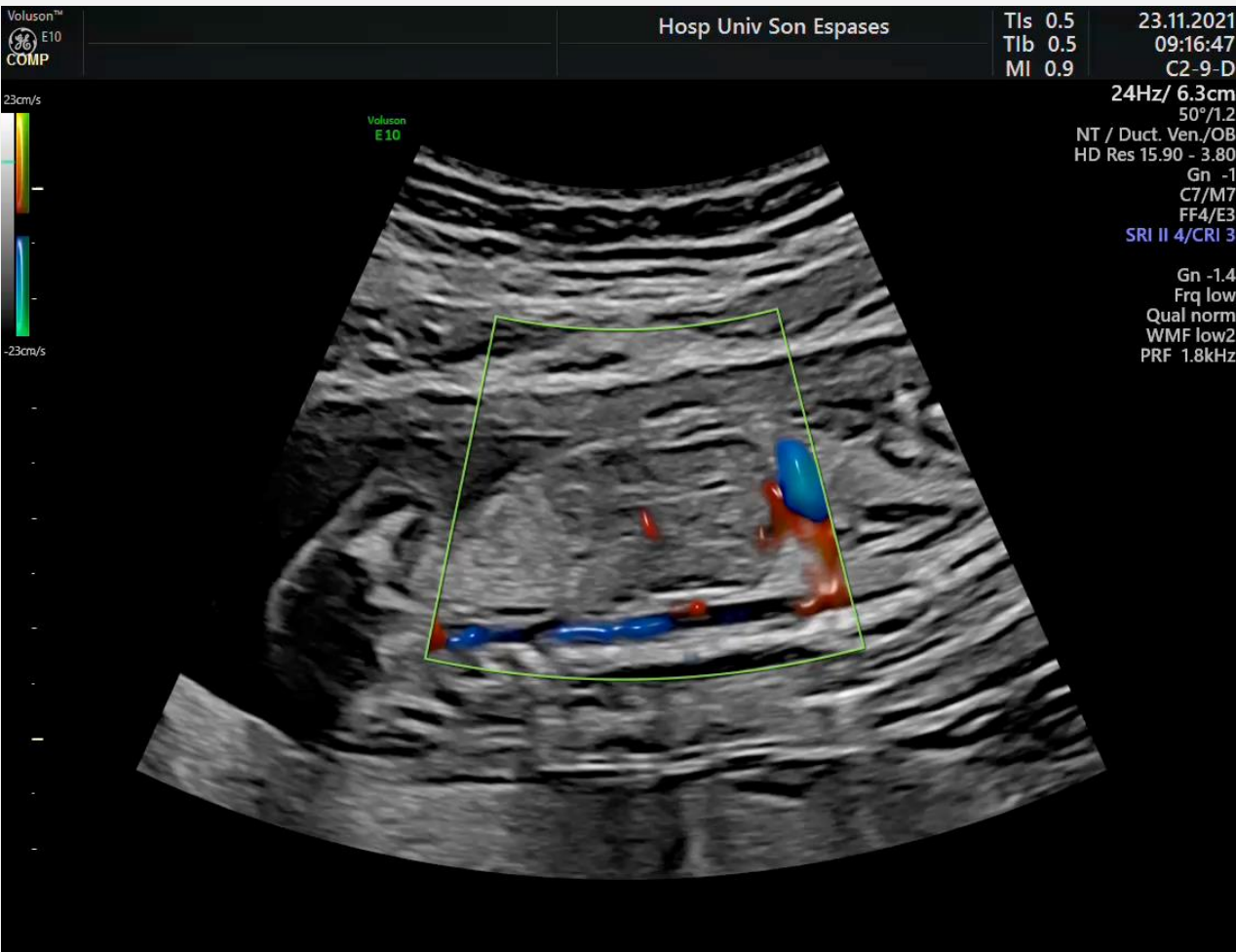


CASO CLÍNICO

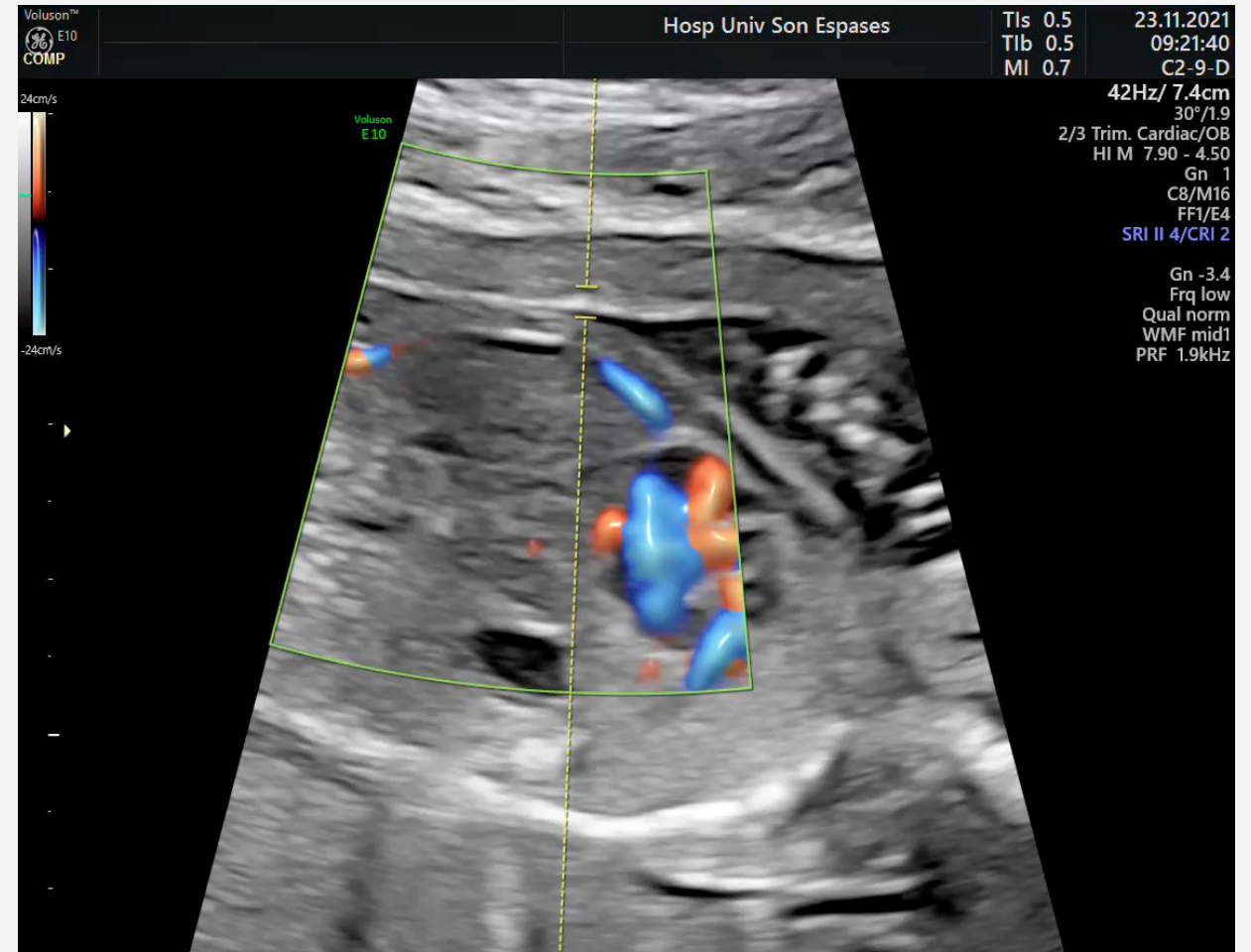
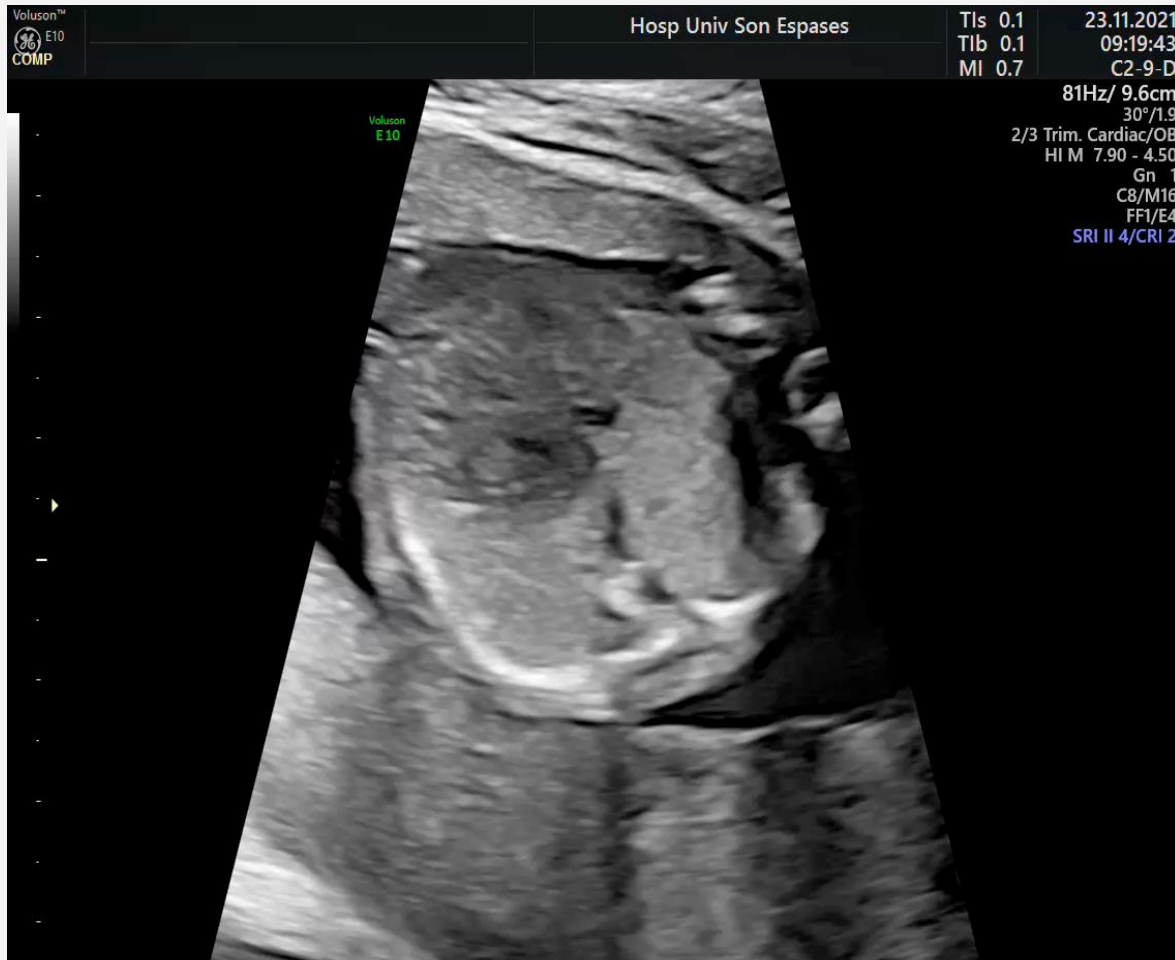Eco 17+5s



CASO CLÍNICO

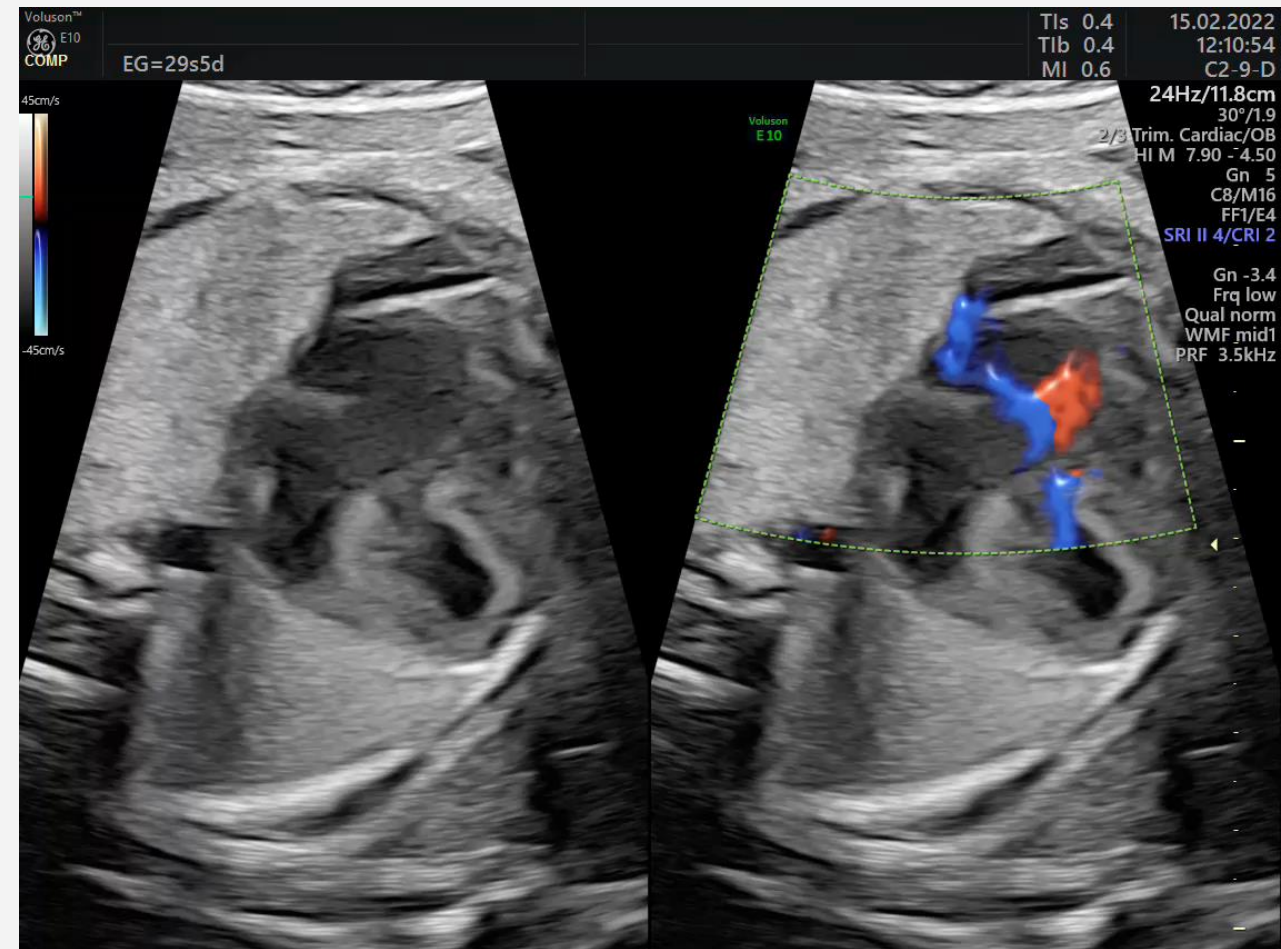
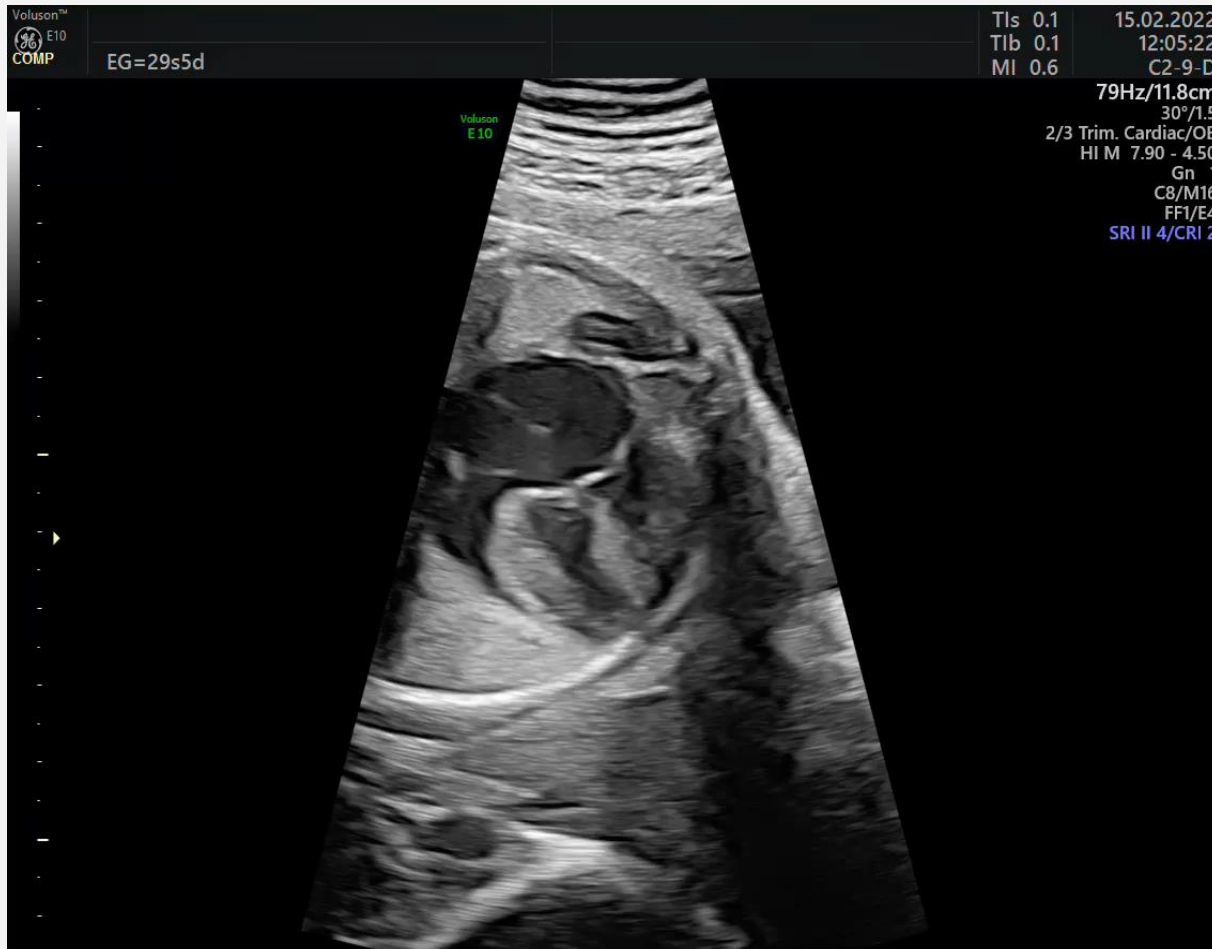


CASO CLÍNICO



CASO CLÍNICO

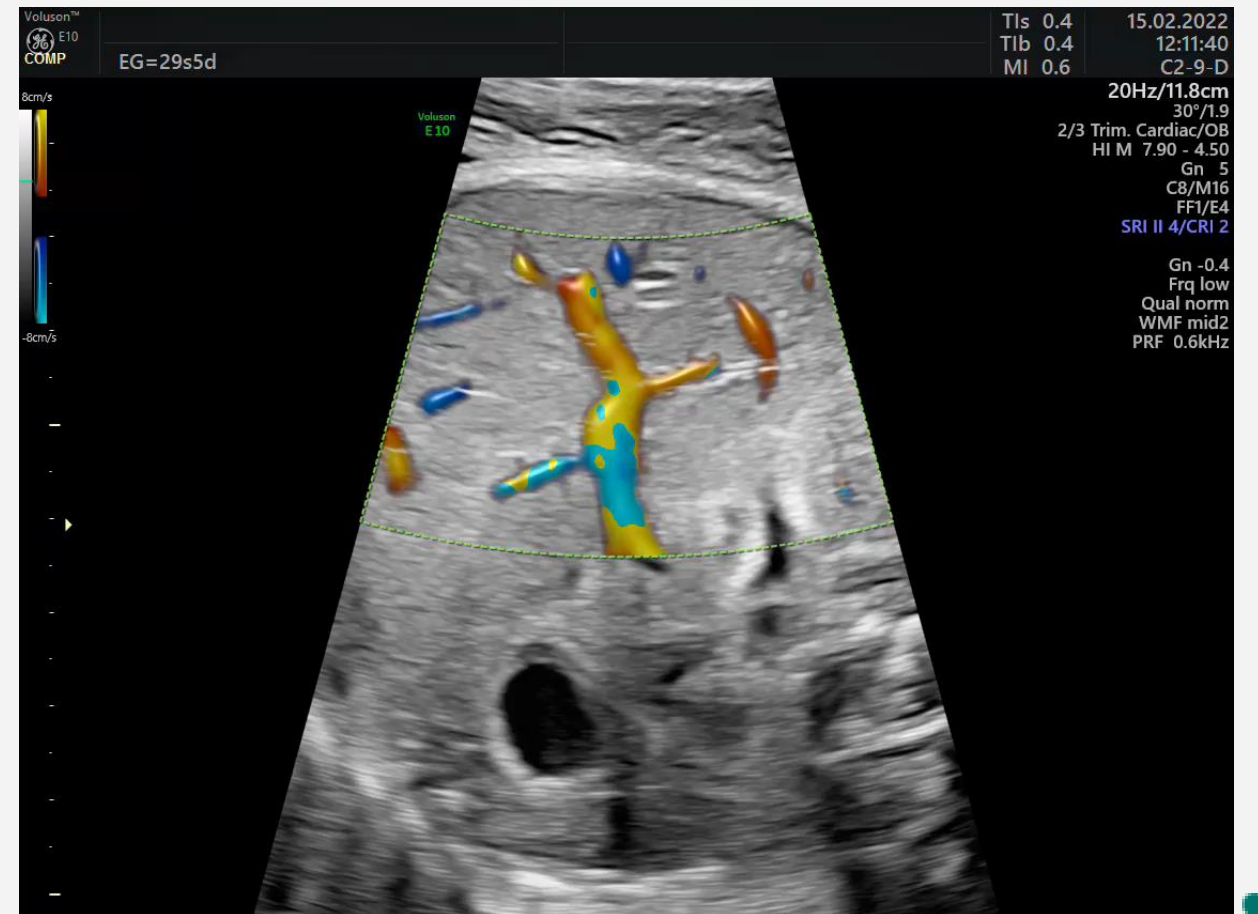
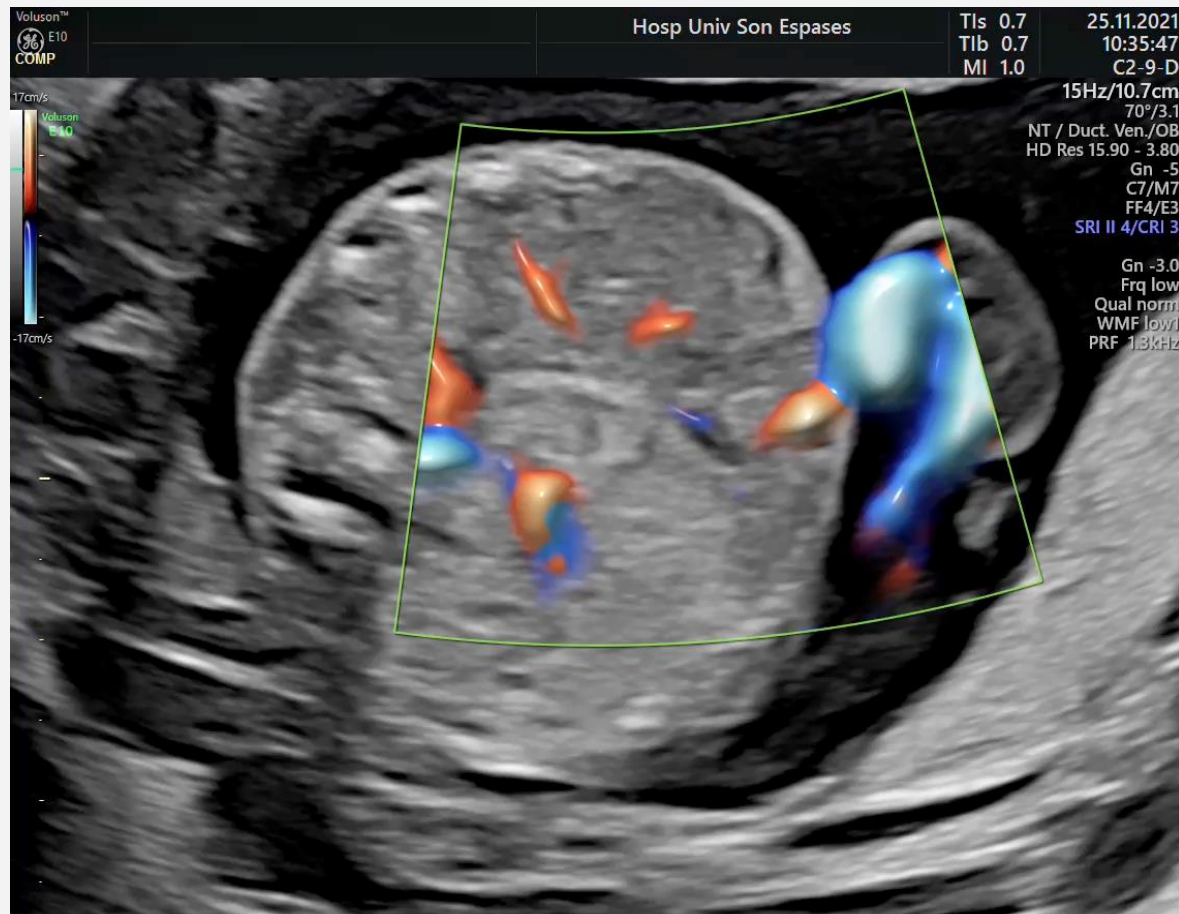
Eco 29+5s



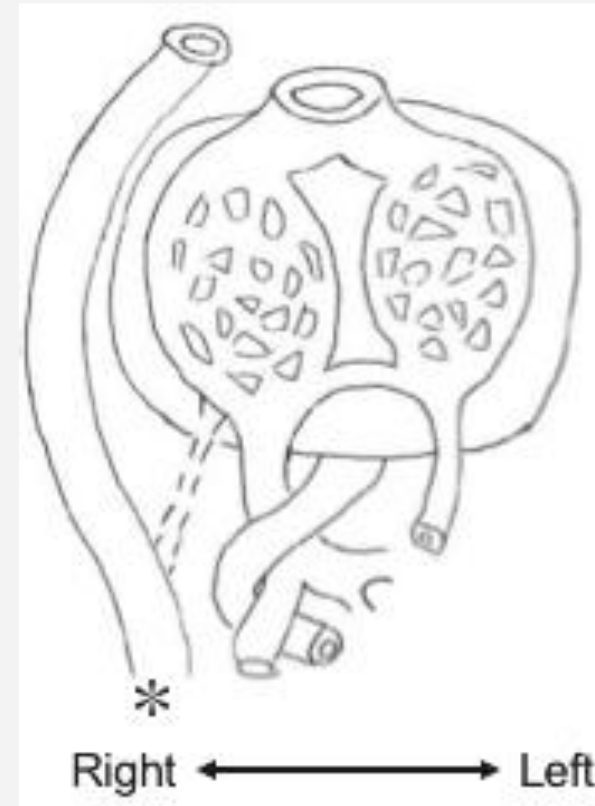
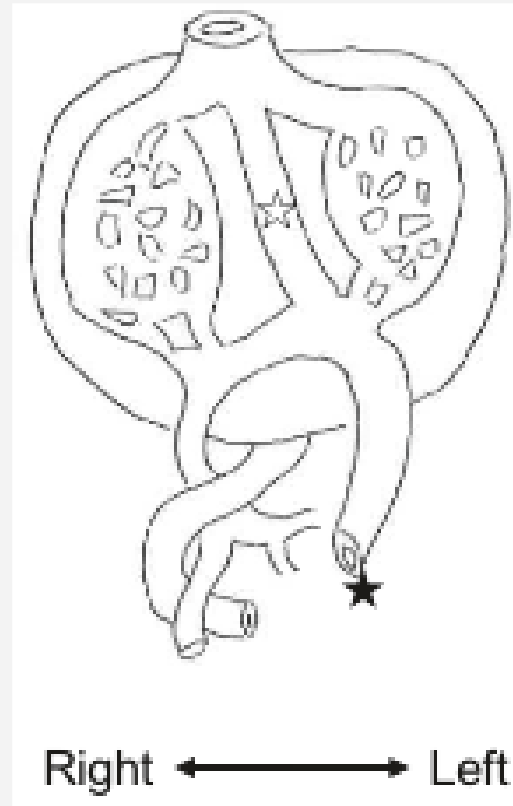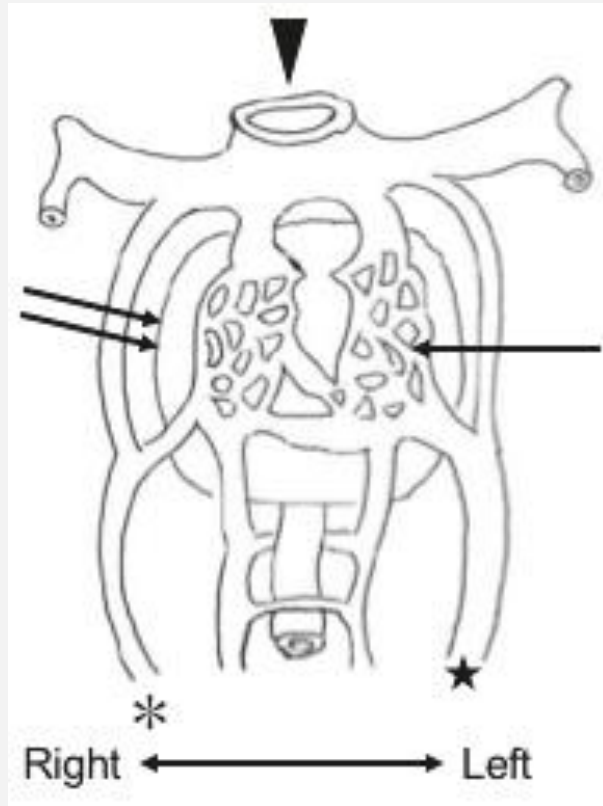
CASO CLÍNICO

Eco 17+5s

Eco 29+5s



AGENESIA DUCTUS VENOSO



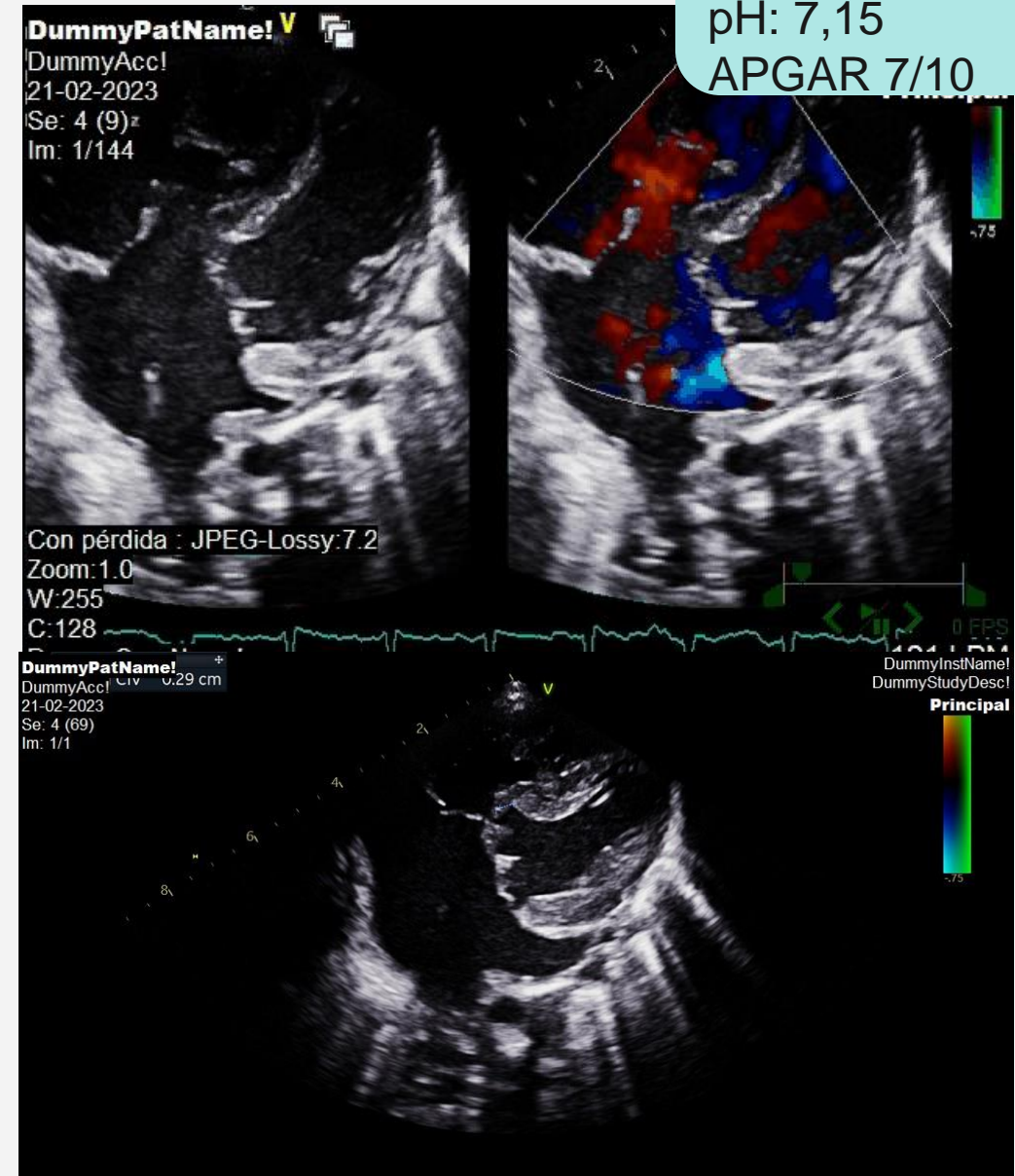
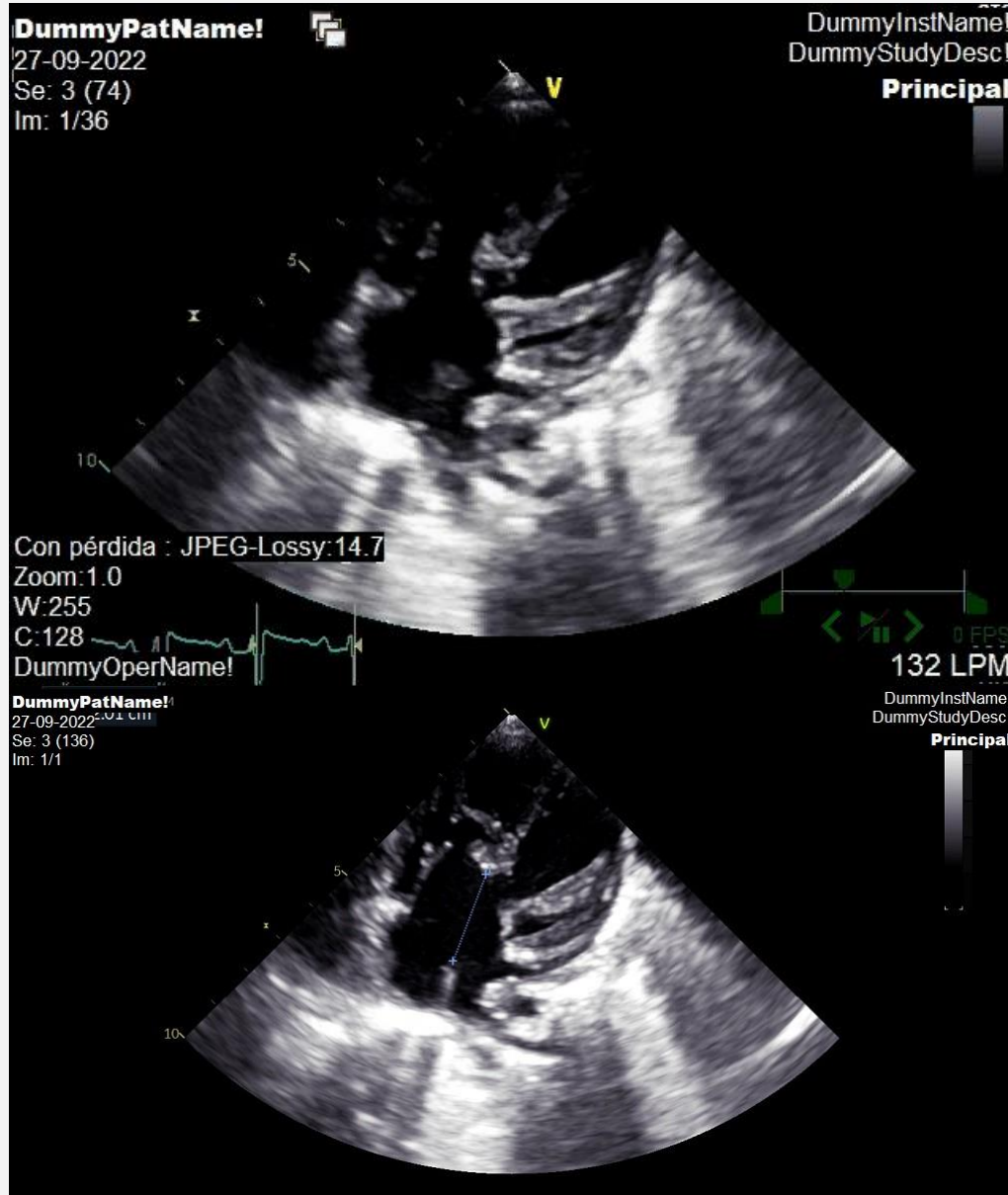
CASO CLÍNICO

POSTNATAL

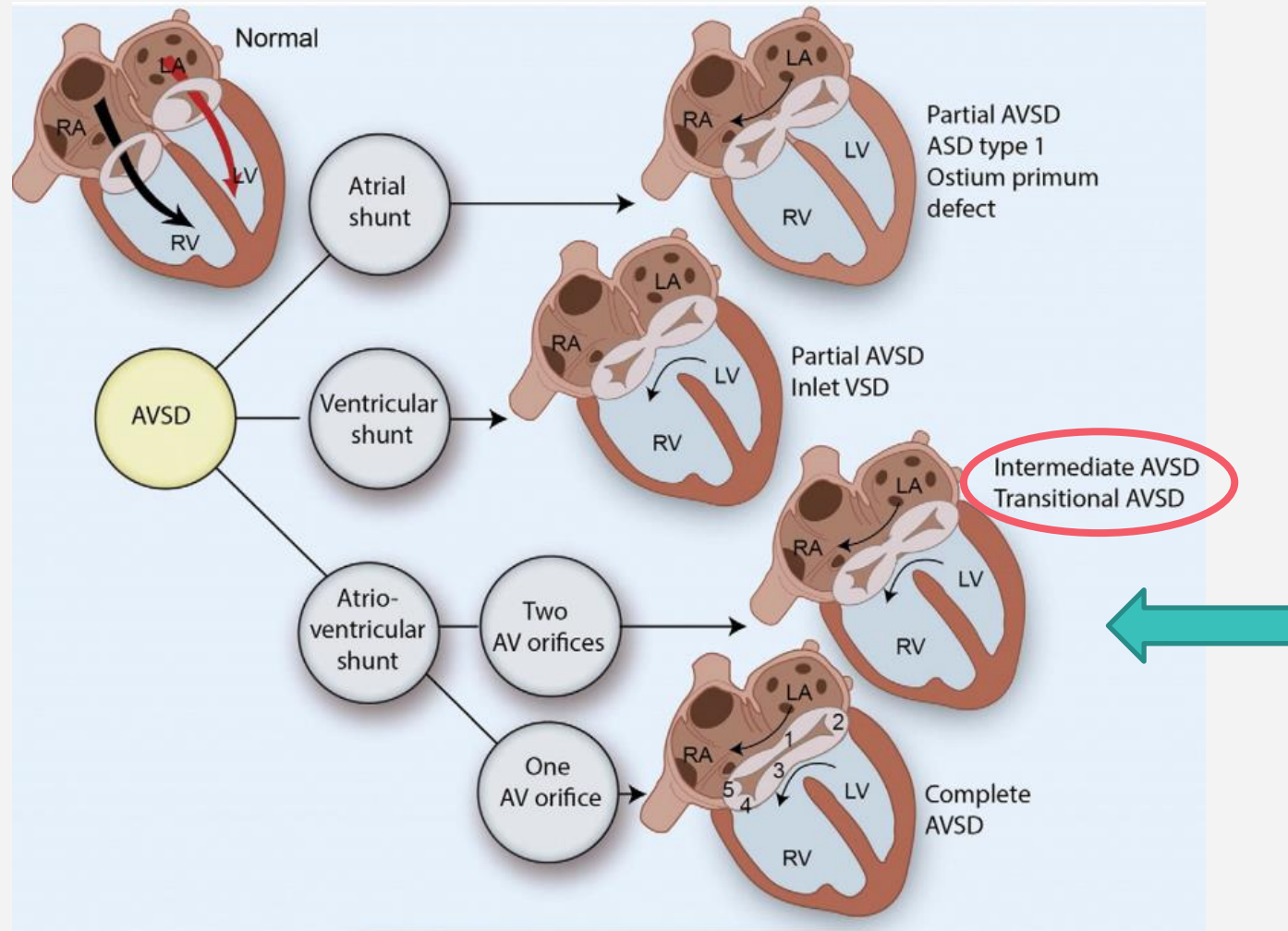
ECOCARDIOGRAFÍA
postnatal



Parto vaginal 39+4s
RN Mujer
3065gr
pH: 7,15
APGAR 7/10



AGENESIA DUCTUS VENOSO



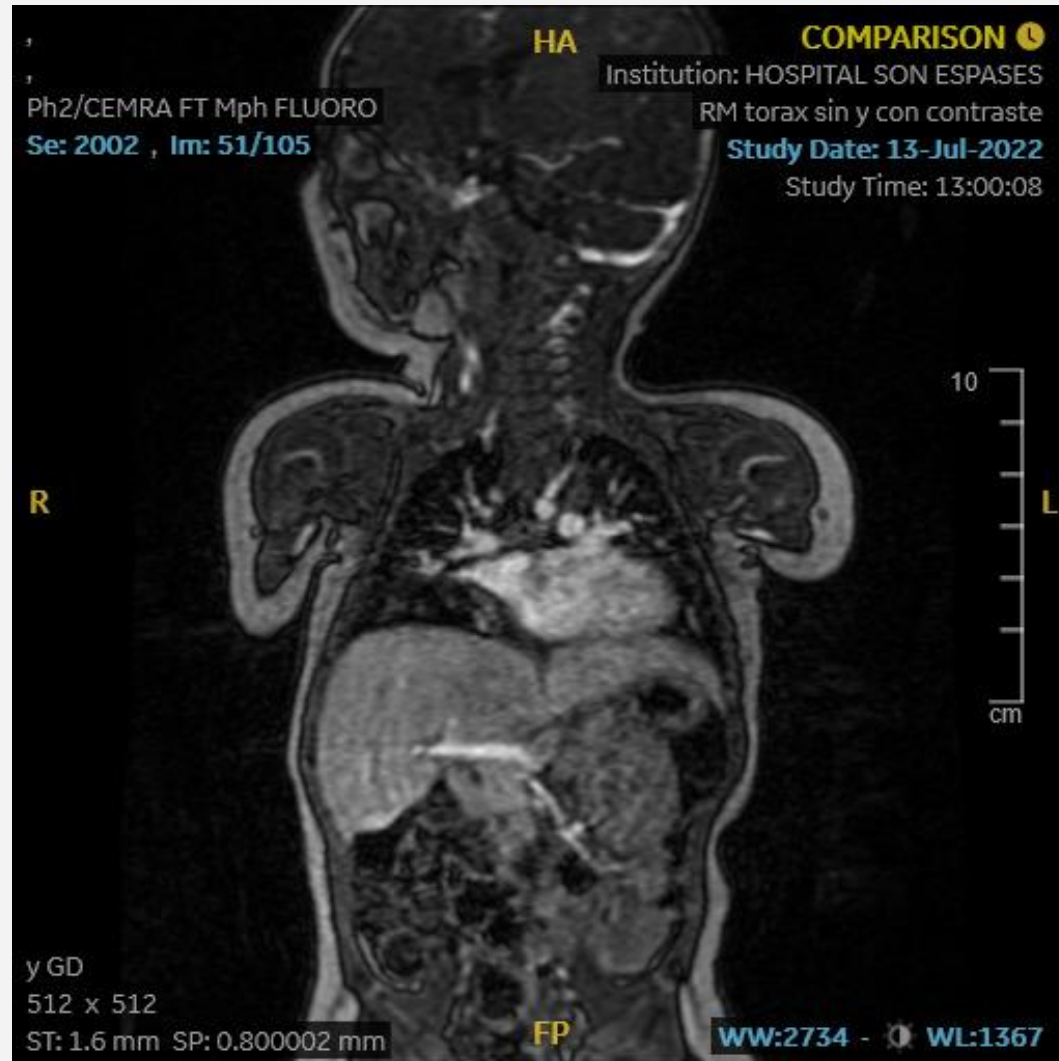
CASO CLÍNICO

POSTNATAL

RESONANCIA
MAGNÉTICA postnatal



Parto vaginal 39+4s
RN Mujer
3065gr
pH: 7,15
APGAR 7/10



AGENESIA DUCTUS VENOSO

INCIDENCIA

6/1000

DRENAJE

- Intrahepático
- Extrahepático

ASOCIACIONES

- Cromosómicas
- Cardíacas
- Extracardíacas
- Sistema venoso portal
- Cortocircuitos portosistémicos persistentes.

ESTUDIO GENÉTICO

- FISH
- Cariotipo
- Array-CGH +/- exoma

PRONÓSTICO

- Aislado
- Anomalías asociadas



1. Yagel, S., Kivilevitch, Z., Cohen, S. M., Valsky, D. V., Messing, B., Shen, O., & Achiron, R. (2010). The fetal venous system, part I: normal embryology, anatomy, hemodynamics, ultrasound evaluation and Doppler investigation. *Ultrasound in obstetrics & gynecology : the official journal of the International Society of Ultrasound in Obstetrics and Gynecology*, 35(6), 741–750.
2. K., Takahashi, H., Matsubara, D., Kataoka, K., Furukawa, R., Baba, Y., Ohkuchi, A., & Matsubara, S. (2018). Absent Ductus Venosus Associated with Partial Liver Defect. *Case reports in obstetrics and gynecology*, 2018, 6591025.
3. Pérez-Pedregosa Javier, Martínez G María Teresa, del Pino S.R Sandra, Gutiérrez-Larraya A Federico, Medina M Leticia, Bueso M Teresa et al . Diagnóstico prenatal y evolución en fetos con agenesia de ductus venoso. *Rev. chil. obstet. ginecol.* 2014
4. Pacheco D, Brandão O, Montenegro N, Matias A. Ductus venosus agenesis and fetal malformations: what can we expect? – a systematic review of the literature. *Journal of Perinatal Medicine.* 2019;47(1): 1-11.
5. Calkoen, E. E., Hazekamp, M. G., Blom, N. A., Elders, B. B., Gittenberger-de Groot, A. C., Haak, M. C., Bartelings, M. M., Roest, A. A., & Jongbloed, M. R. (2016). Atrioventricular septal defect: From embryonic development to long-term follow-up. *International journal of cardiology*,
6. Strizek, B., Zamprakou, A., Gottschalk, I., Roethlisberger, M., Hellmund, A., Müller, A., Gembruch, U., Geipel, A., & Berg, C. (2019). Prenatal Diagnosis of Agenesis of Ductus Venosus: A Retrospective Study of Anatomic Variants, Associated Anomalies and Impact on Postnatal Outcome. *Pränatale Agenesie des Ductus venosus: retrospektive Analyse anatomischer Varianten, assoziierter Fehlbildungen und Einfluss auf das postnatale Outcome. Ultraschall in der Medizin (Stuttgart, Germany : 1980)*, 40(3), 333–339.



MOLTES GRÀCIES



@albusagui_art

“The important thing is not to stop questioning.”

