

Perfil Fetal Anòmal

Andrea Anleu

R3 Ginecologia i Obstetricia

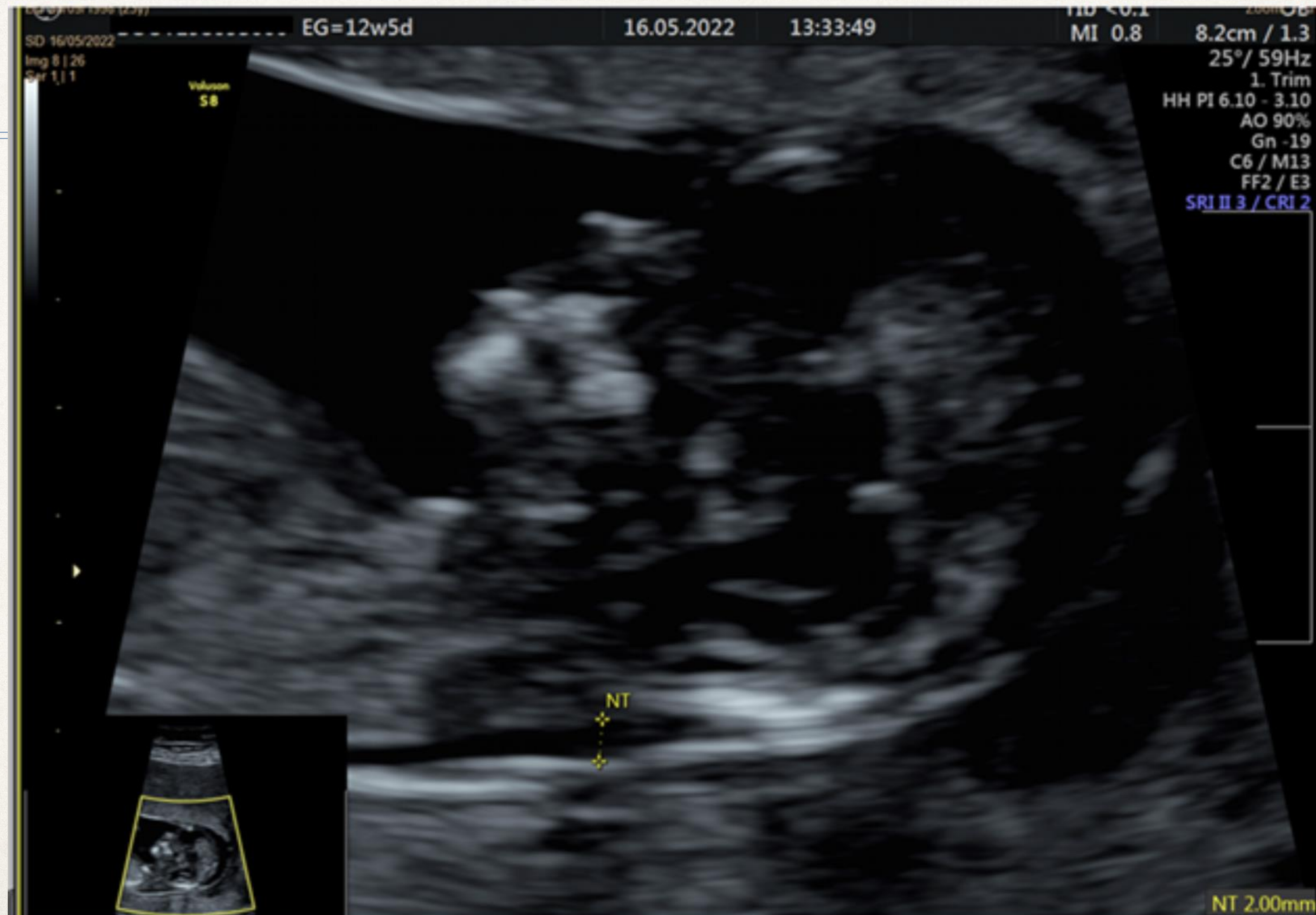Consorti Hospitalari de Vic

Antecedents Personals

- ❖ TPAL: 2002
- ❖ 23 anys
- ❖ Parella consanguínia (consins germans)
- ❖ 2 fills sans



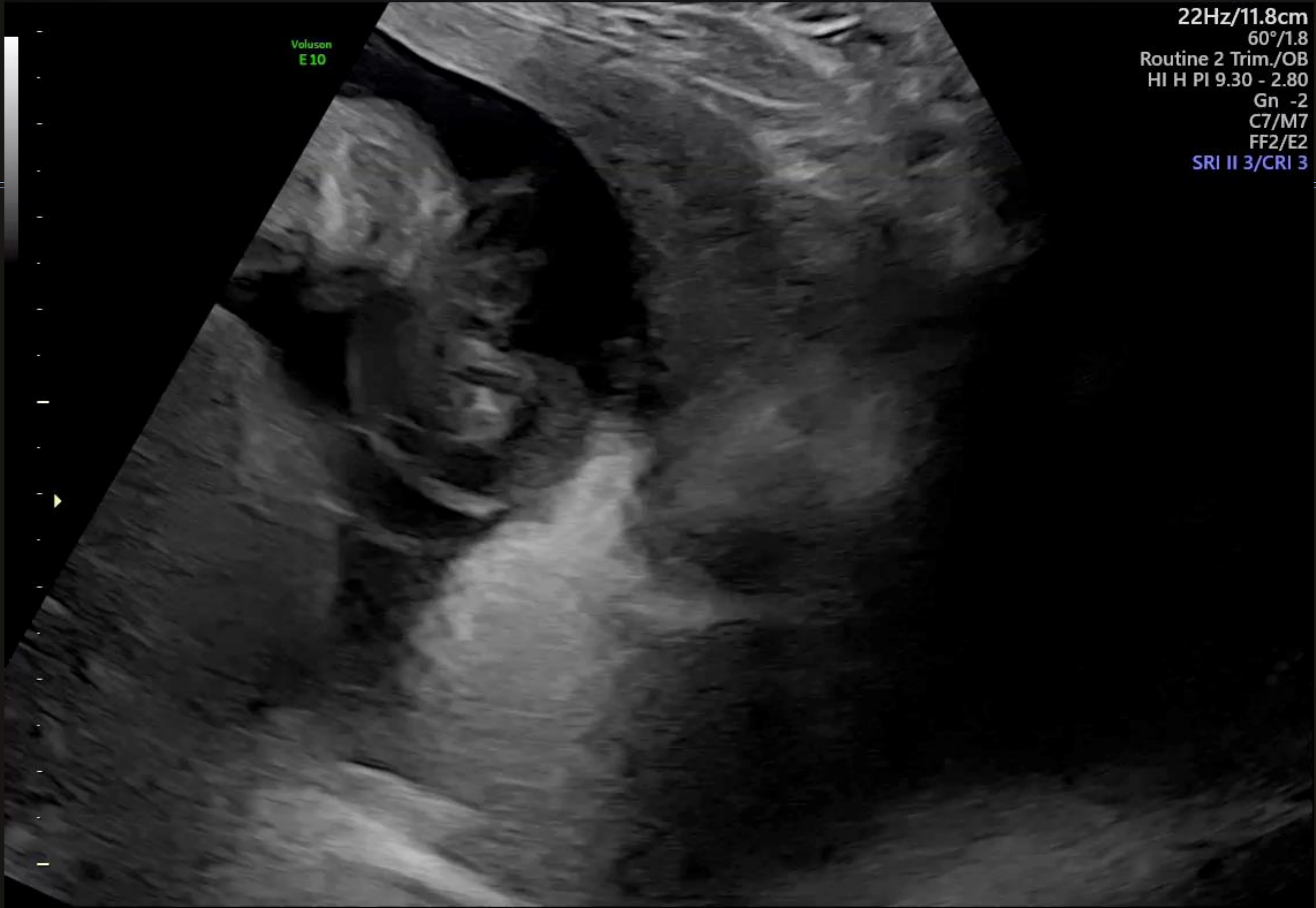Ecografía de Primer Trimestre

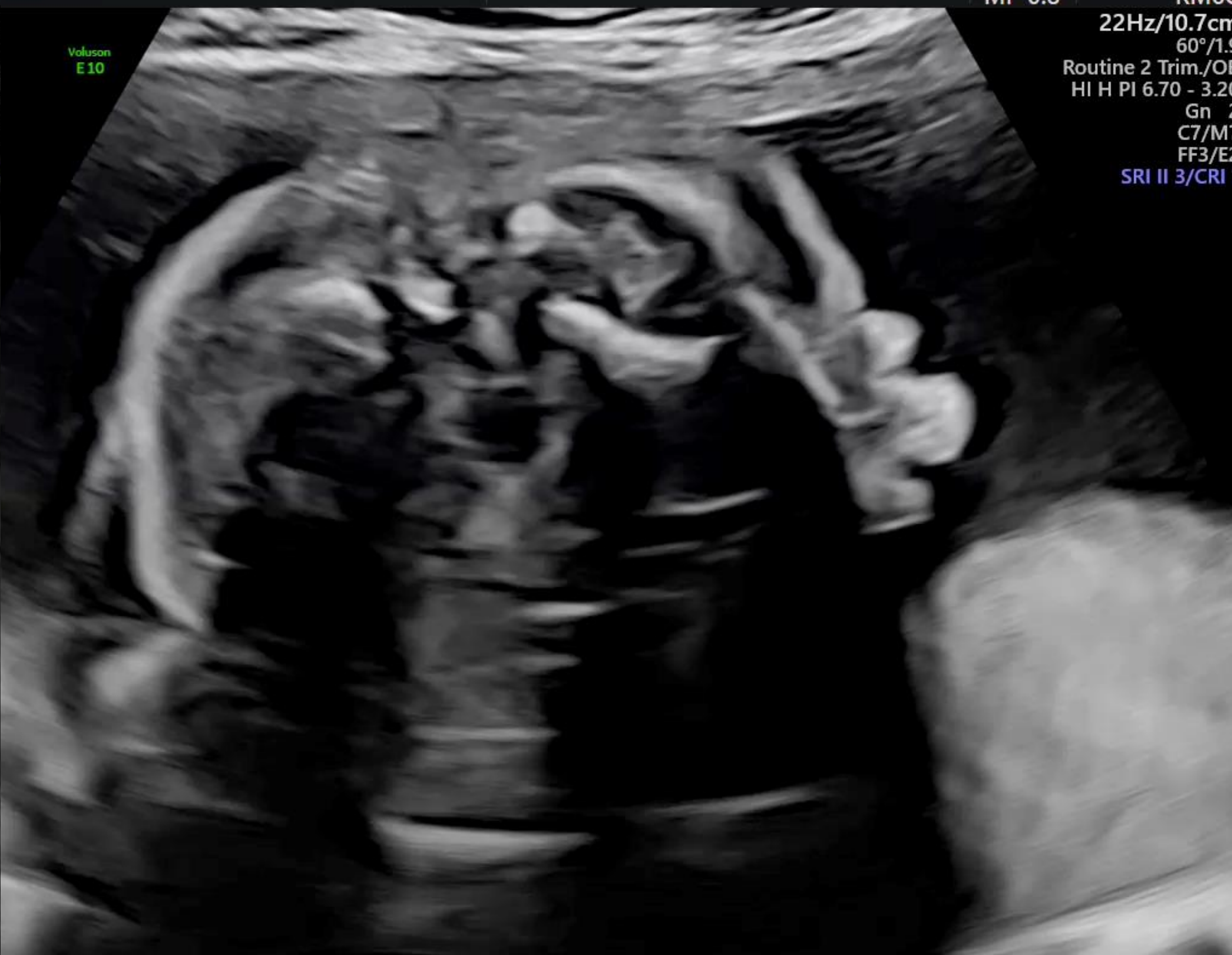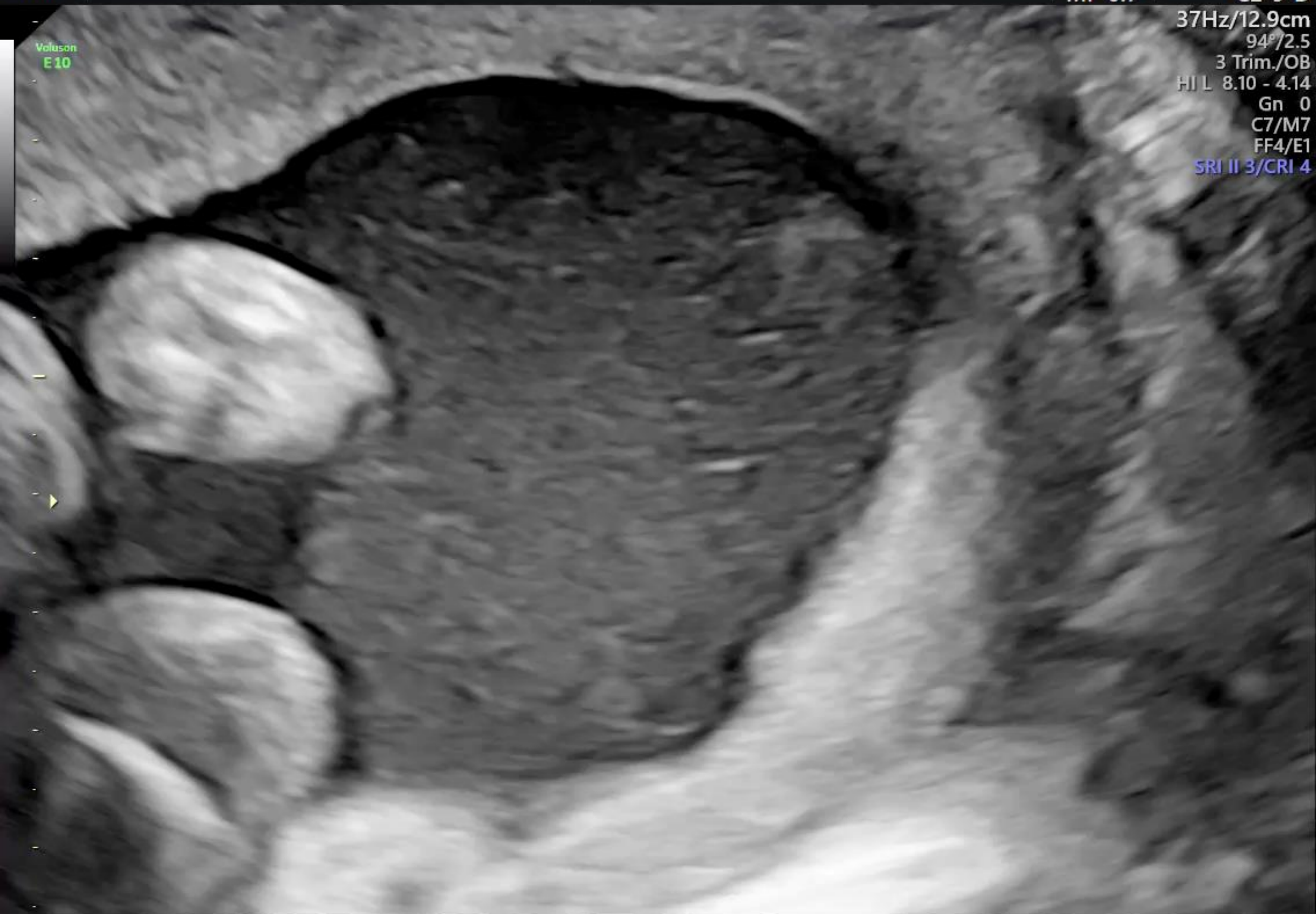


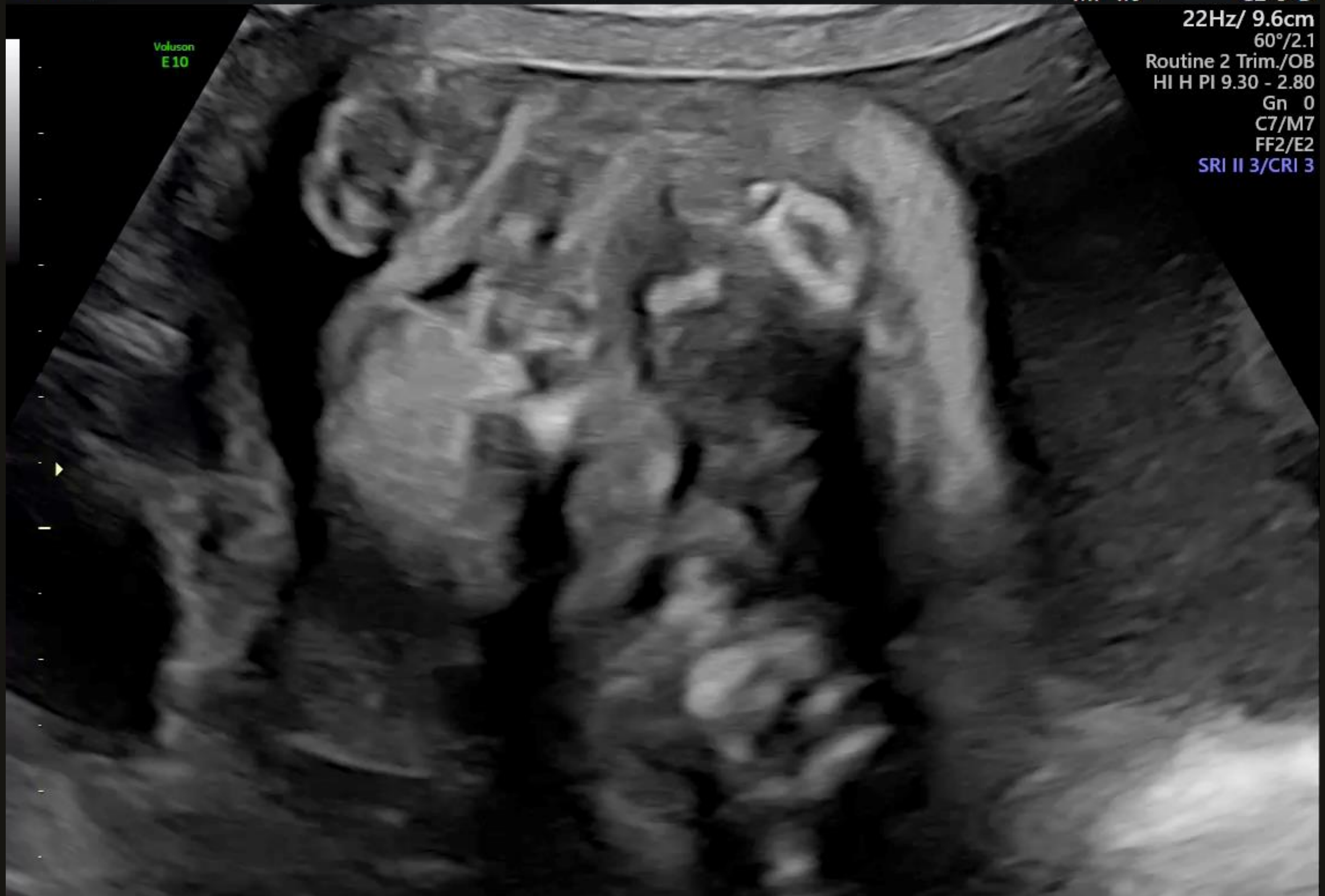25s

Voluson
E10

22Hz/11.8cm
60°/1.8
Routine 2 Trim./OB
HI H PI 9.30 - 2.80
Gn -2
C7/M7
FF2/E2
SRI II 3/CRI 3



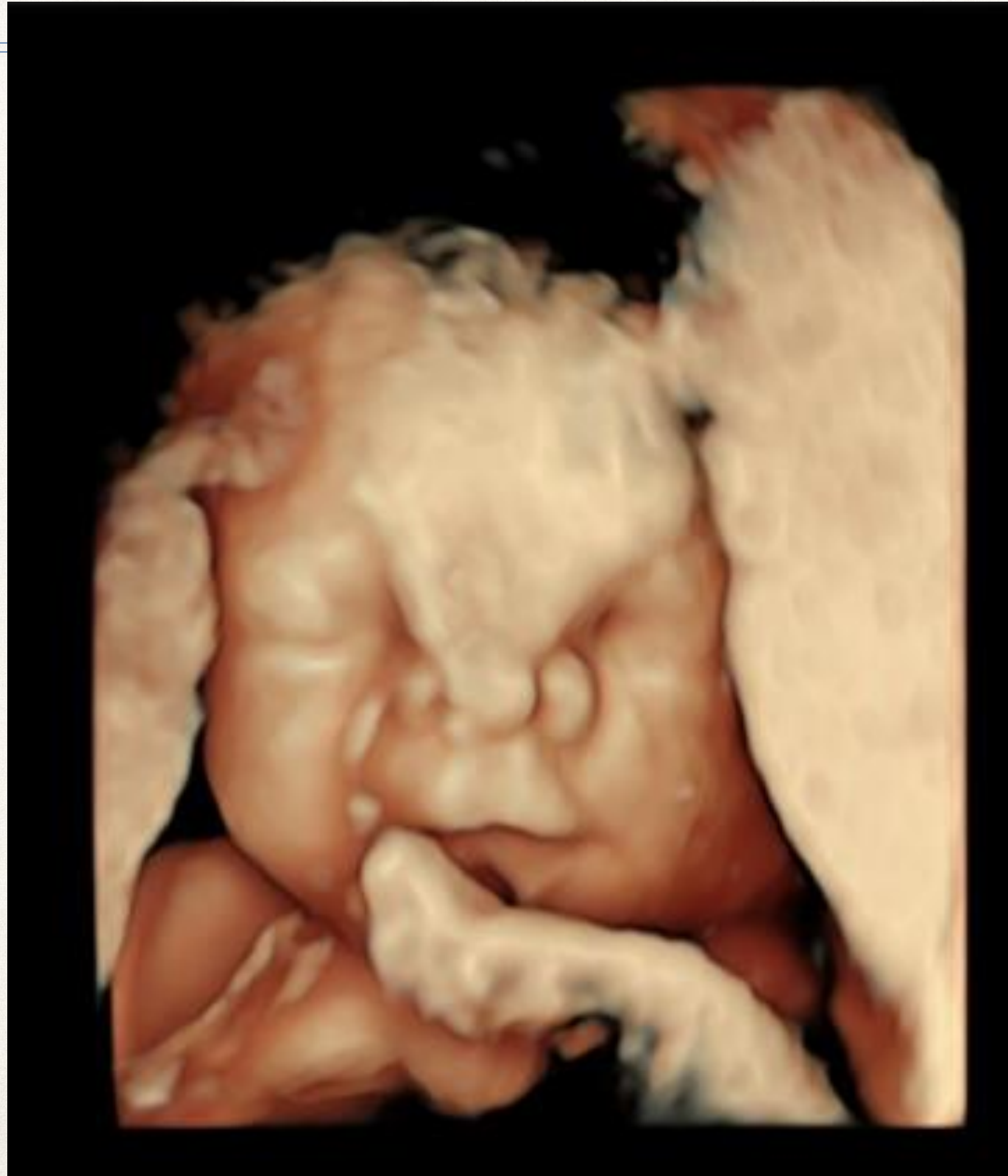


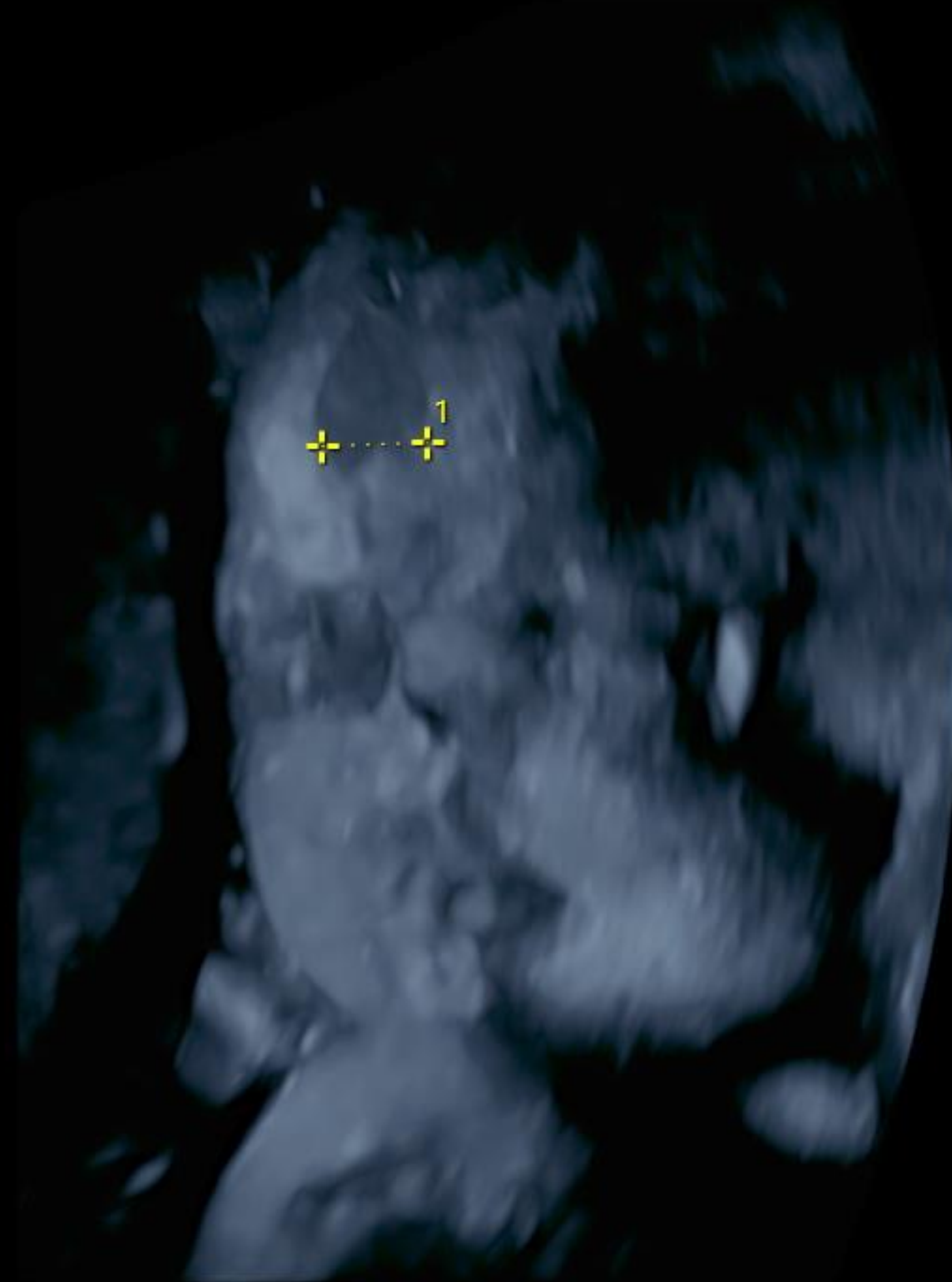
Voluson
E10

22Hz/ 9.6cm
60°/2.1
Routine 2 Trim./OB
HI H PI 9.30 - 2.80
Gn 0
C7/M7
FF2/E2
SRI II 3/CRI 3

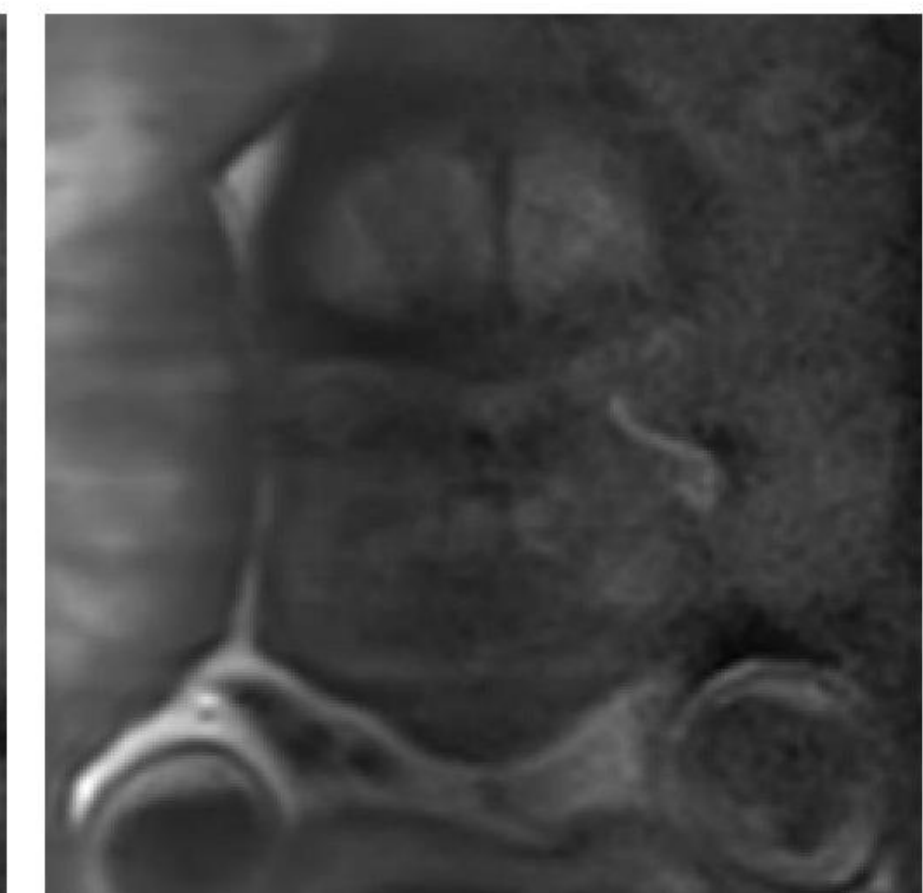
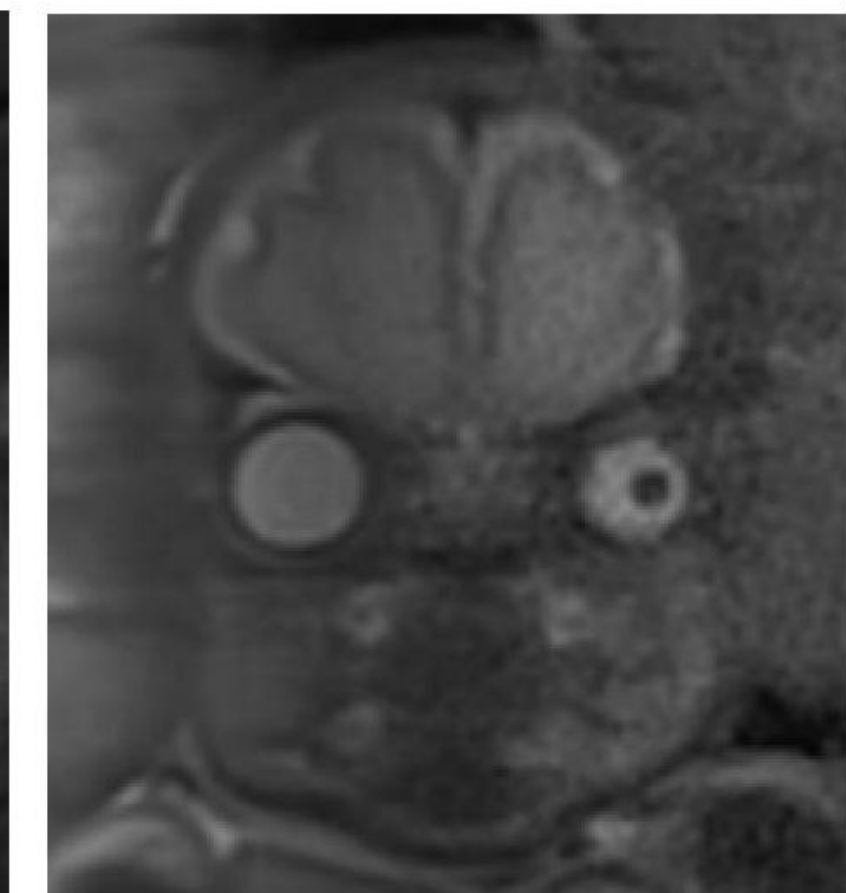
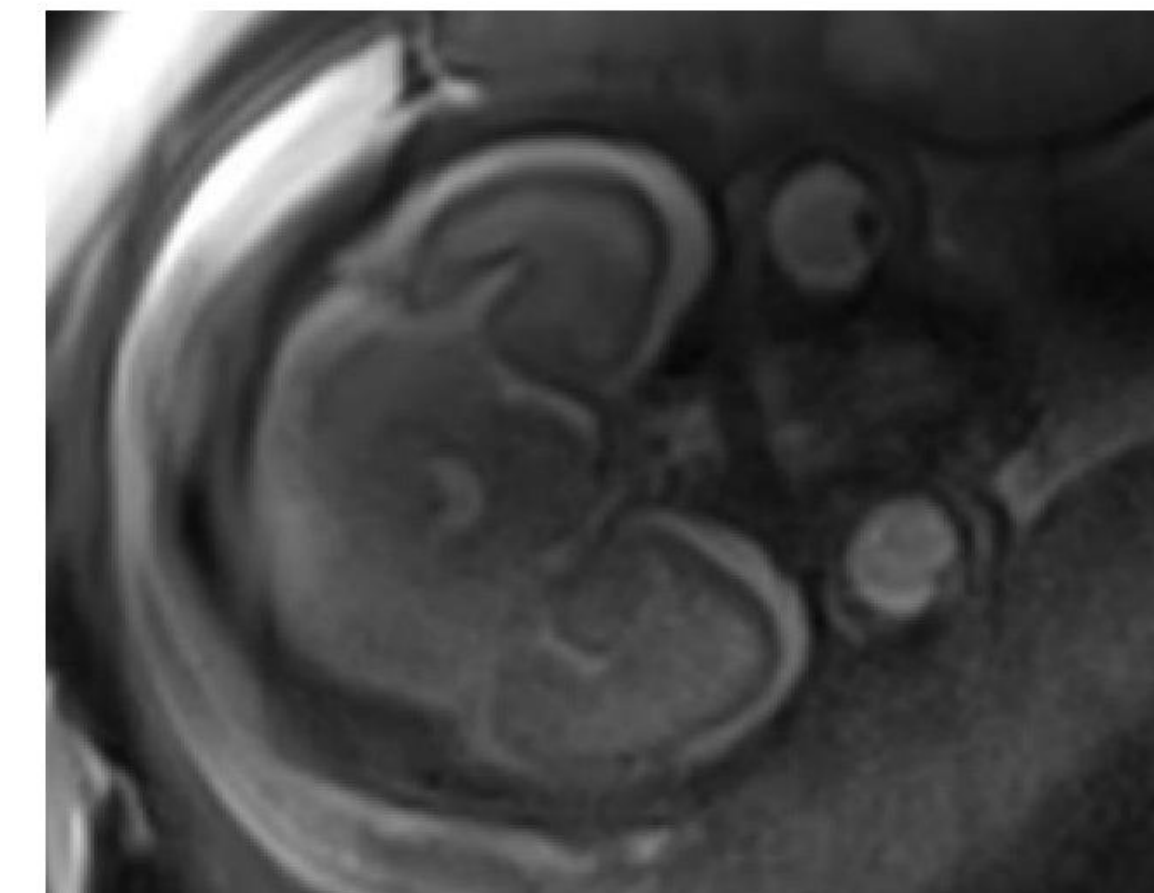
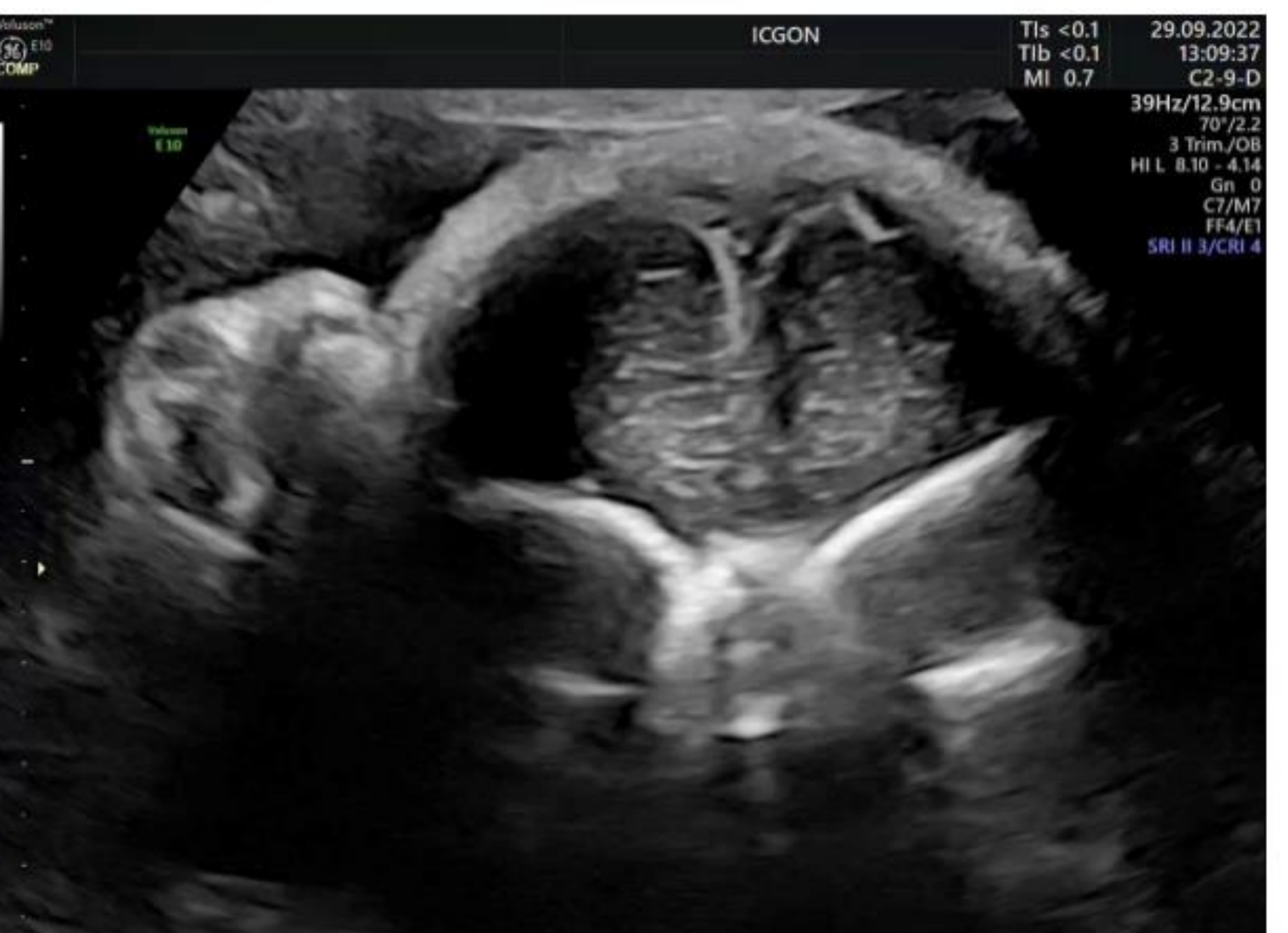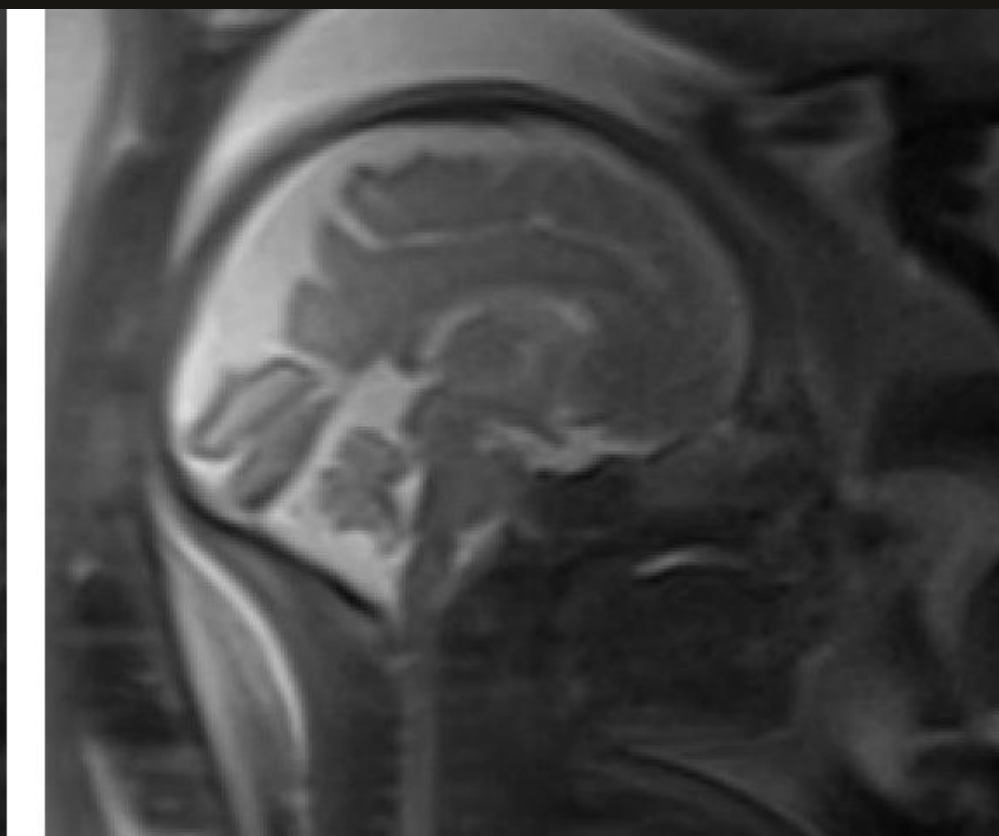
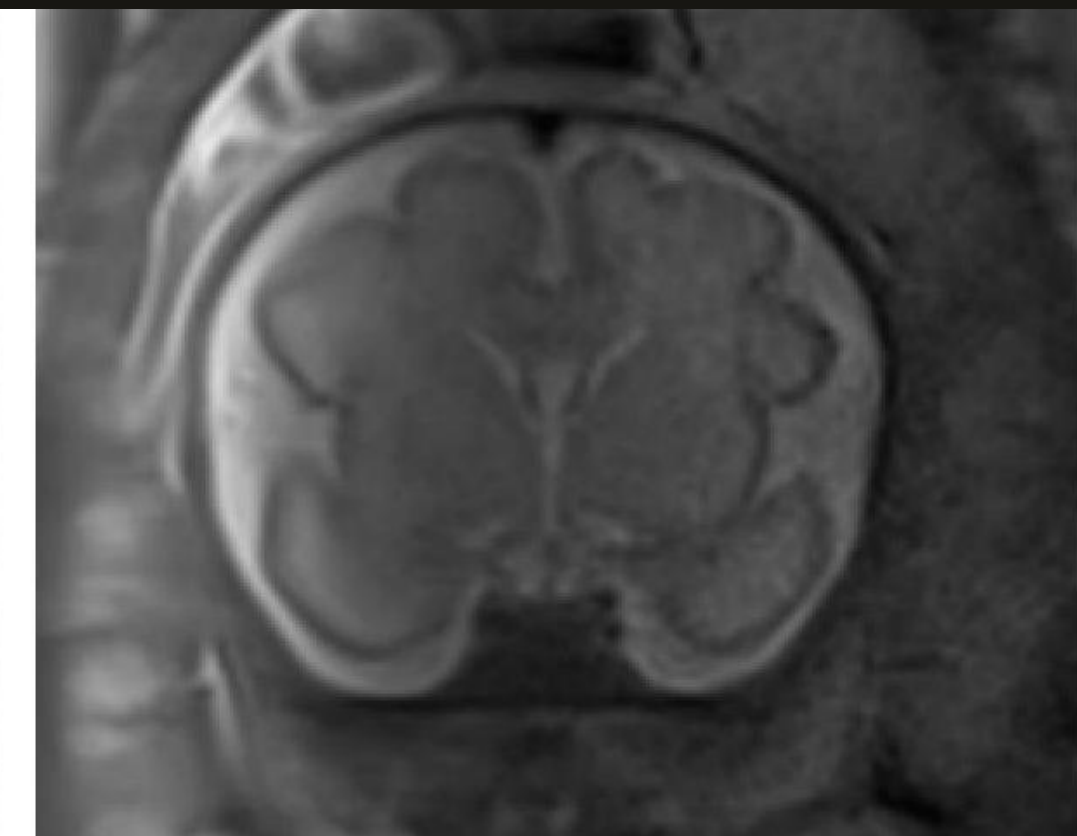
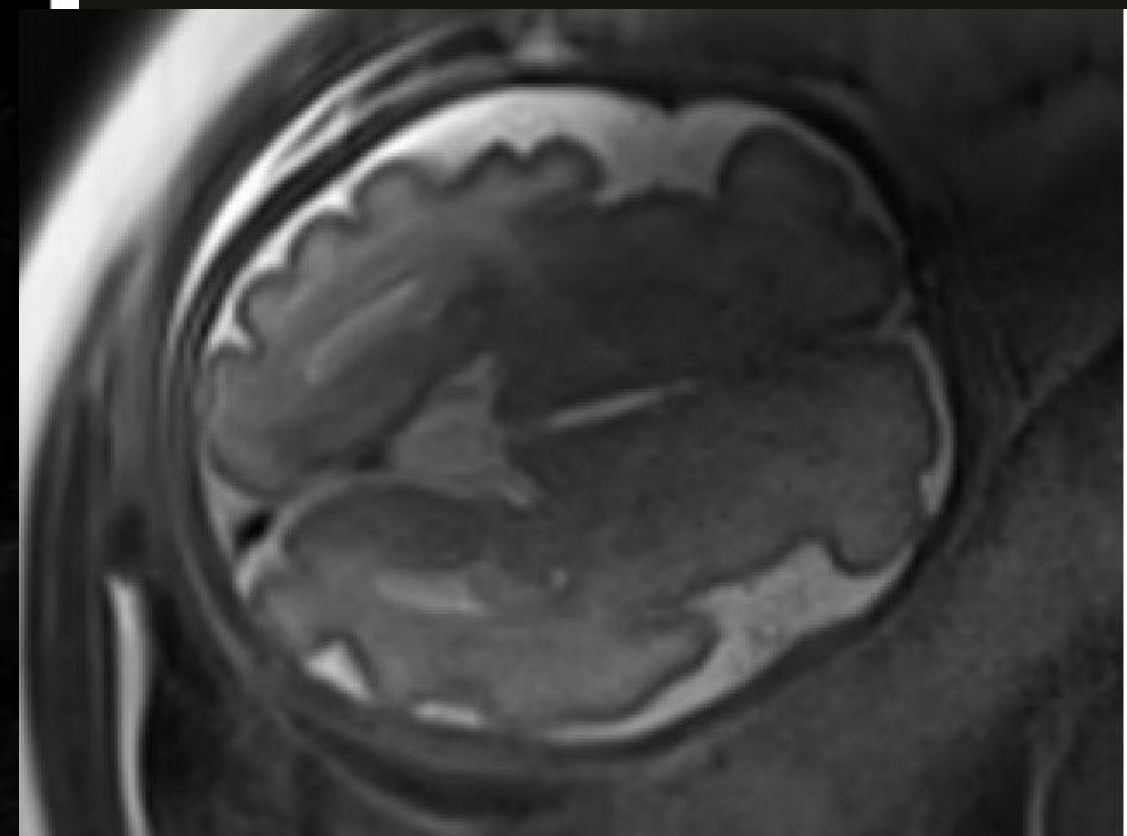
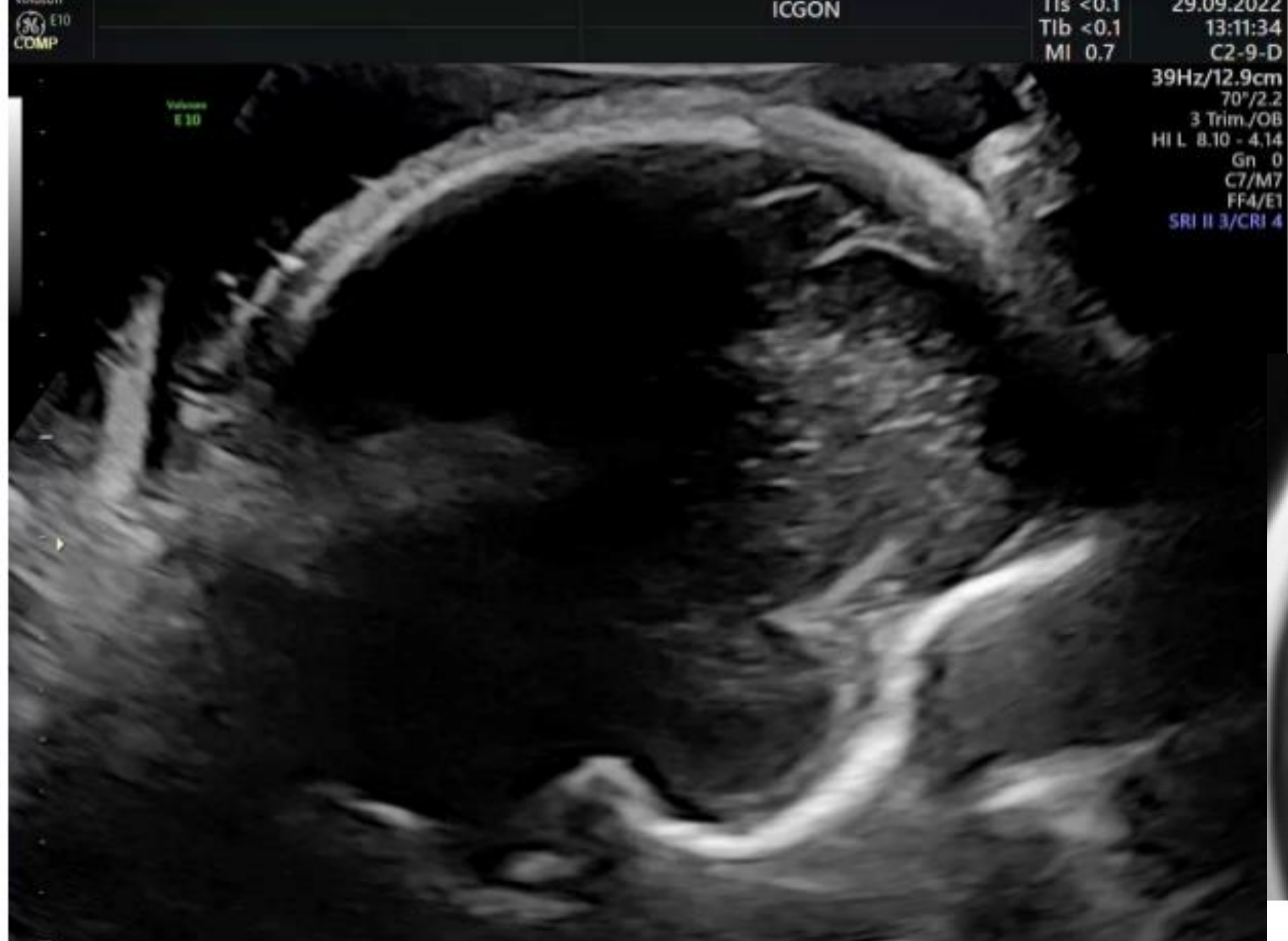Displàsia Frontonasal





1 D 11.06mm

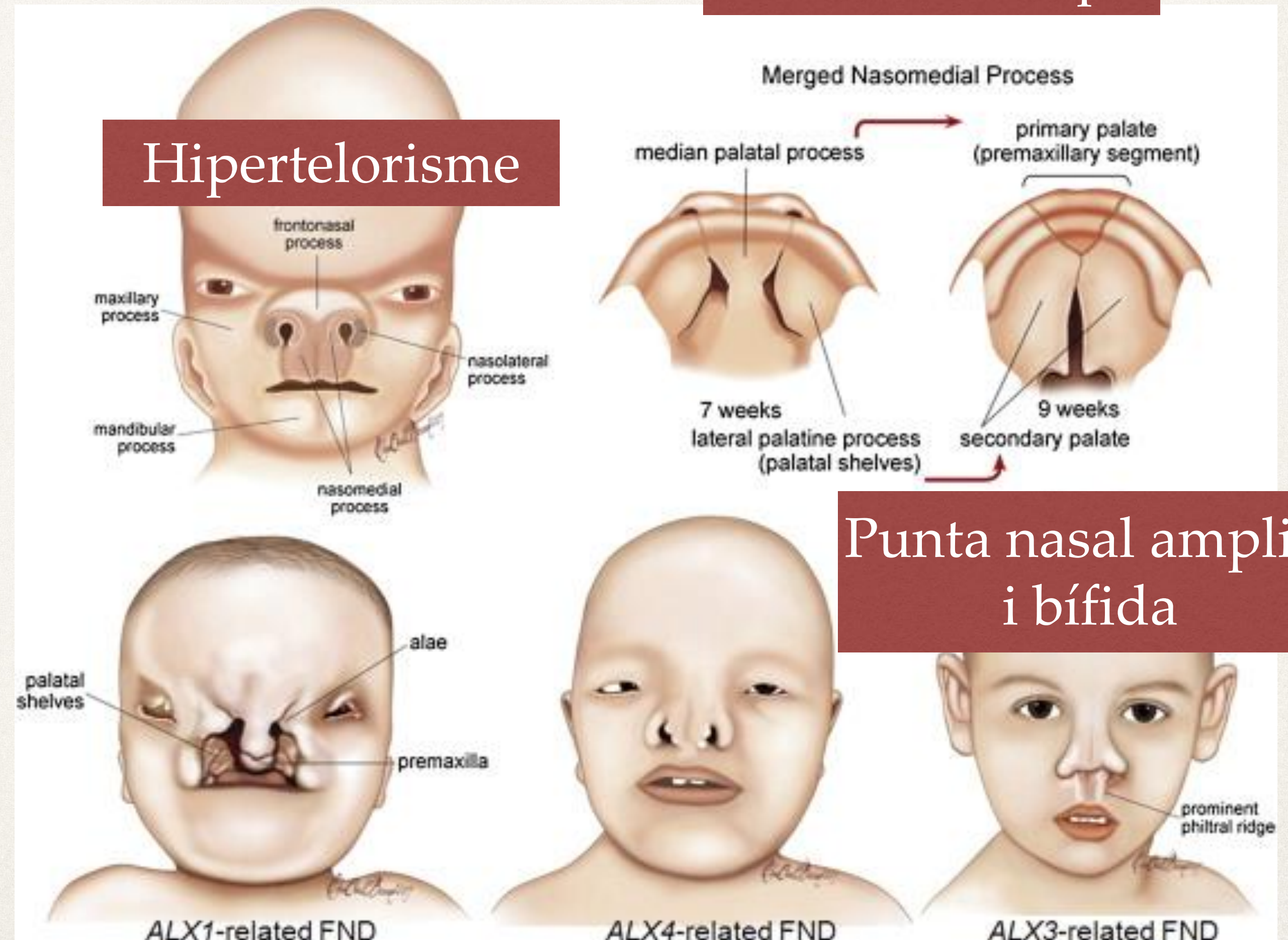
3D



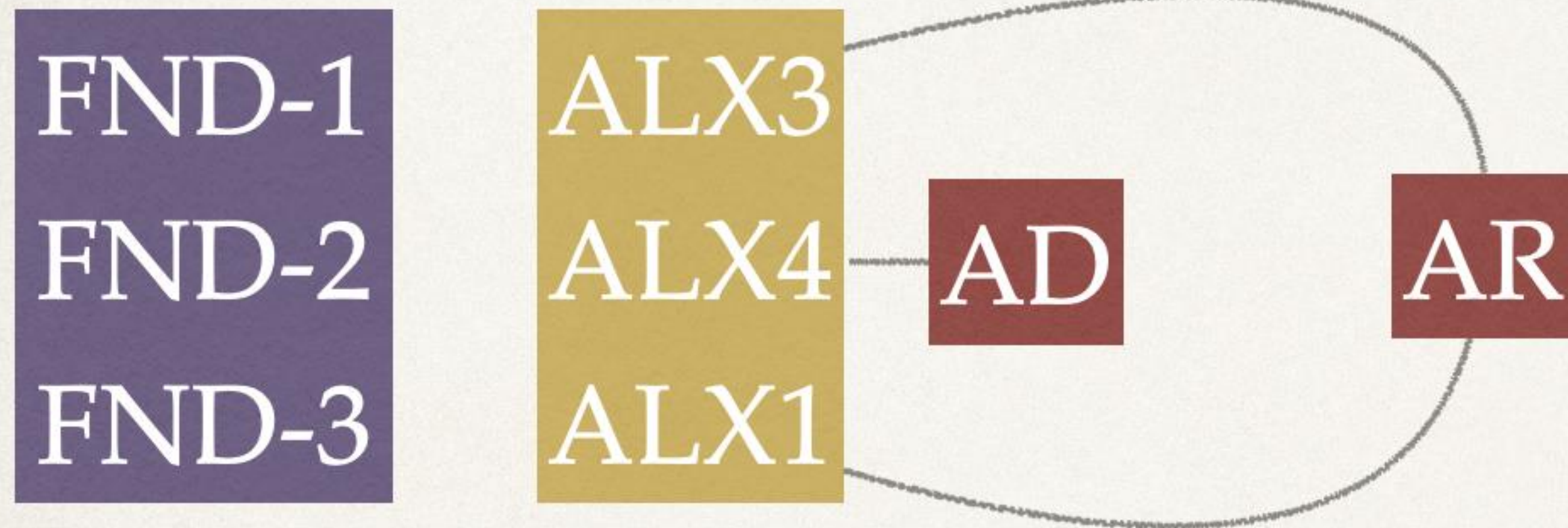
Displàsia frontonasal

- ❖ Trastorns ossis (cara i cap)
- ❖ Deficient desenvolupament embriològic de la prominència frontonasal.
- ❖ Poc frequent.
- ❖ Apèndix nasals, fisura llavi palatina, alteracions oculars, pèrdua auditiva, encefalocele i/o agenesia del cos callós.

Arrel nasal ampla




Displàsia frontonasal



ALX3

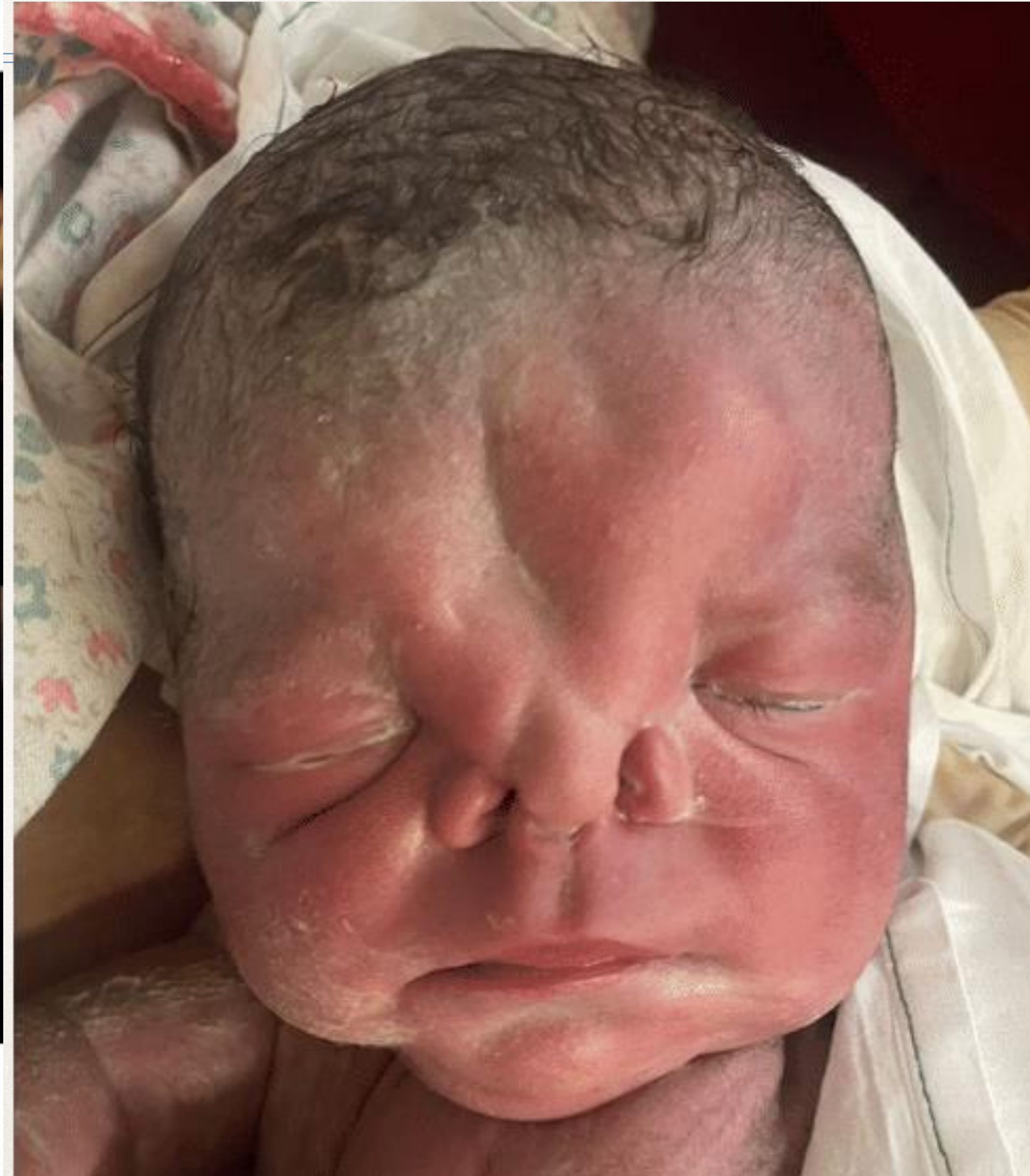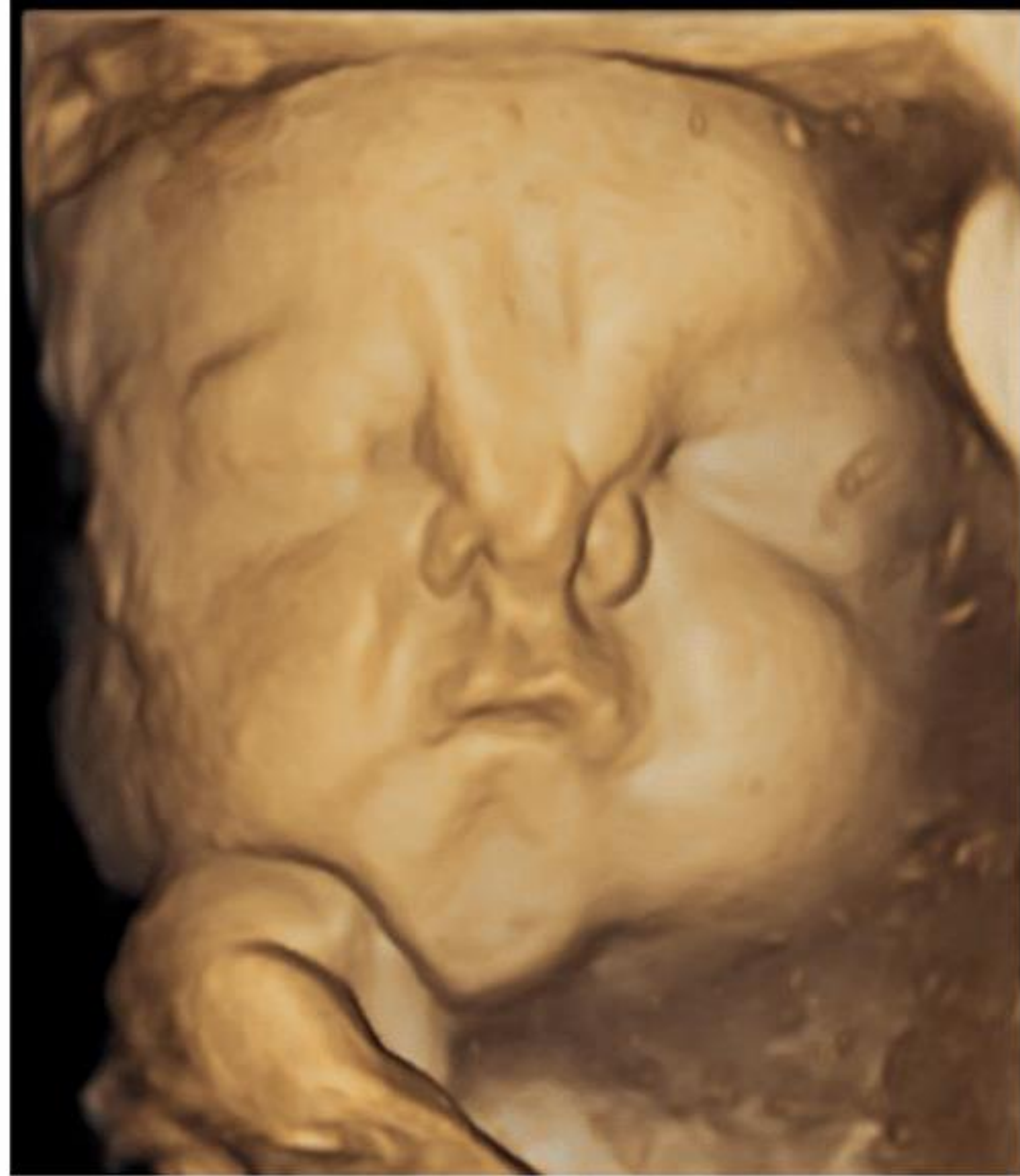ALX4

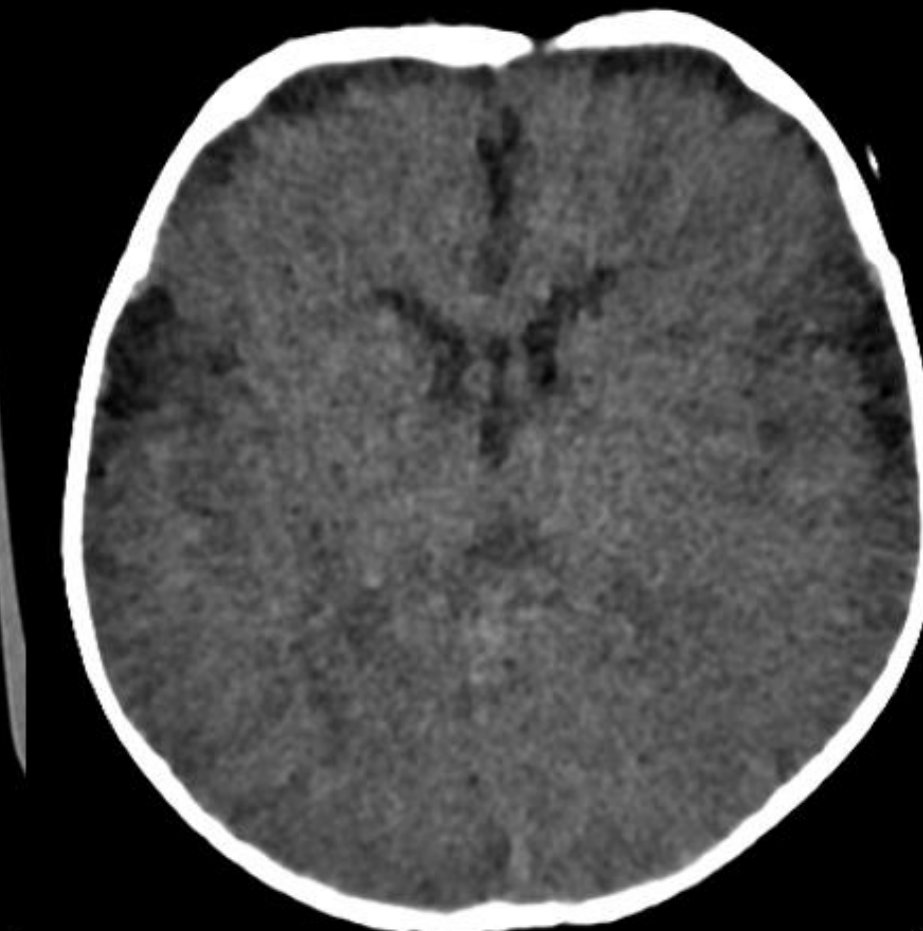
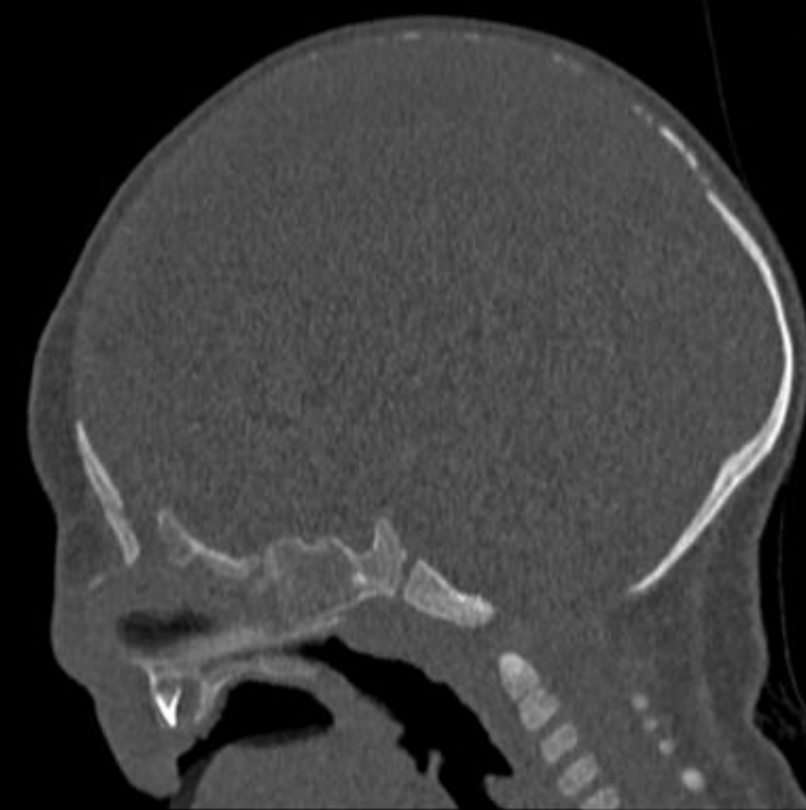
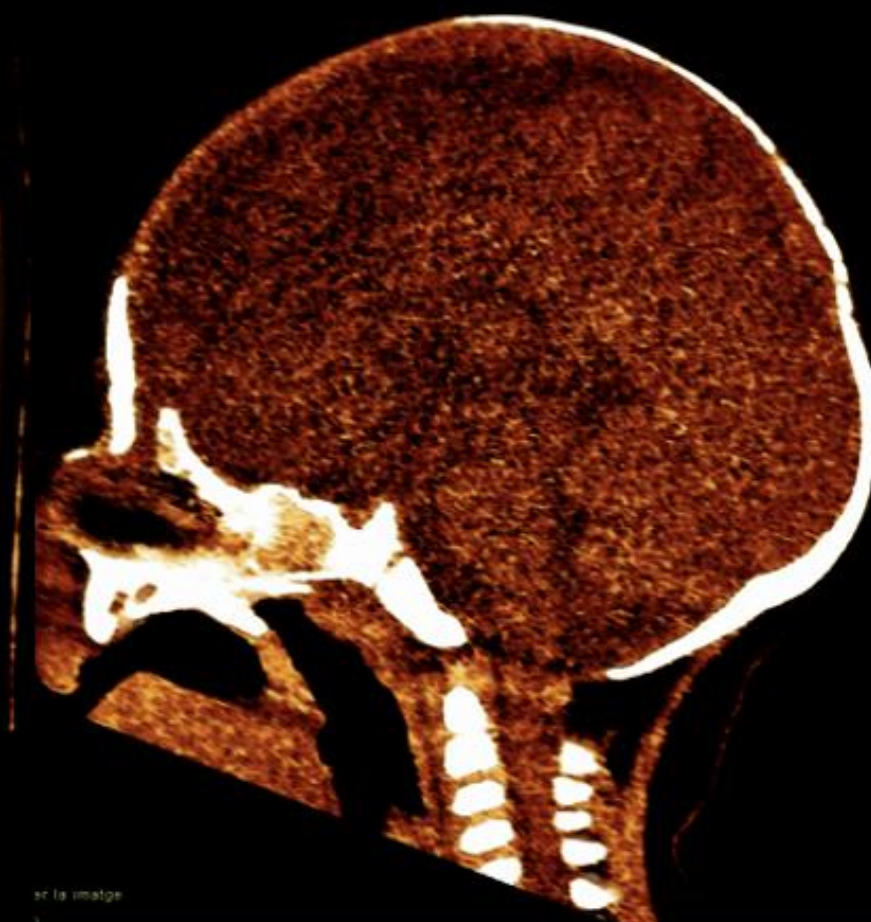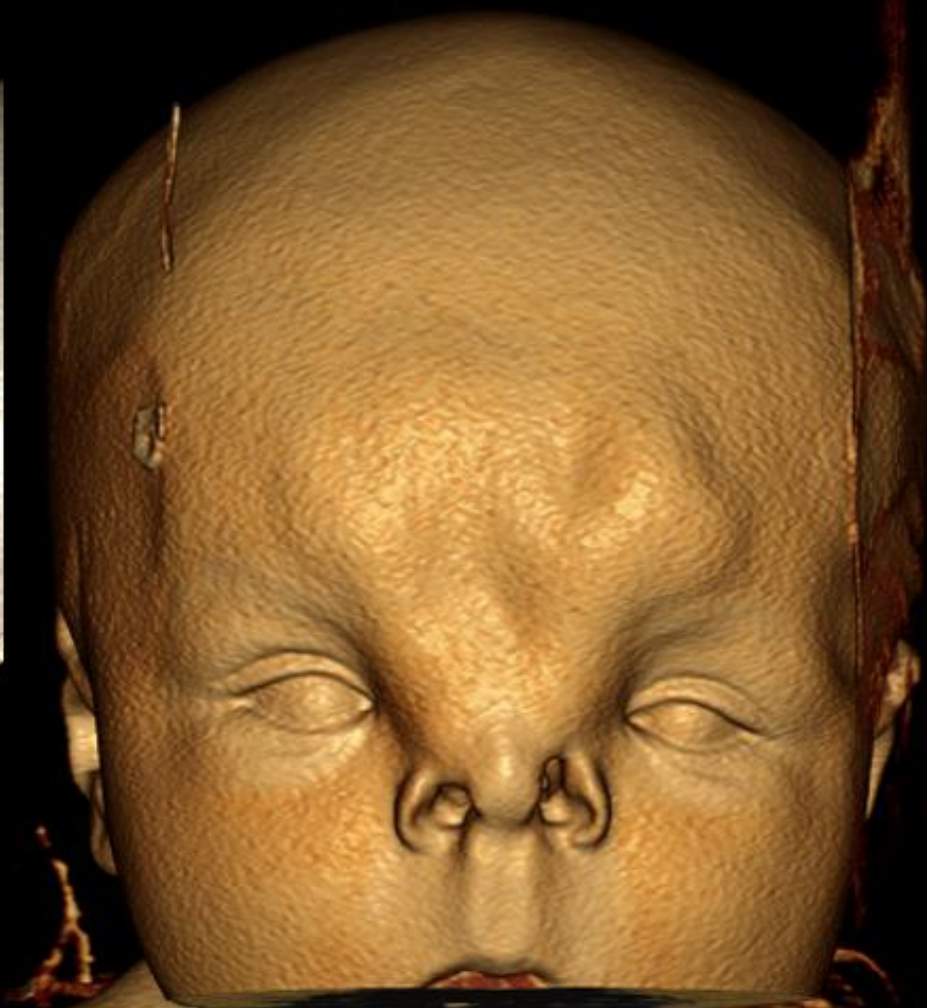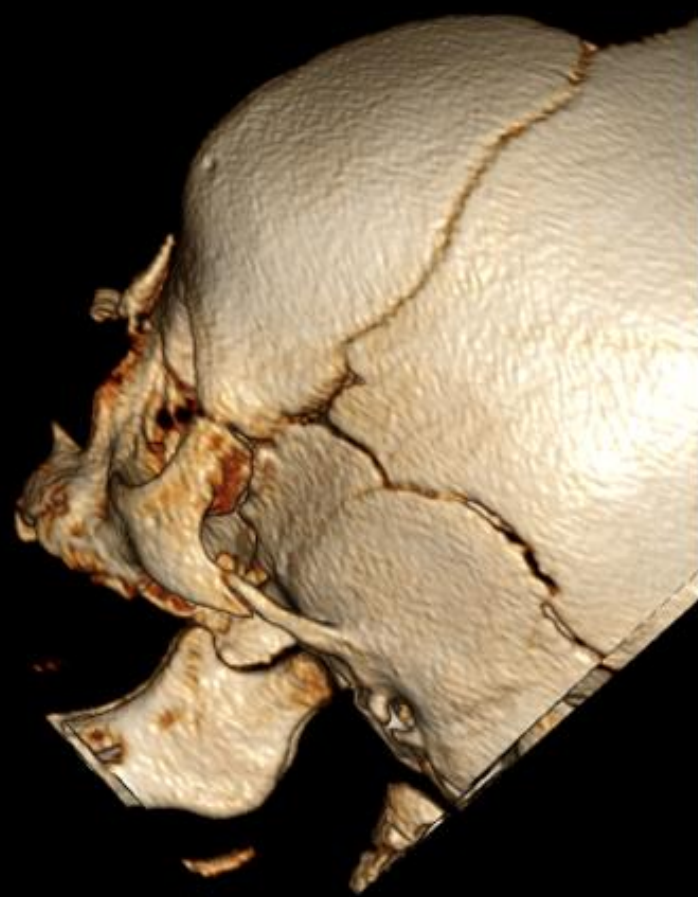


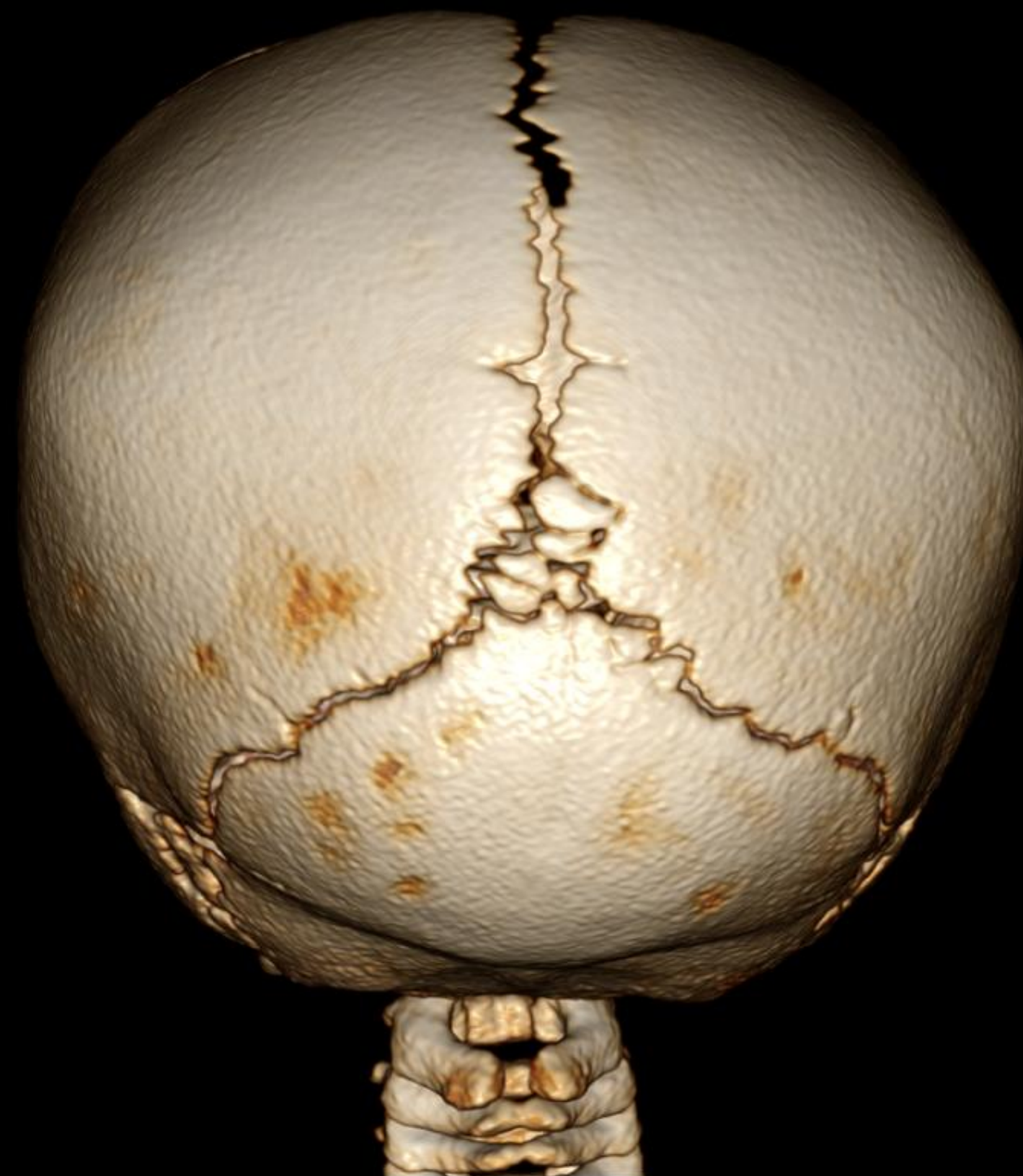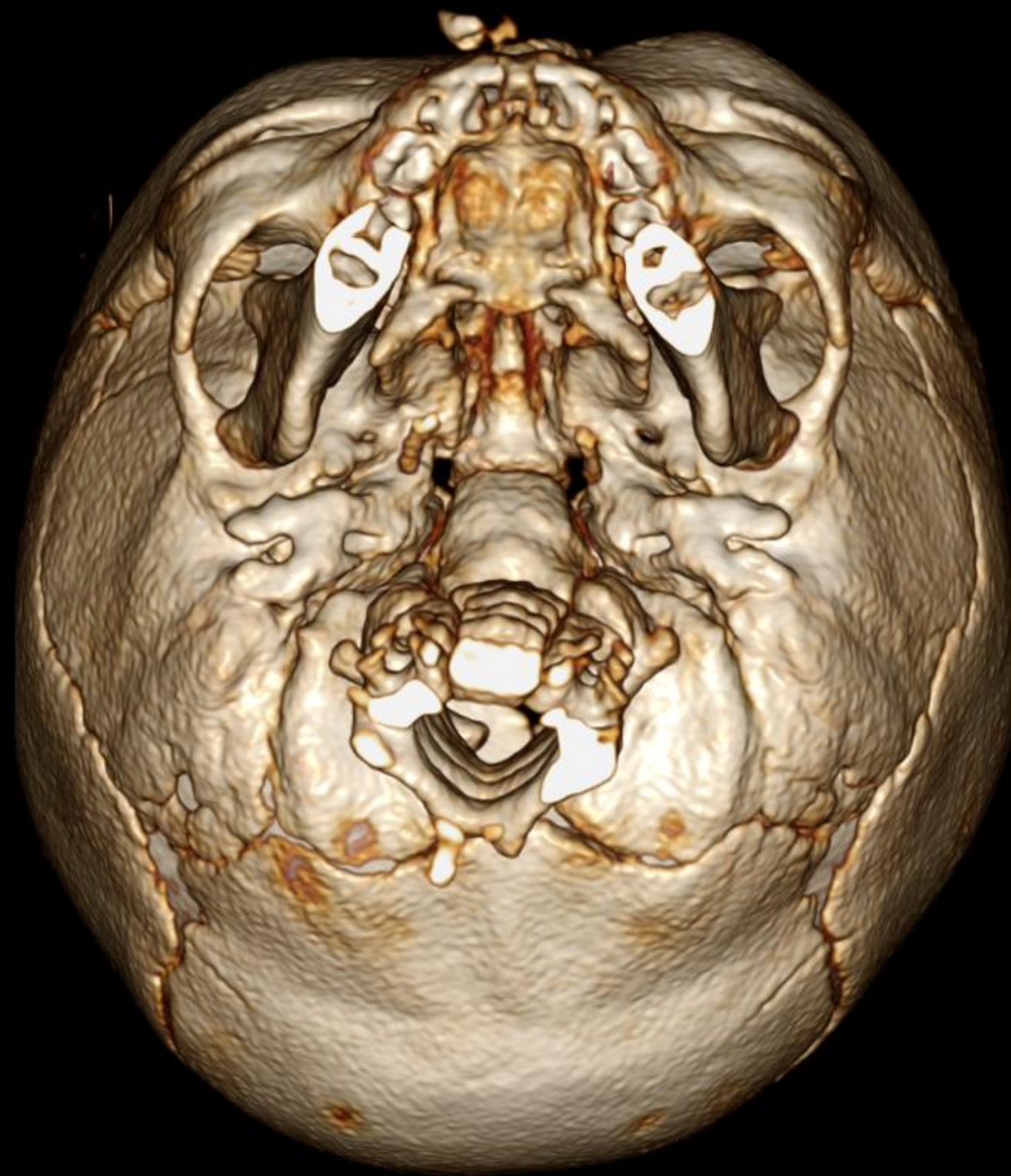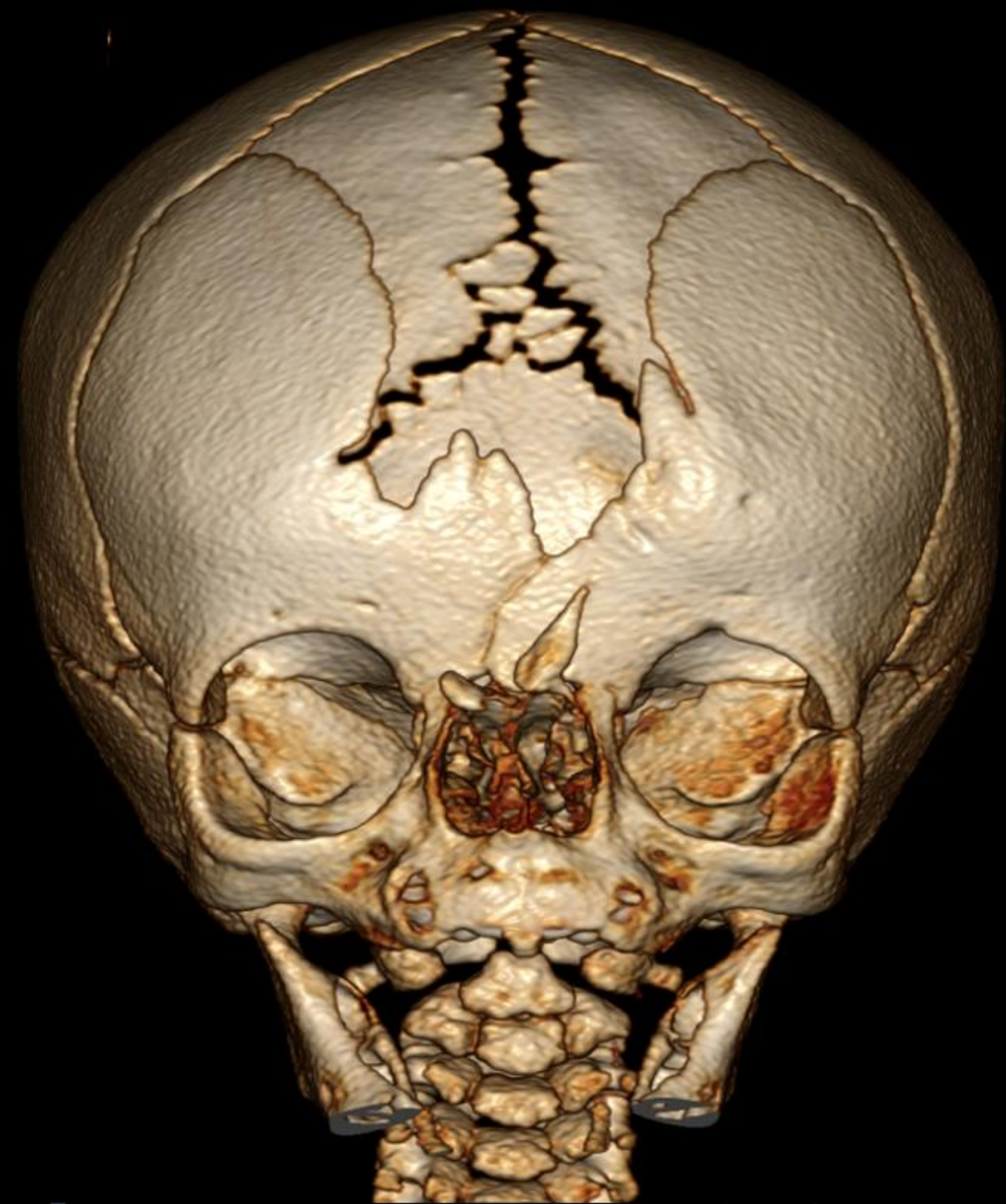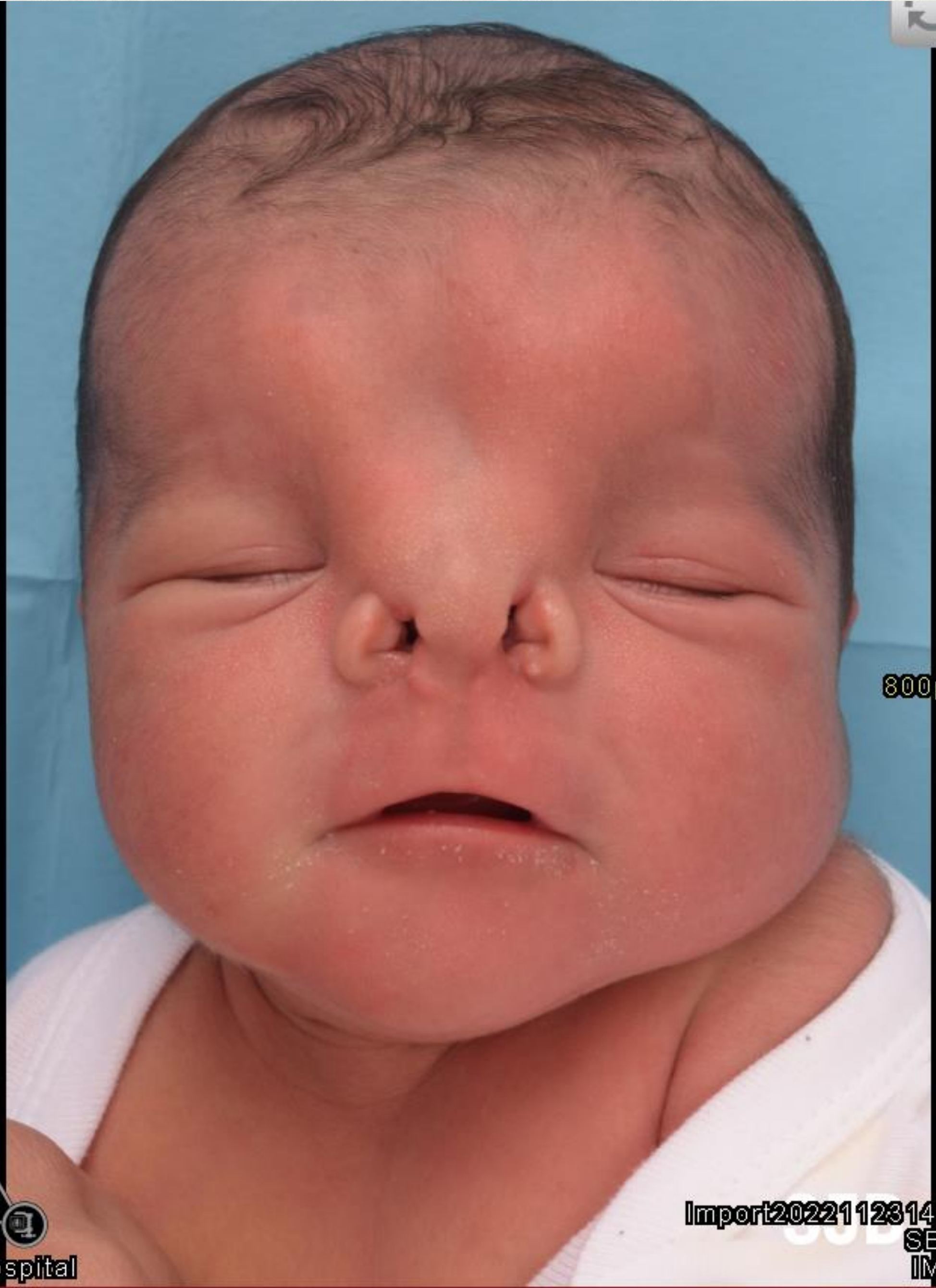ALX1



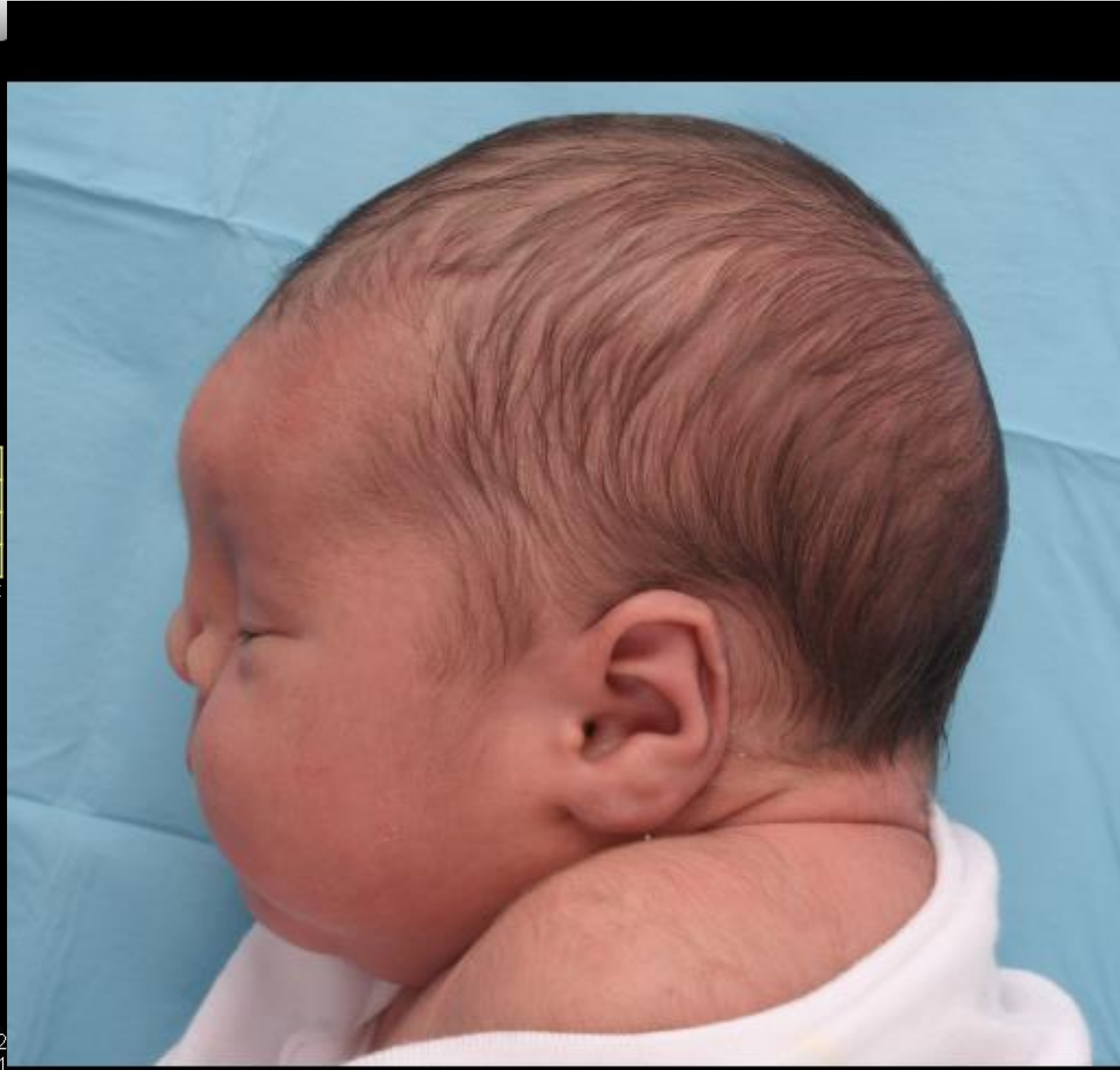Naixement







800px



Hospital

Import202211231442
SE:1
IM:2

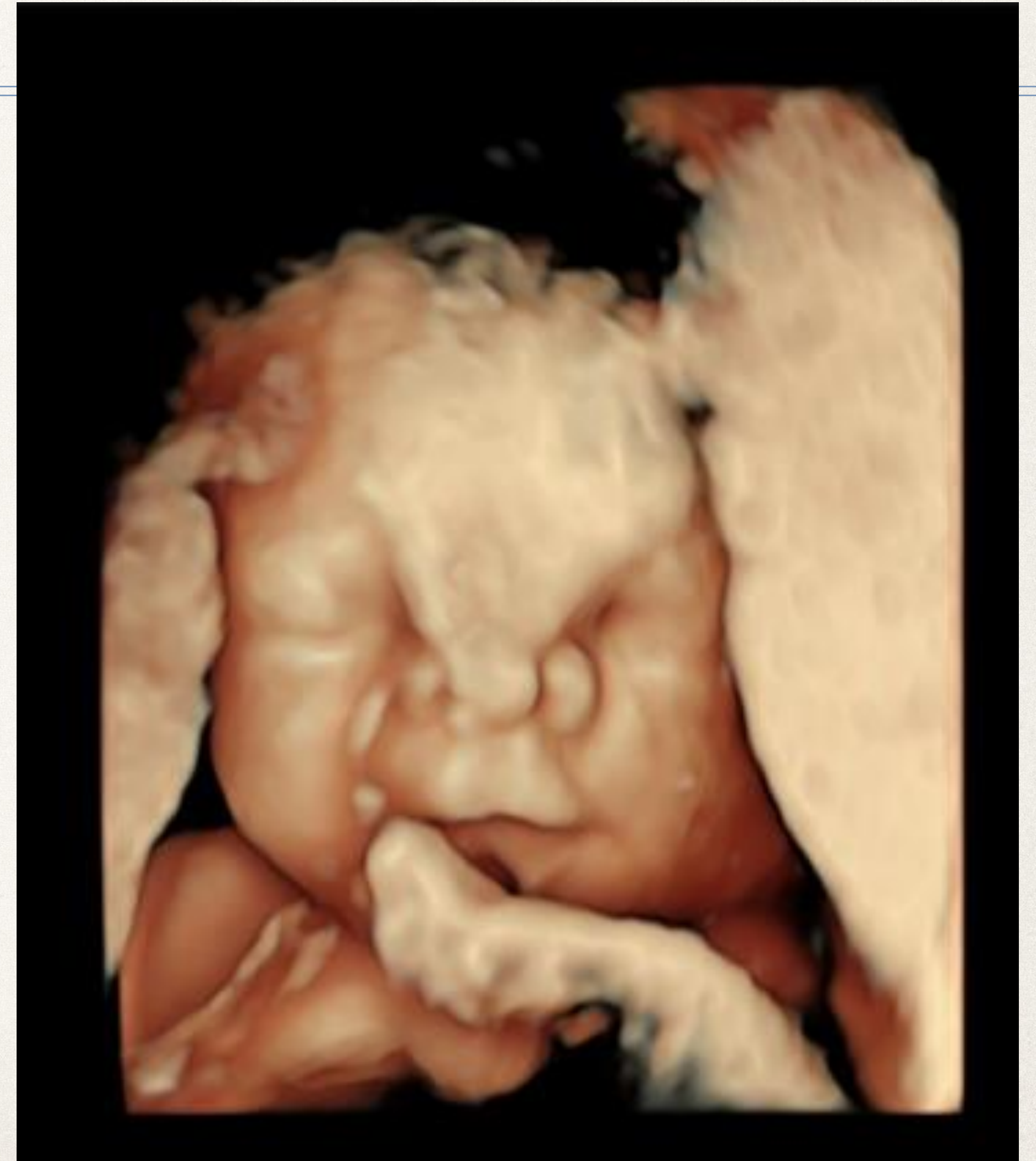Conclusions

Anomalia fetal poc freqüent

Entendre anomalia i les seves associacions

Consell a la família previ al naixement

Maneig multidisciplinar



Bibliografía

Farlie PG, Baker, NL, YAP P, Tan TY. Molecular Syndromology: Frontonasal Dysplasia: Towards an Understanding of Molecular and Developmental Aetiology. 2016; 7:312-321. Disponible en: <https://www.karger.com/Article/Pdf/450533>

Gaball CW, Yenchu MW, Kosnik S. Frontonasal dysplasia, Otolaryngology- Head and neck surgery. 2016Vol 133, issue 4. p637-638

UZ E, Alanas Y, Aktas D. Et. Al. Disruption of *ALX1* Causes Extreme Microphthalmia and Severe Facial Clefting: Expanding the Spectrum of Autosomal-Recessive *ALX*-Related Frontonasal Dysplasia. AJHG. Vol. 86, Issue 5. May 2010.

Akarsu N. Hacettepe University Medical Faculty. Frontonasal Dysplasia. Rare Diseases. January 03, 2017. Disponible en: <https://rarediseases.org/rare-diseases/frontonasal-dysplasia/>

Lourenço C, Godinho C, Marinho M. et. Al. . Journal Clinic Ultrasound: Prenatal diagnosis of isolated frontonasal dysplasia: a case report. 2021 FEB;49(2):145-148. Disponible en: <https://pubmed.ncbi.nlm.nih.gov/32374429/>

Ondeck CL, Pretorius D, McCaulley J, et. Al. Ultrasonographic prenatal imaging of fetal ocular and orbital abnormalitie. Survey of Ophthalmology. Nov-Dec 2018, 63(6): 745-753. Disponible en: <https://pubmed.ncbi.nlm.nih.gov/29705173/>