

Trombosi del si dural

Míriam Pérez Cruz

BCNatal – *Barcelona Center for Maternal Fetal and Neonatal Medicine,
Hospital Sant Joan de Déu and Hospital Clínic, University of Barcelona.*

Antecedents

Gestant de 40 anys.

AF: sense interès clínic

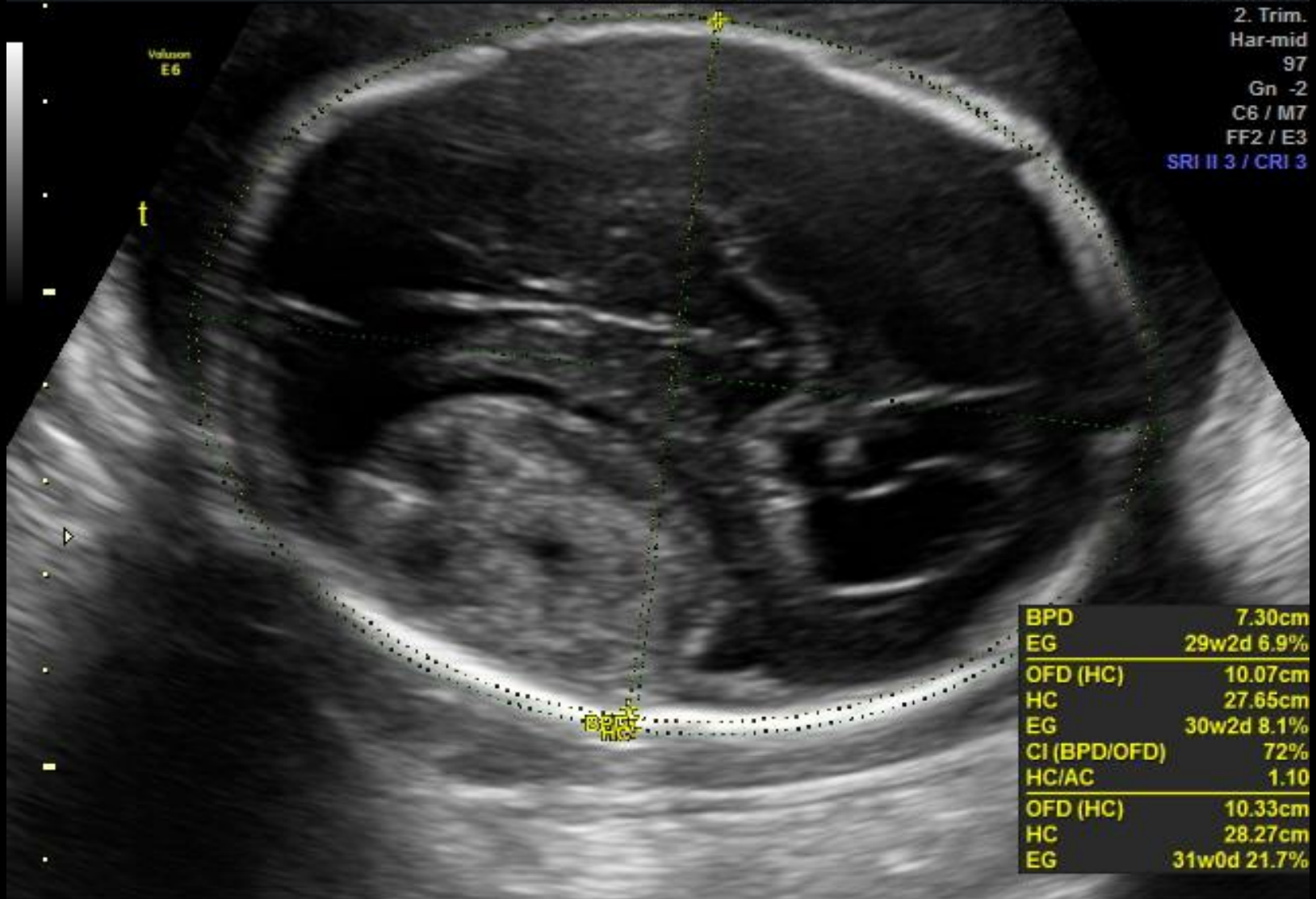AP: hipotiroidisme, anticoagulant lúpic positiu dèbil.

AGO: 0.0.0.0 Esterilitat primària, gestació per FIV (gamets propis)

Control de gestació correcte

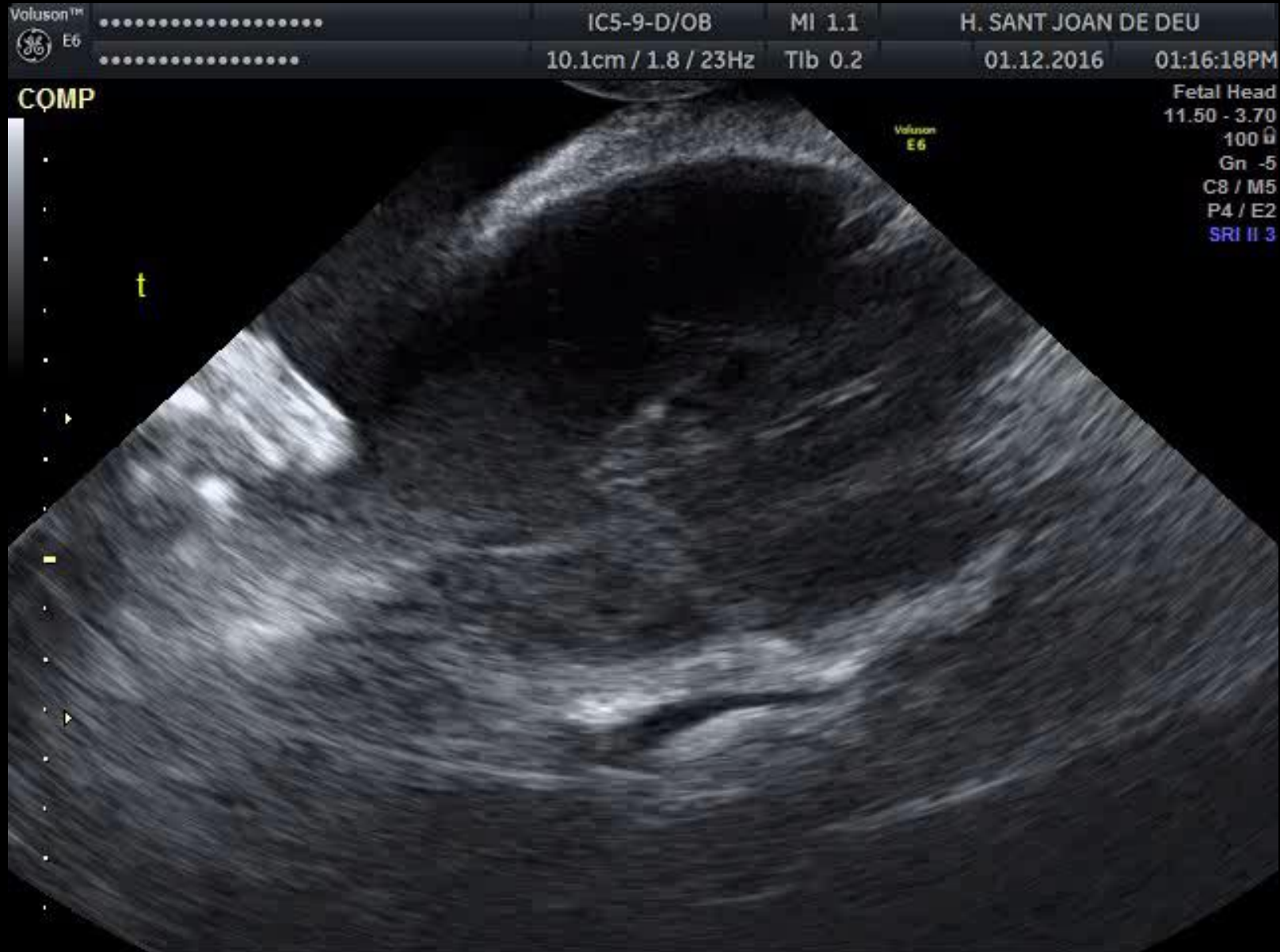
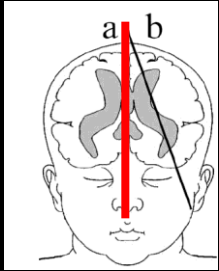
30'5 SG 1^a visita a la Unitat de Patologia Placentària per p15 + IPmAUt>p95 + ICP <p5.

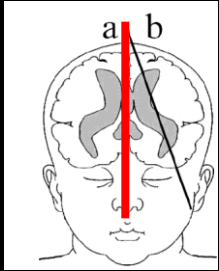
Voluson™ E6 C1-5-D/OB MI 1.1 H. SANT JOAN DE DEU
 14.2cm / 2.1 / 23Hz Tlb 0.1 01.12.2016 12:46:51PM



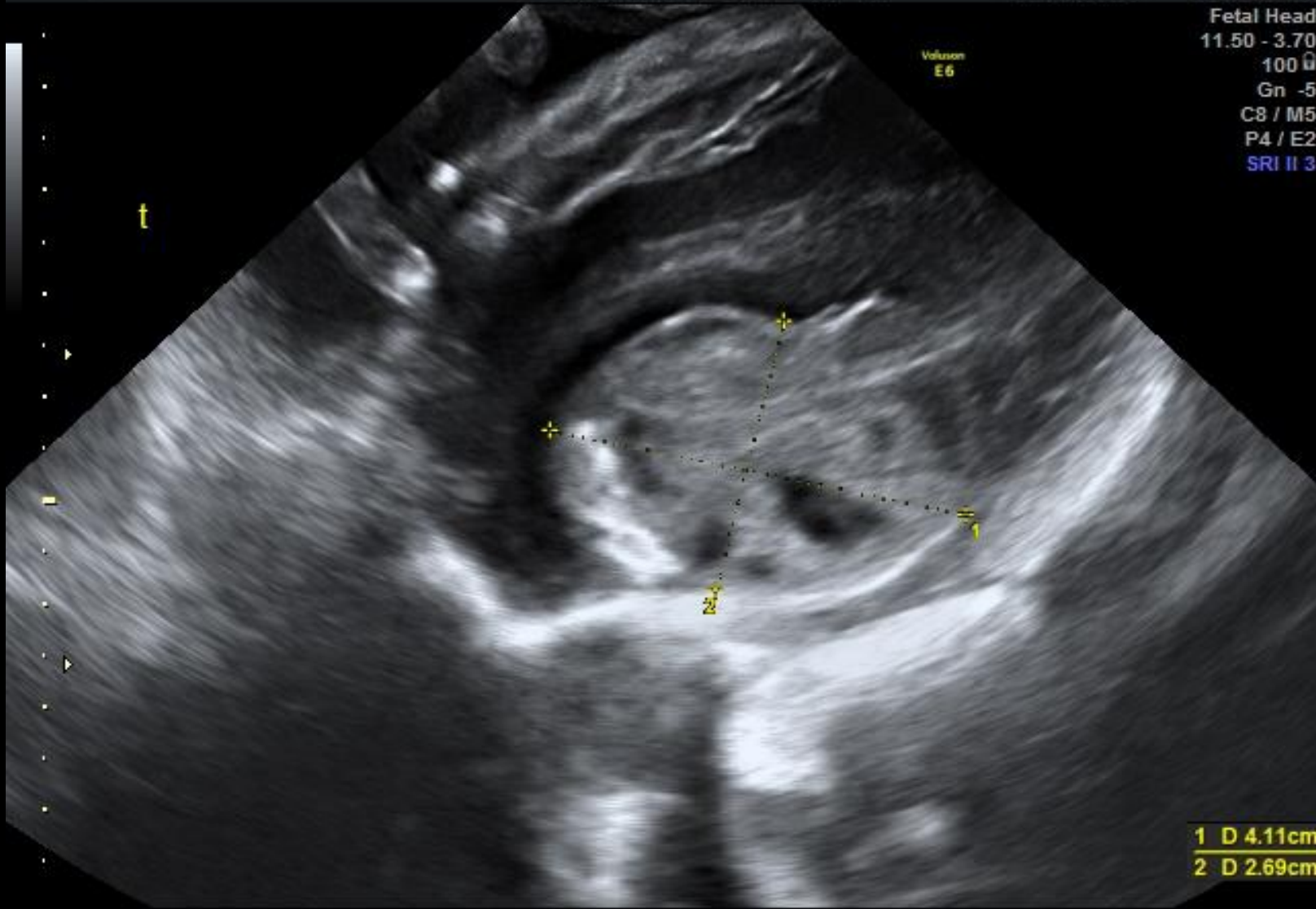
2. Trim.
 Har-mid 97
 Gn -2
 C6 / M7
 FF2 / E3
 SRI II 3 / CRI 3

BPD	7.30cm
EG	29w2d 6.9%
OFD (HC)	10.07cm
HC	27.65cm
EG	30w2d 8.1%
CI (BPD/OFD)	72%
HC/AC	1.10
OFD (HC)	10.33cm
HC	28.27cm
EG	31w0d 21.7%



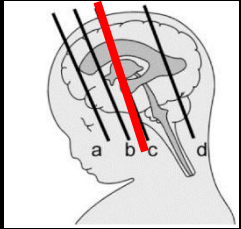


Voluson™ IC5-9-D/OB MI 1.1 H. SANT JOAN DE DEU
E6 10.1cm / 1.8 / 23Hz Tib 0.2 01.12.2016 01:15:26PM

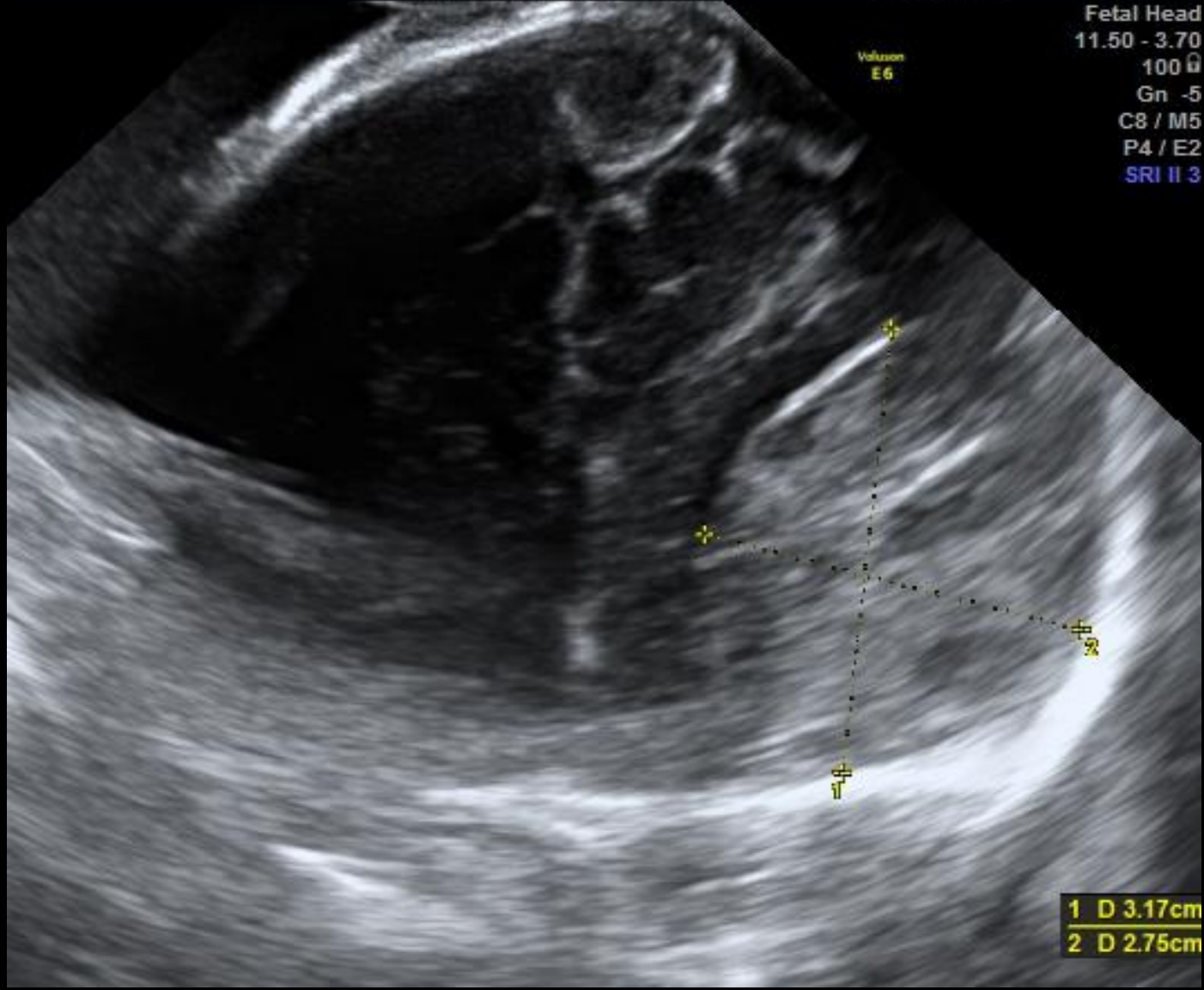


Fetal Head
11.50 - 3.70
100 U
Gn -5
C8 / M5
P4 / E2
SRI II 3

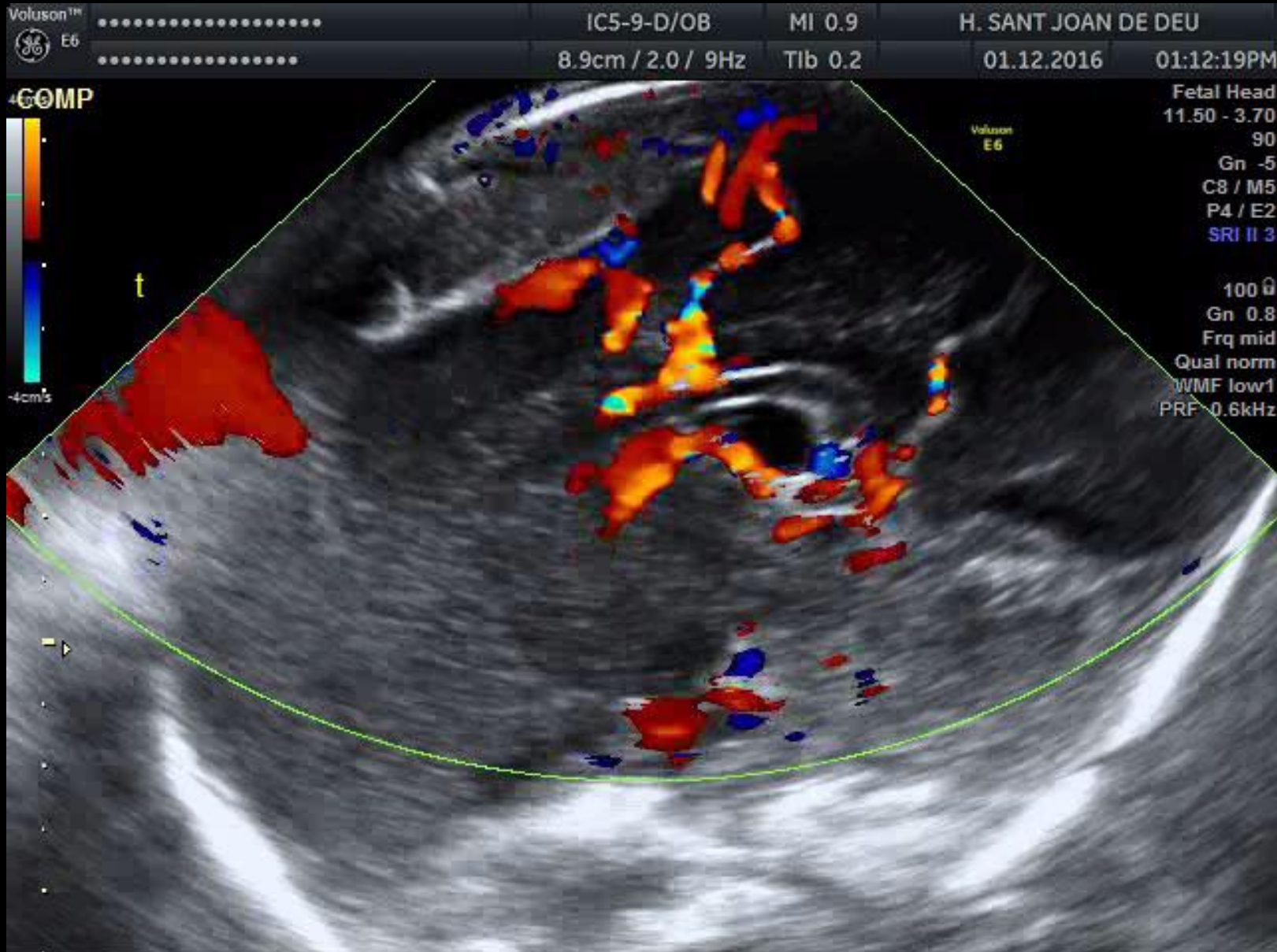
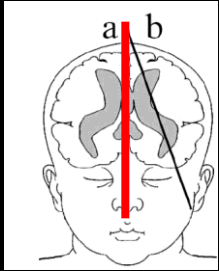
1 D 4.11cm
2 D 2.69cm

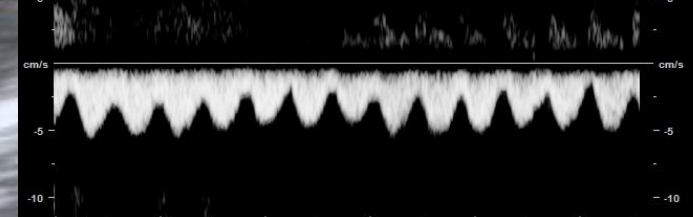
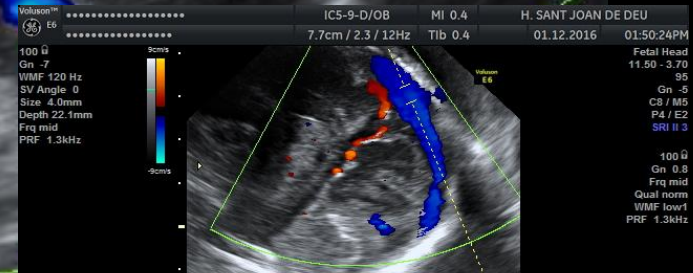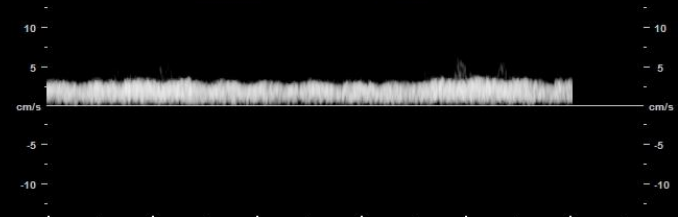
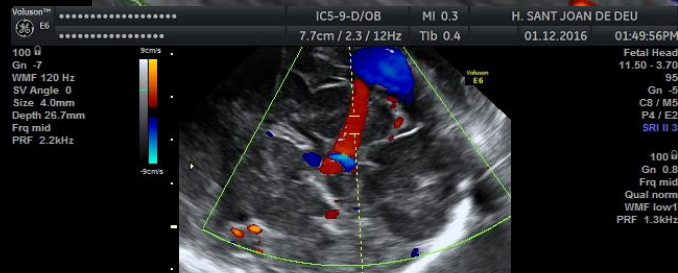
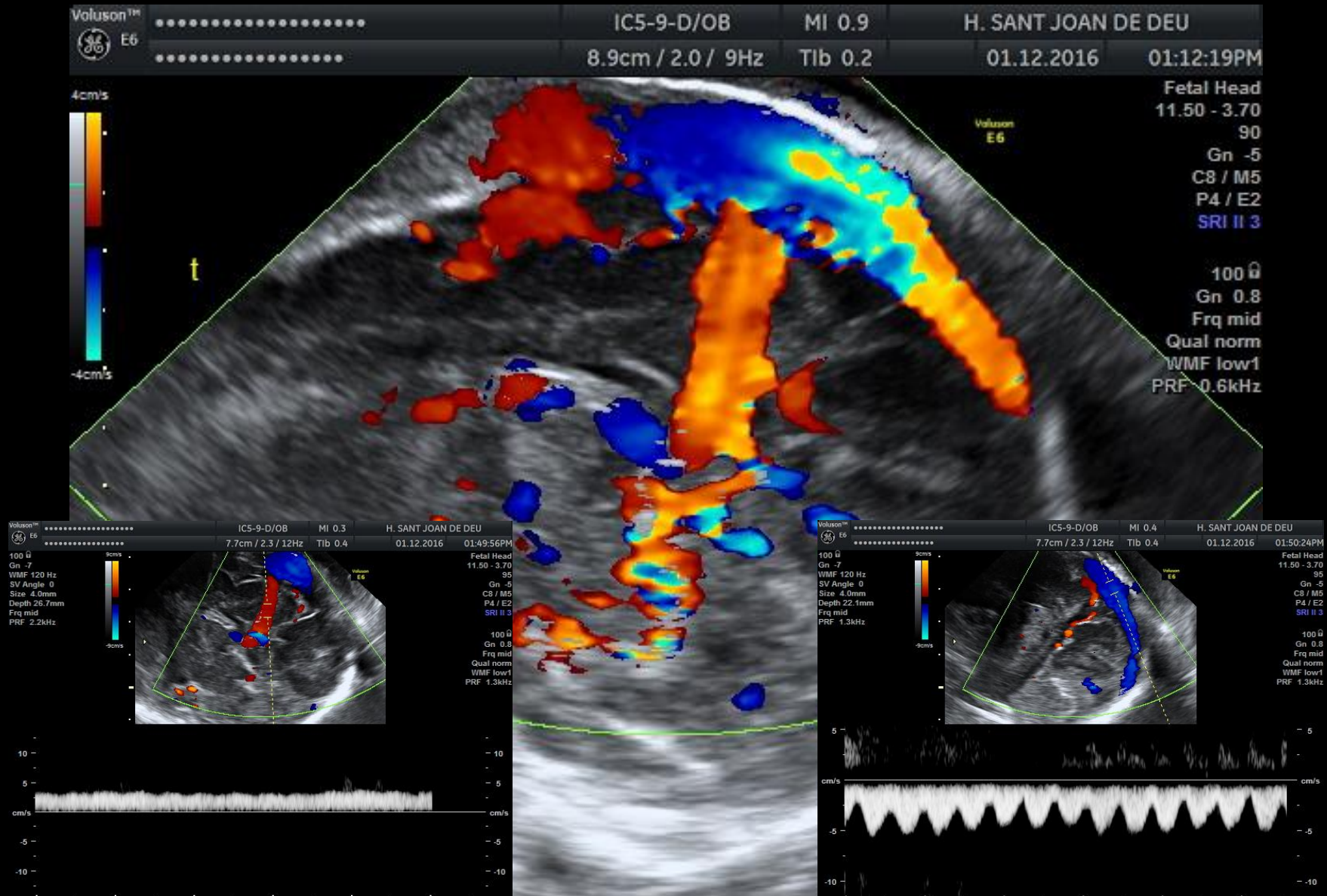
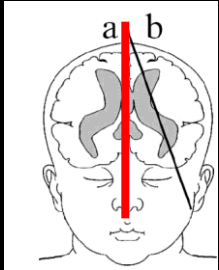


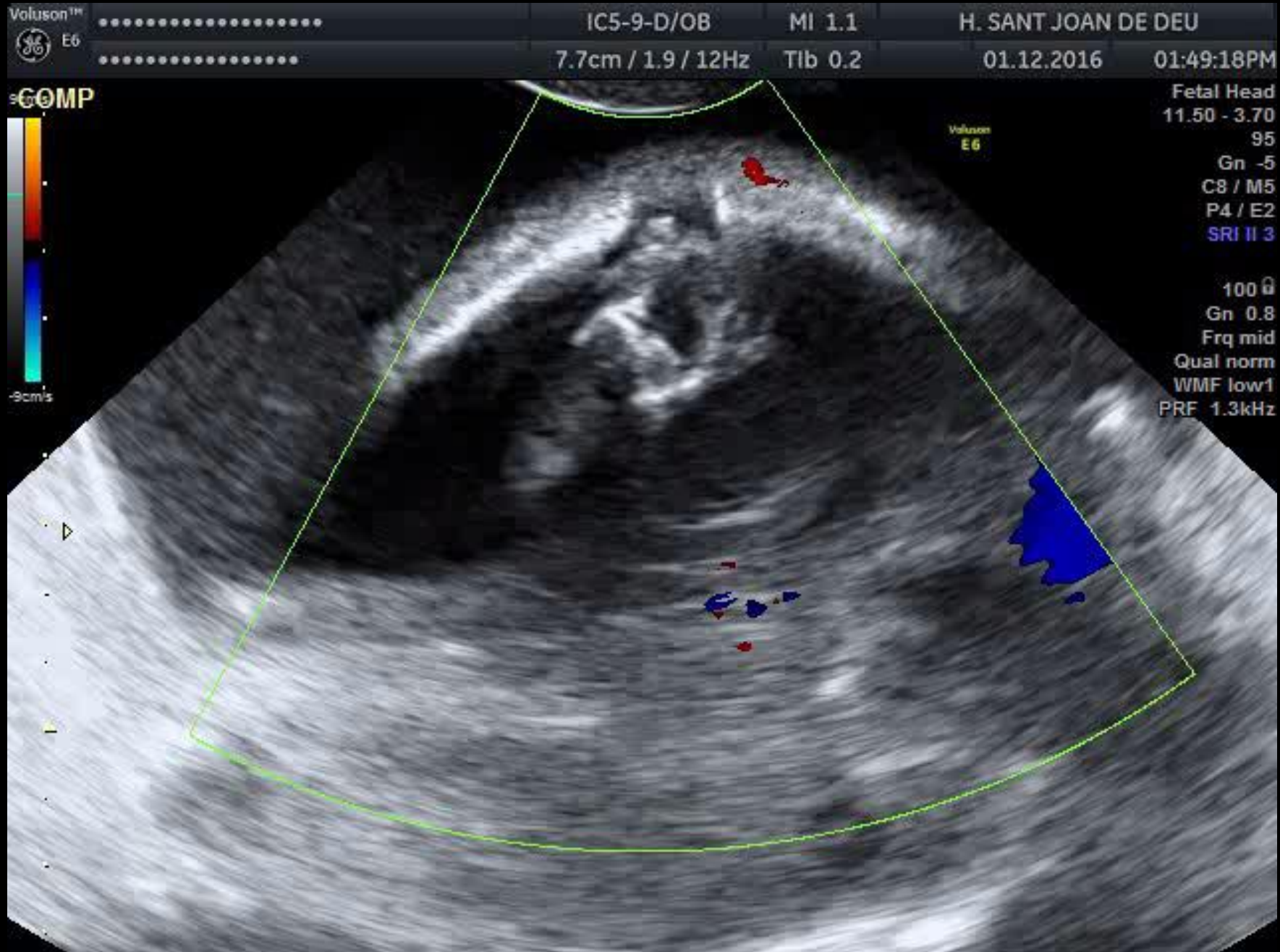
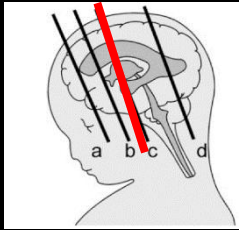
IC5-9-D/OB MI 1.1 H. SANT JOAN DE DEU
8.9cm / 2.0 / 25Hz Tib 0.2 01.12.2016 01:07:17PM

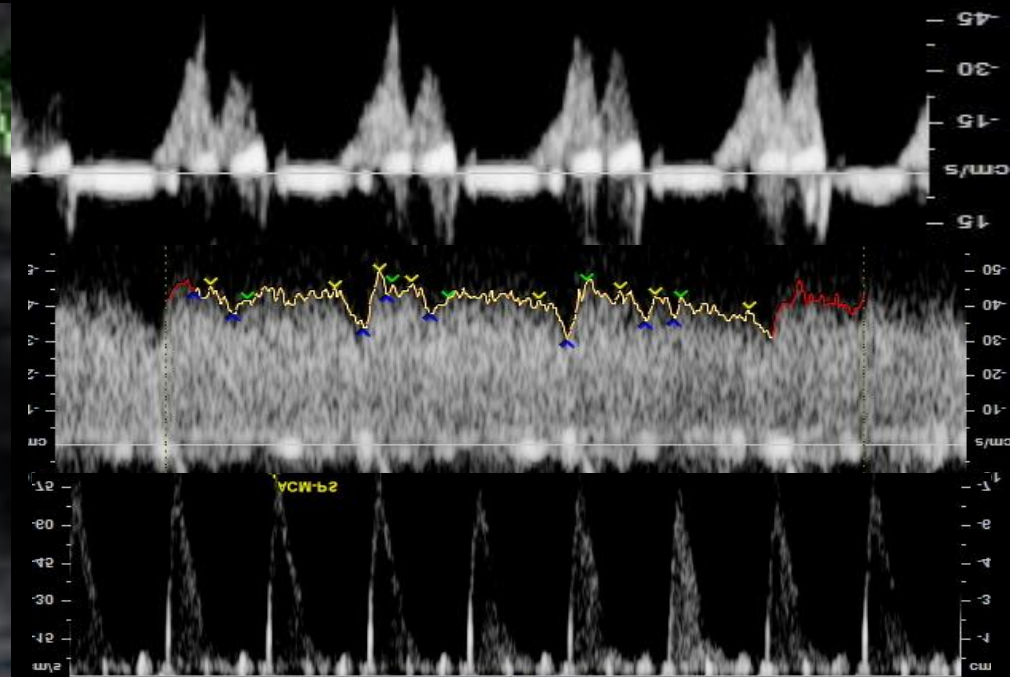
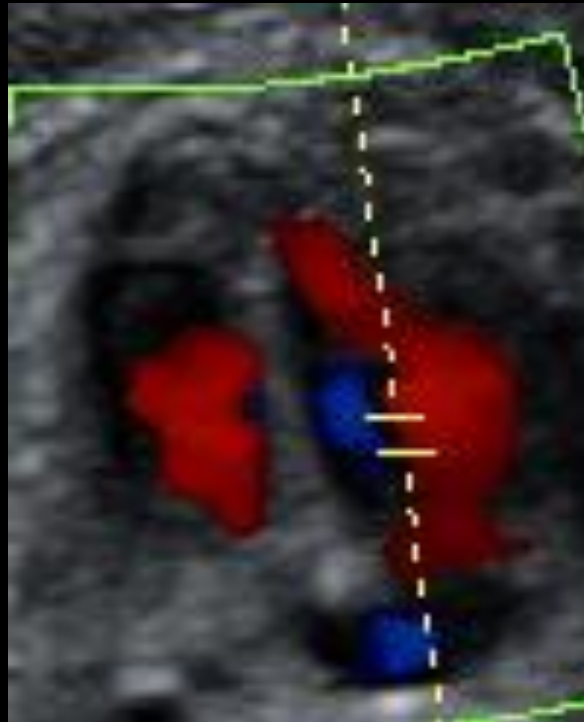
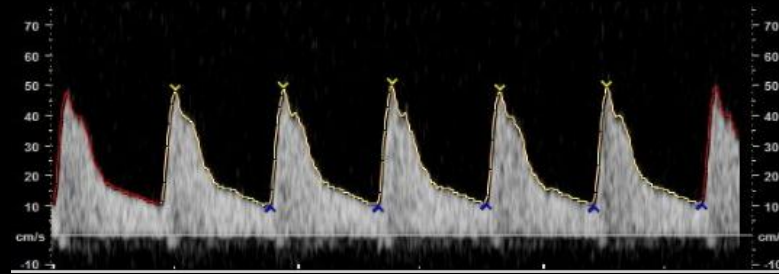
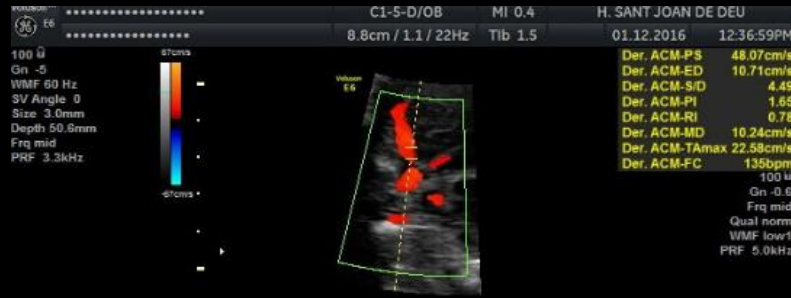

Fetal Head
11.50 - 3.70
100 μ
Gn -5
C8 / M5
P4 / E2
SRI II 3

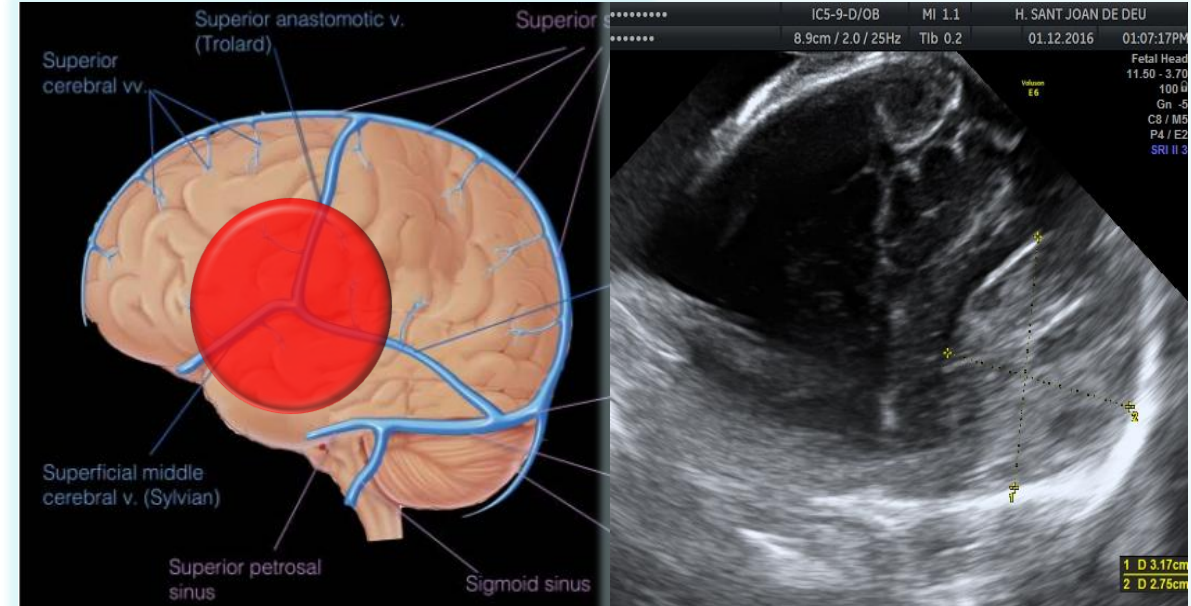
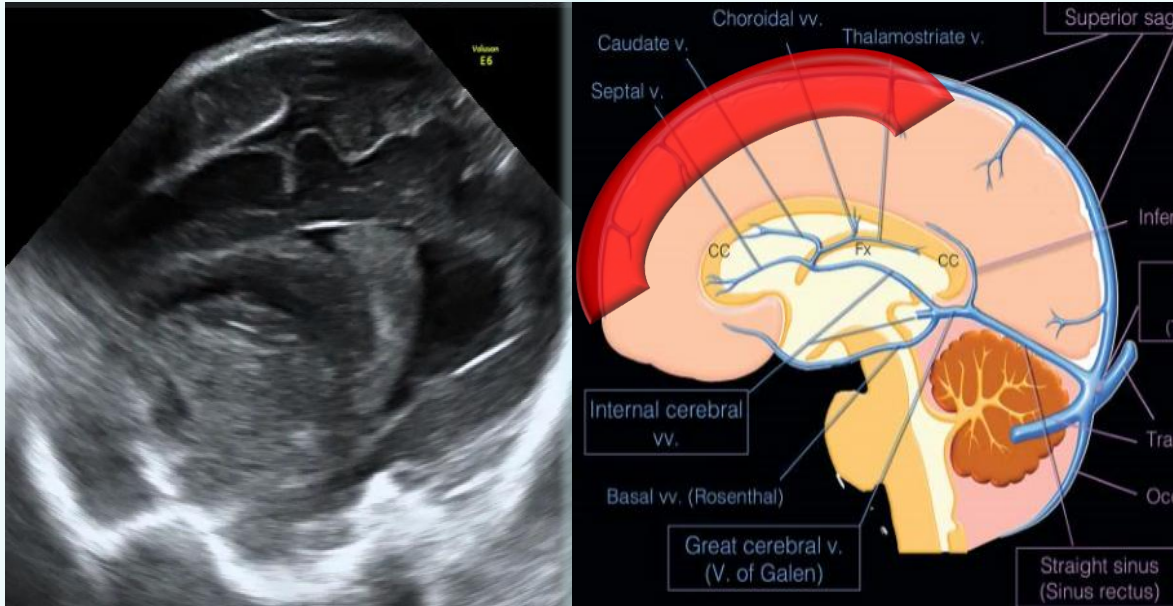






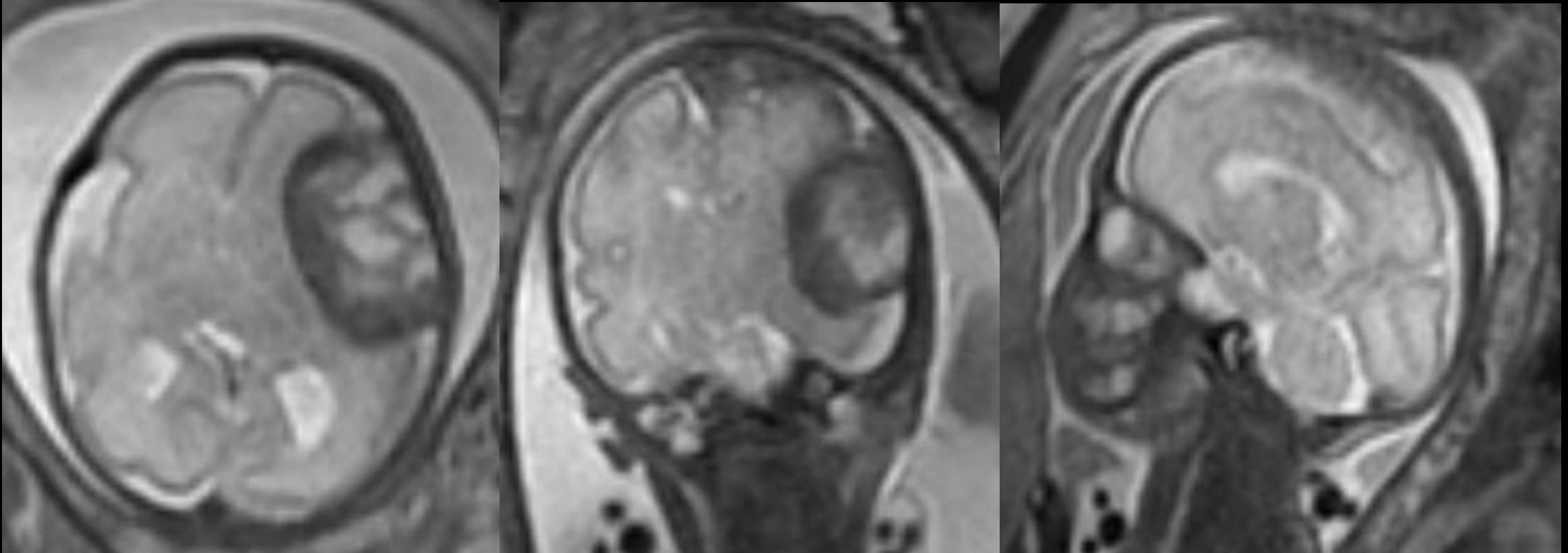


Orientació diagnòstica



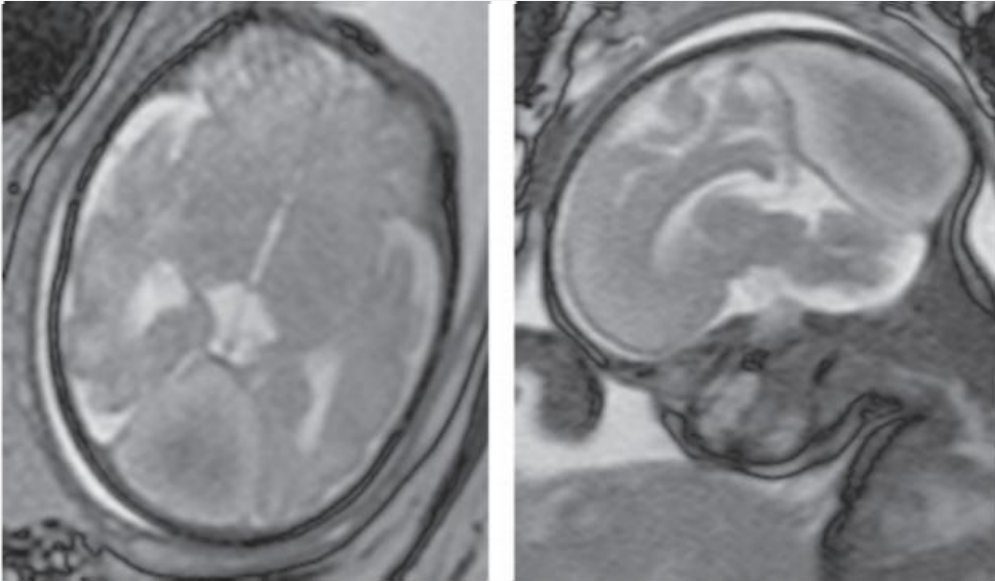
Trombosi part anterior del si sagital superior
+
Hematoma epidural

Relació?

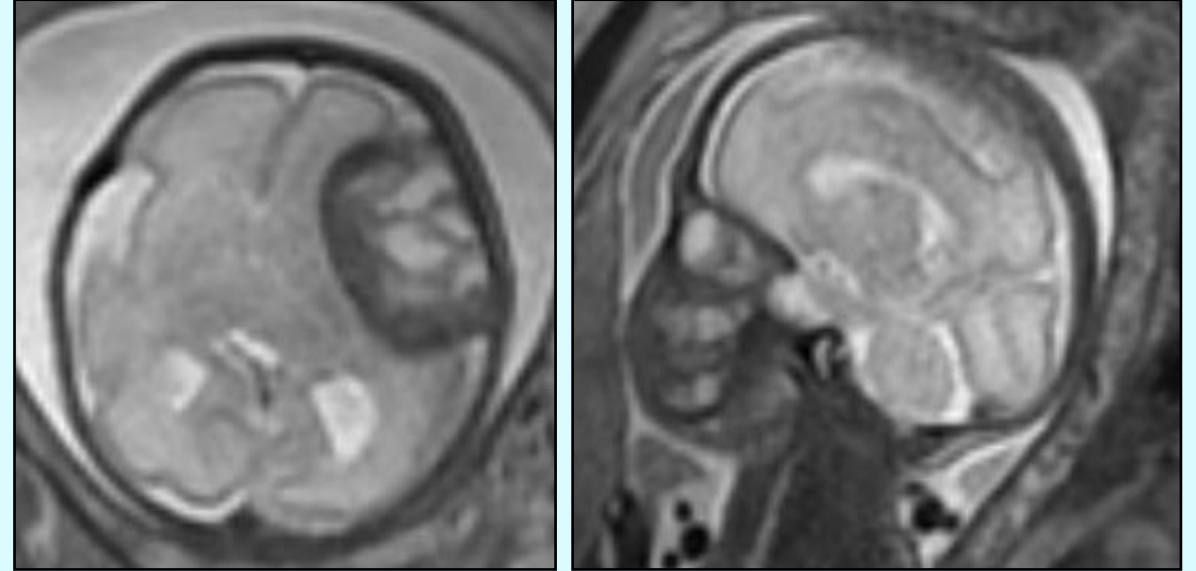


No infarts venosos
No afectació de parènquima

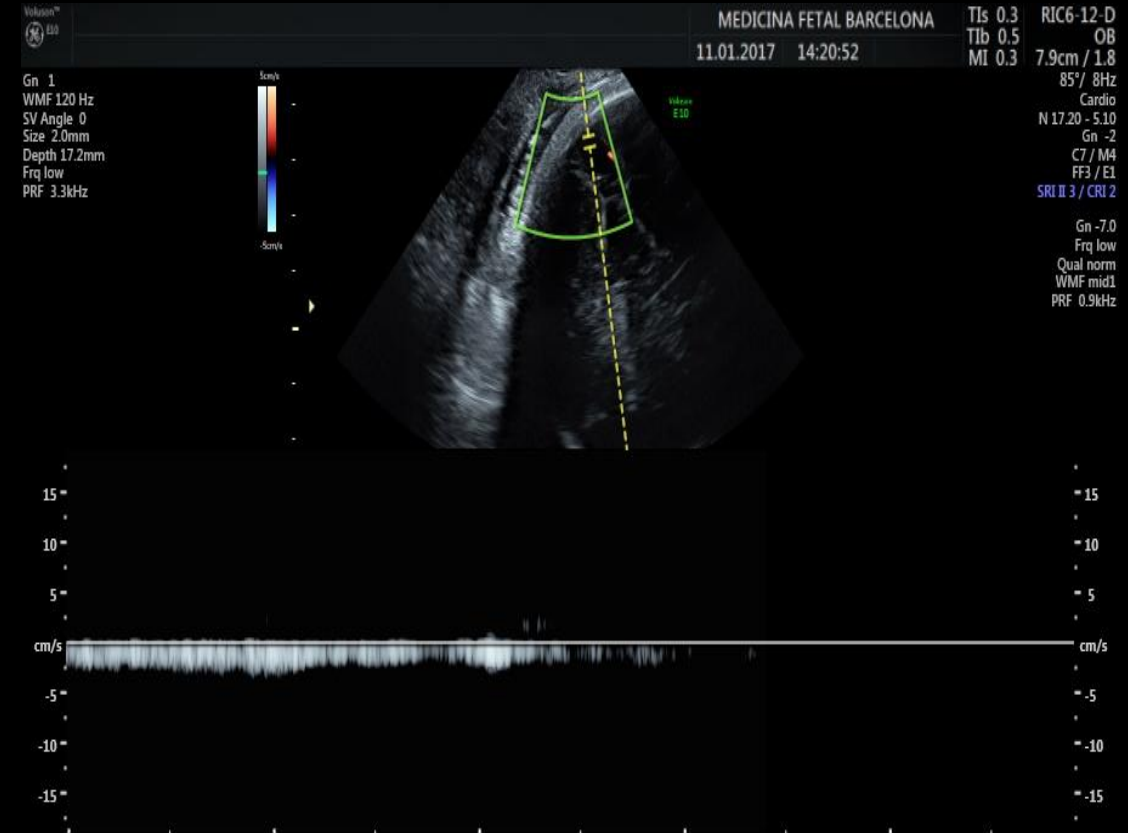
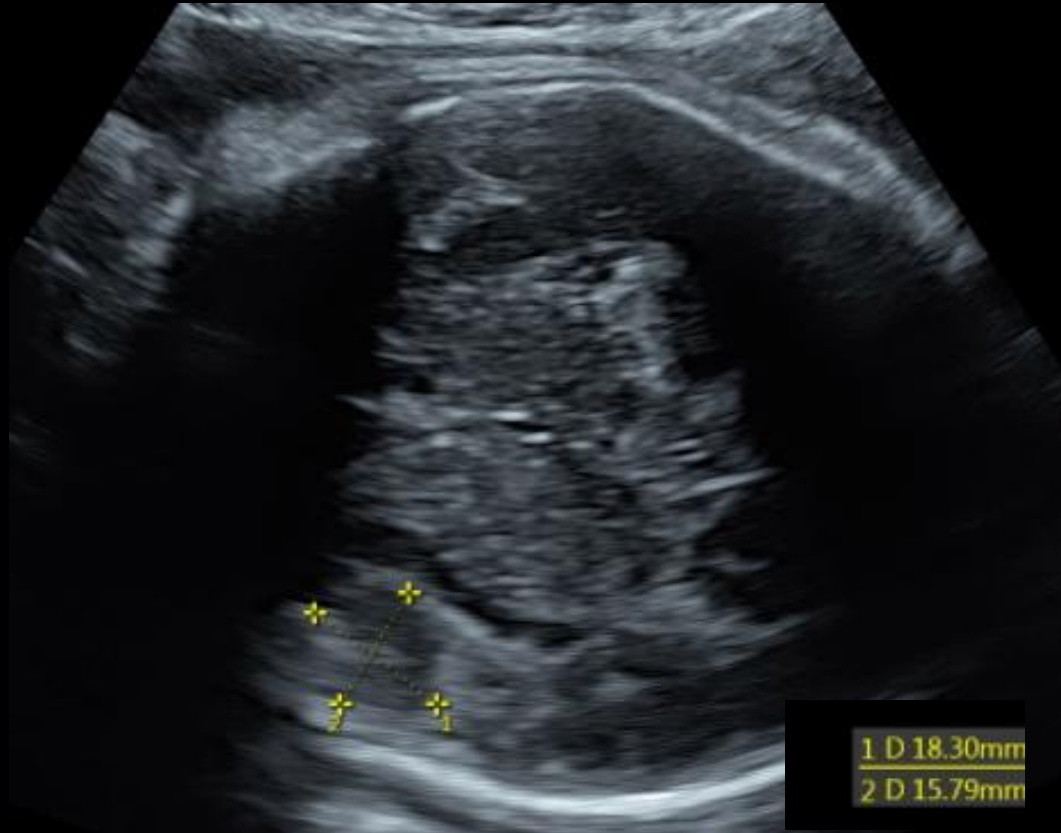
Pronòstic ?



Trombosi de la tòrcula d'Heròfil

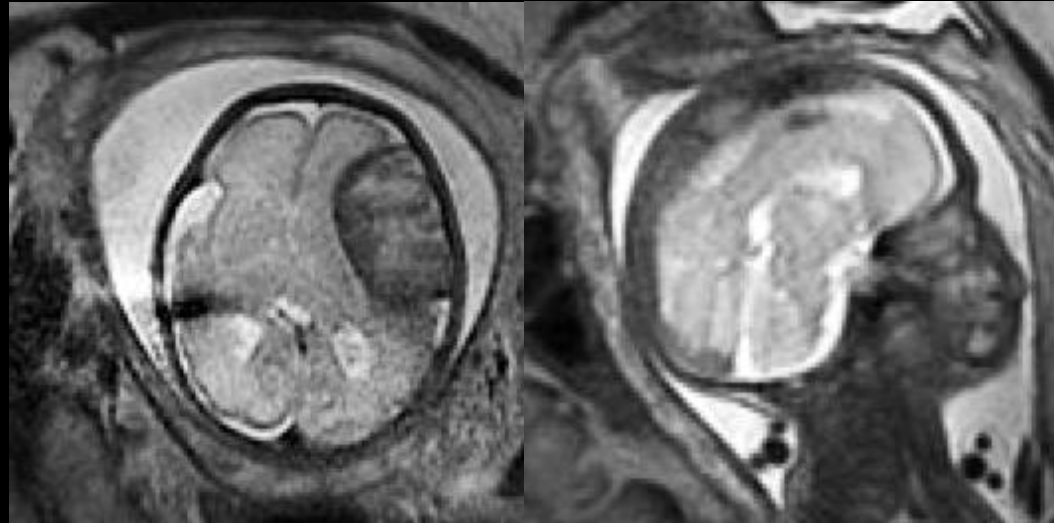


***Trombosi del si sagital superior
+
Hematoma epidural***

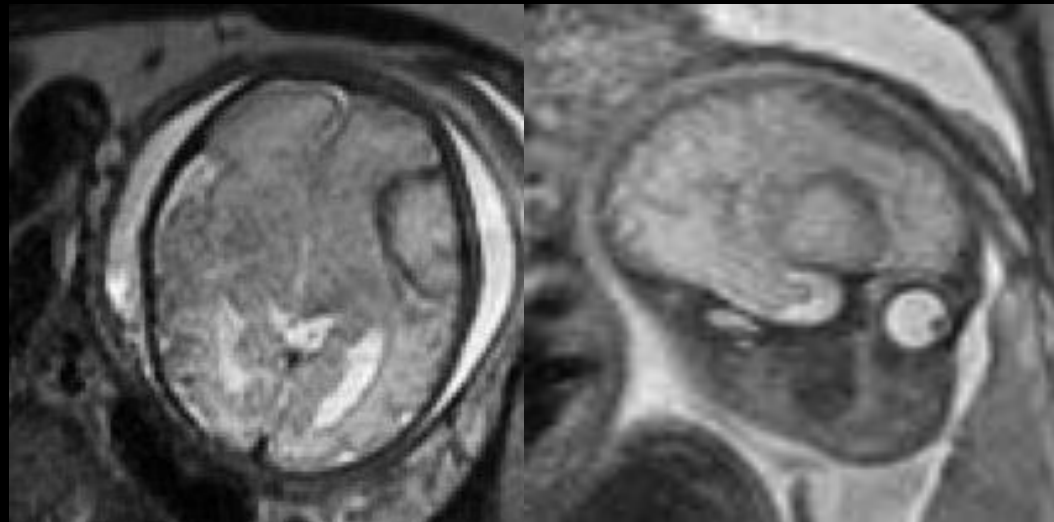


Reducció del tamany de l'hematoma i de la ingurgitació venosa

30 SG



36 SG

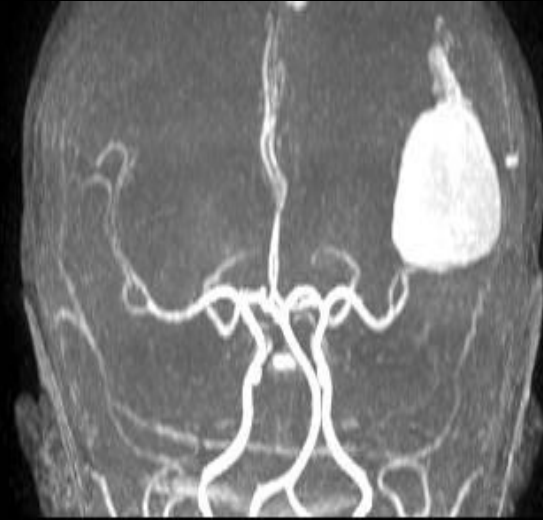
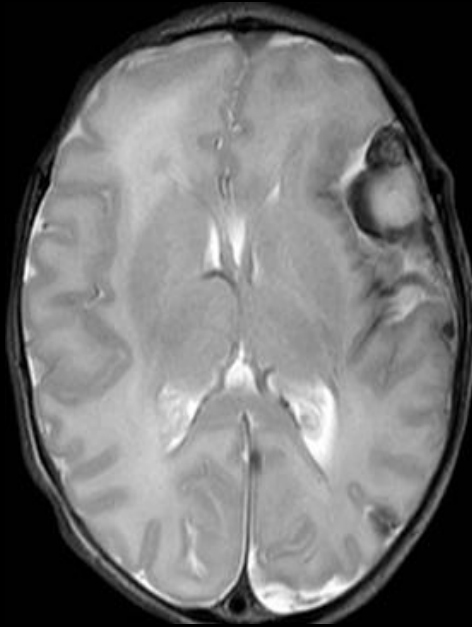
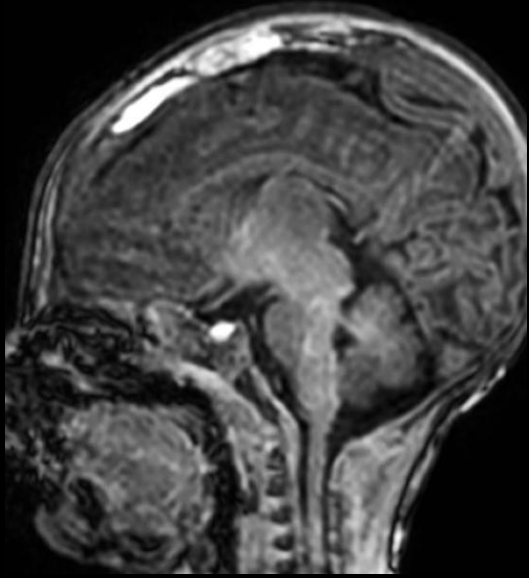


Cesària electiva a les 37,2 SG per CIR tipus I.

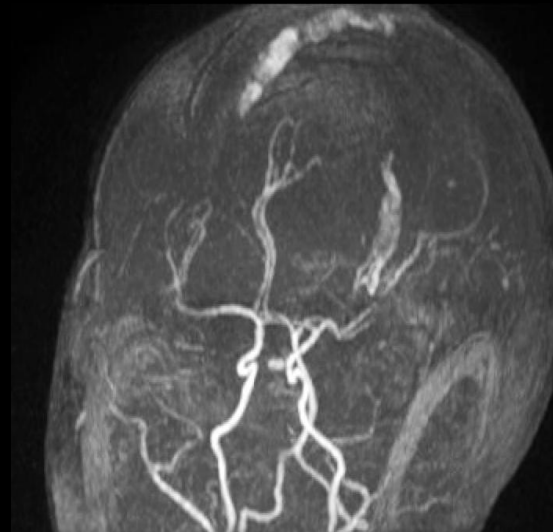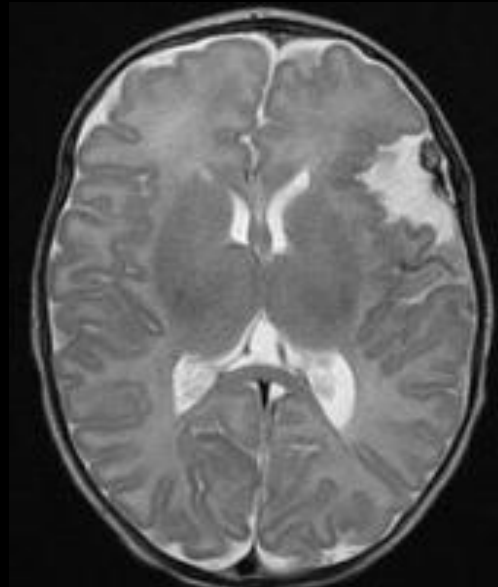
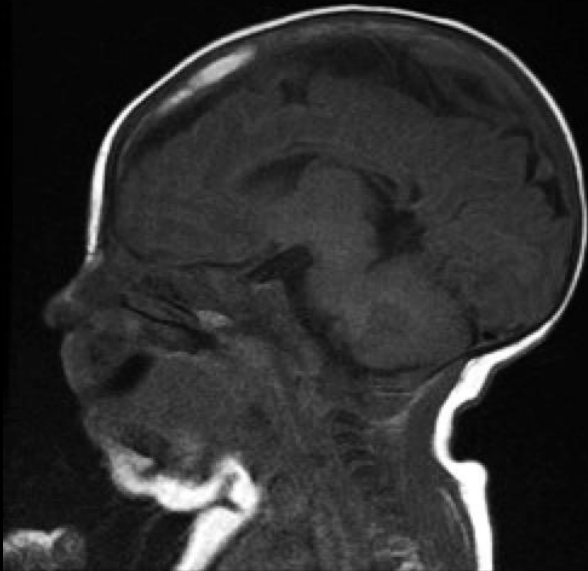
Naixement de nen masculí, pes 2.235g. Apgar 9-10.

Ingressa a neonats

NN



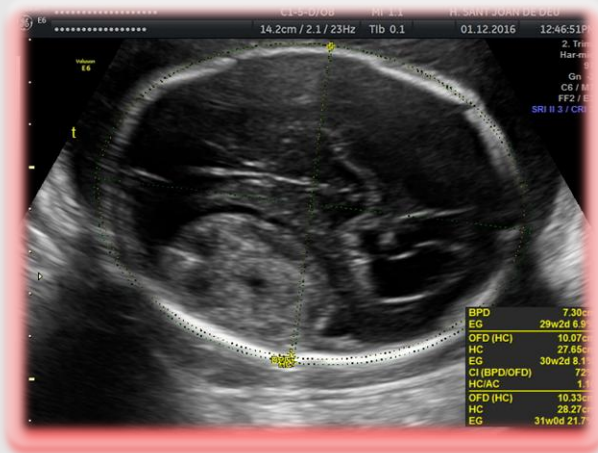5 setmanes



Trombosi de la part anterior del si sagital superior

Associació a hematoma epidural

Valorar l'evolució intraúter per establir el pronòstic



EQUIP MULTIDISCIPLINAR