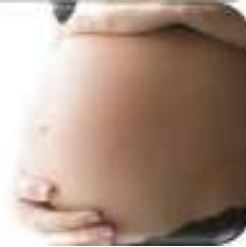

DOBLE ARC AÒRTIC

Maria Antònia Perelló Barceló
Resident 2n any Obstetrícia i Ginecologia
Hospital Universitari Son Espases
Illes Balears

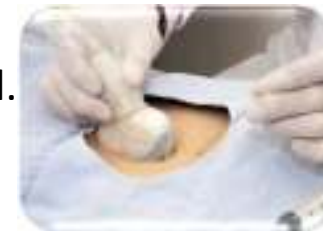39 anys
Formula obstètrica: 1.0.1.1 1CS
Epilèpsia en tractament amb Lamotrigina

33 sg per a valoració
per patologia tronc
aòrtic.



CARIOTIP: 46 xx normal.

22q11.2 negatiu

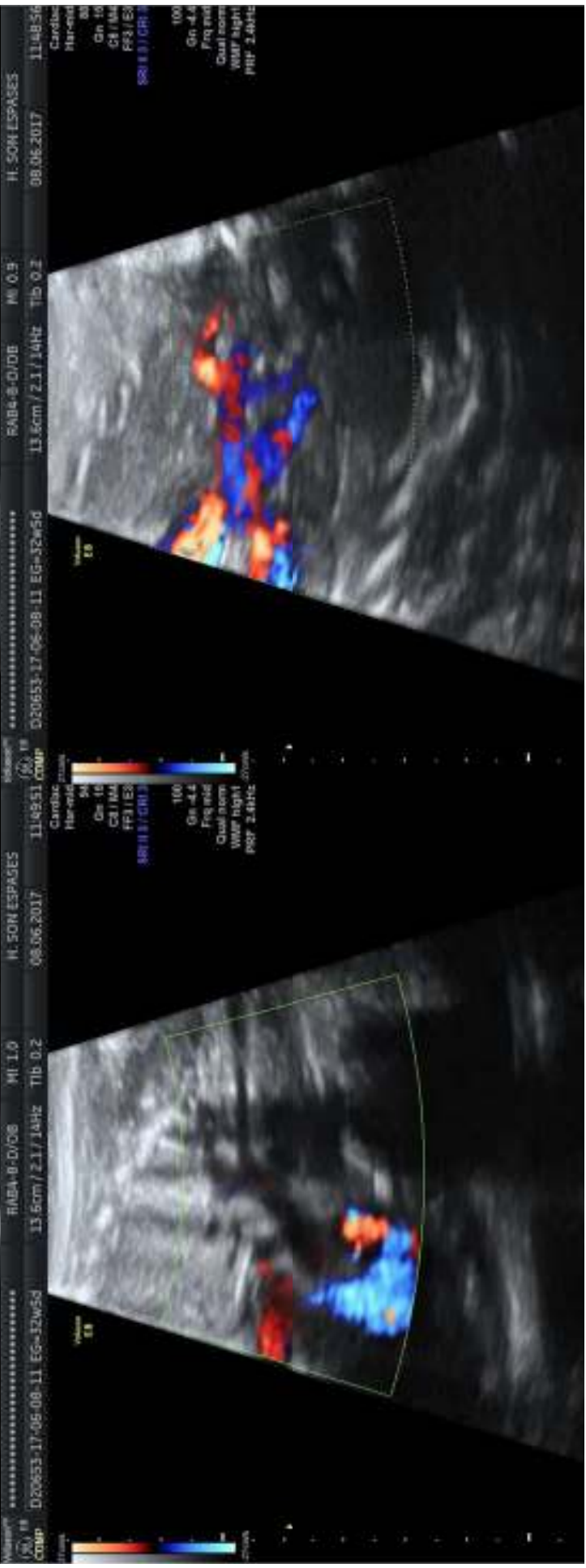
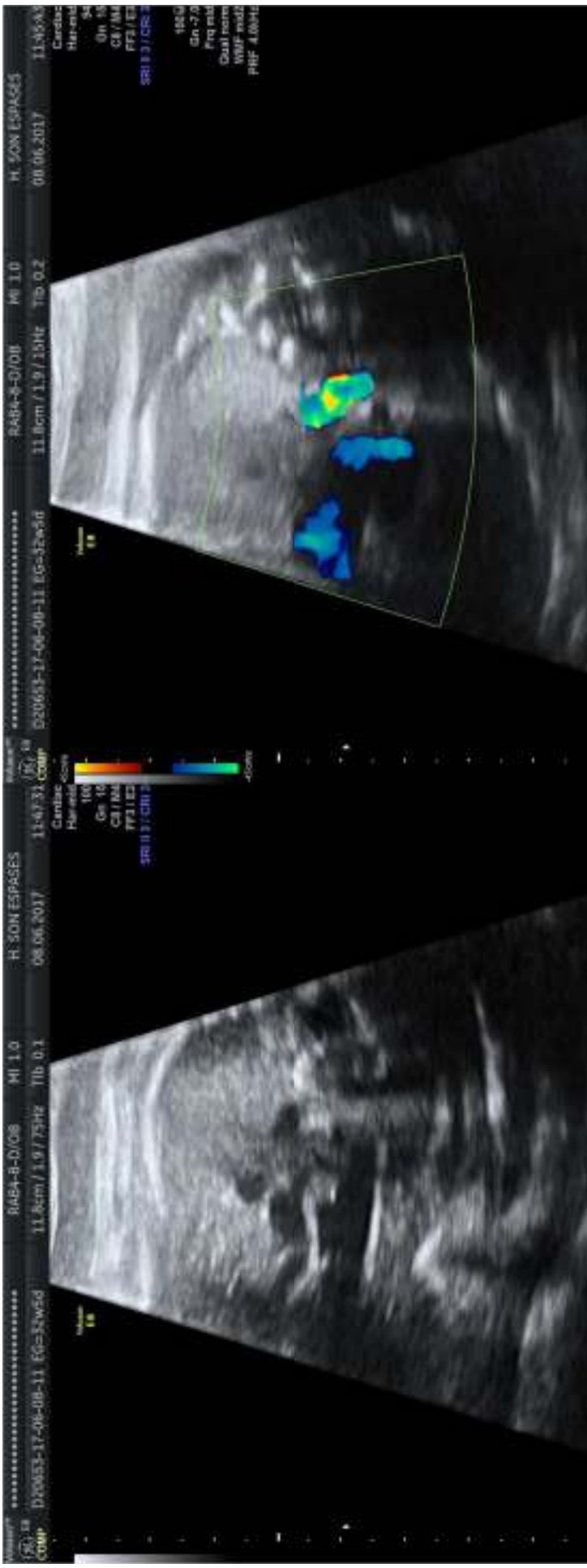


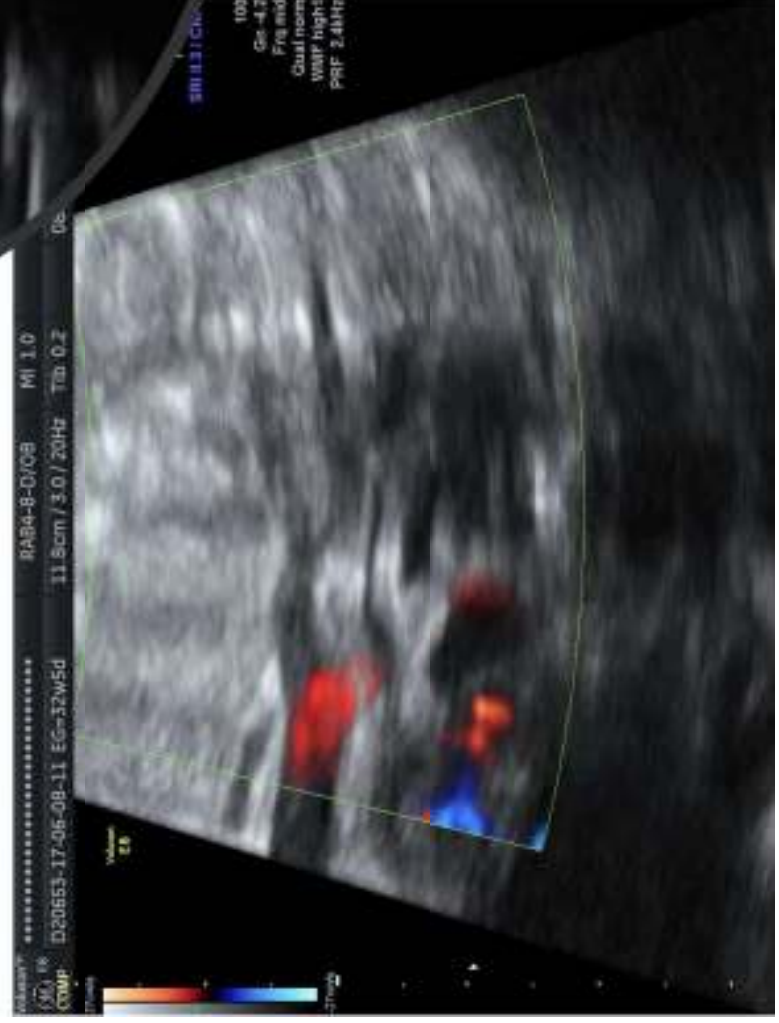
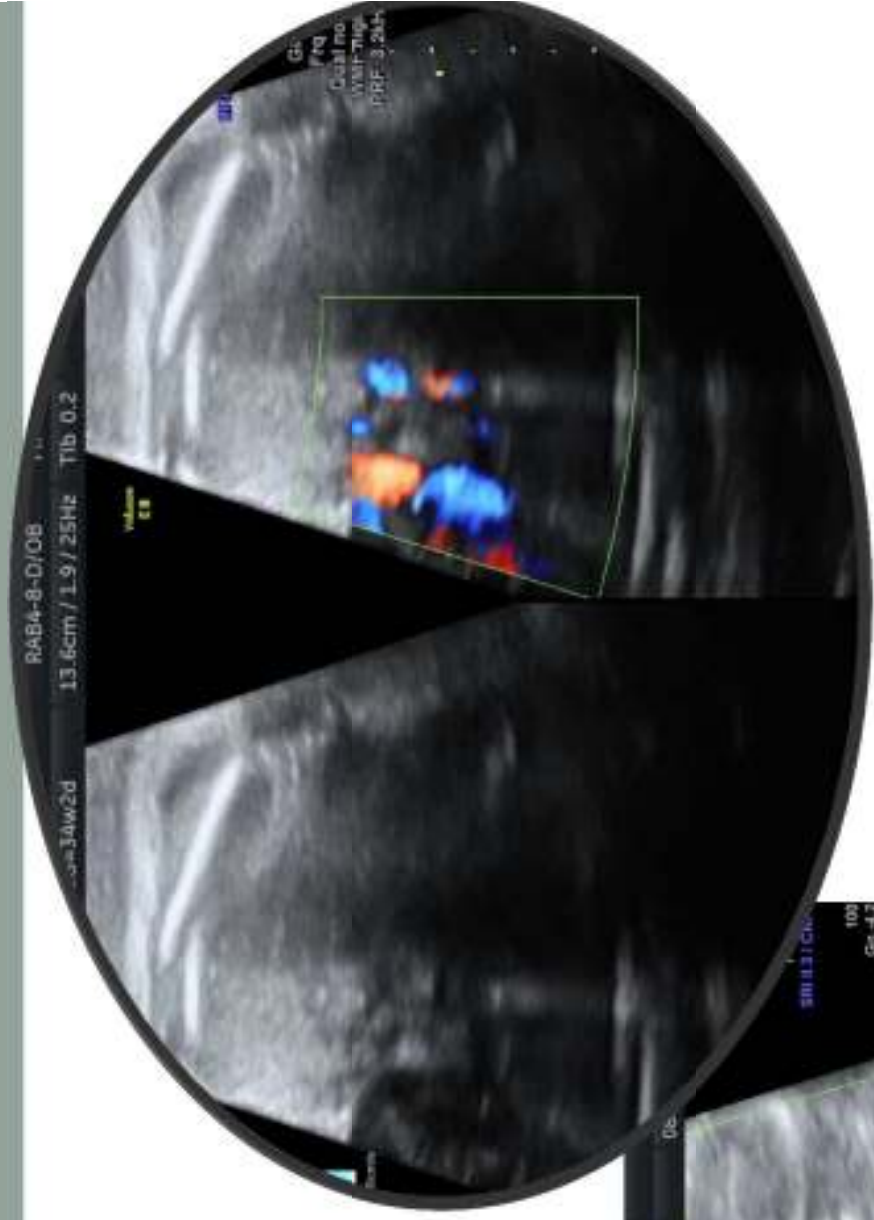
38+4 sg cesàrea

2600 g Apgar 9-10 pH AU: 7,32

RN sa, No UCIN/UCM







right

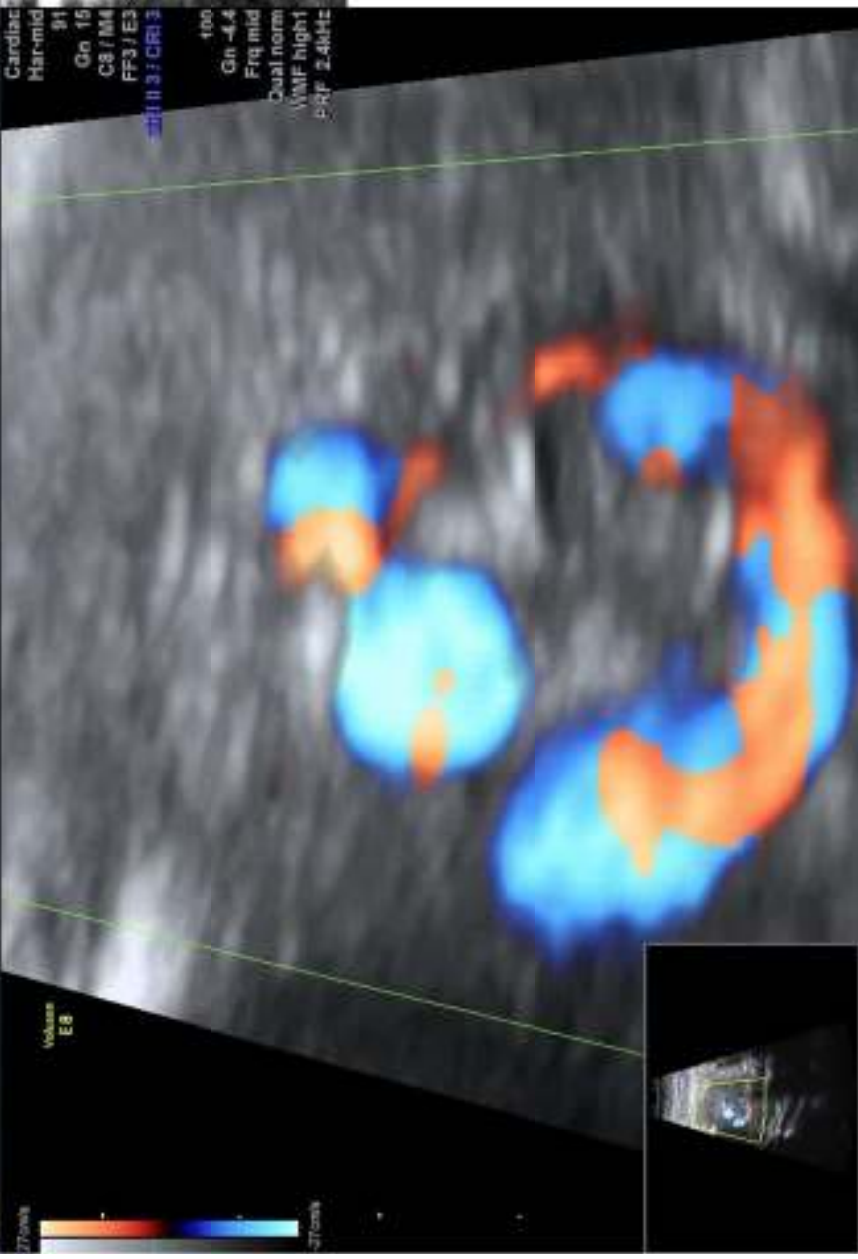
V A P
R T L

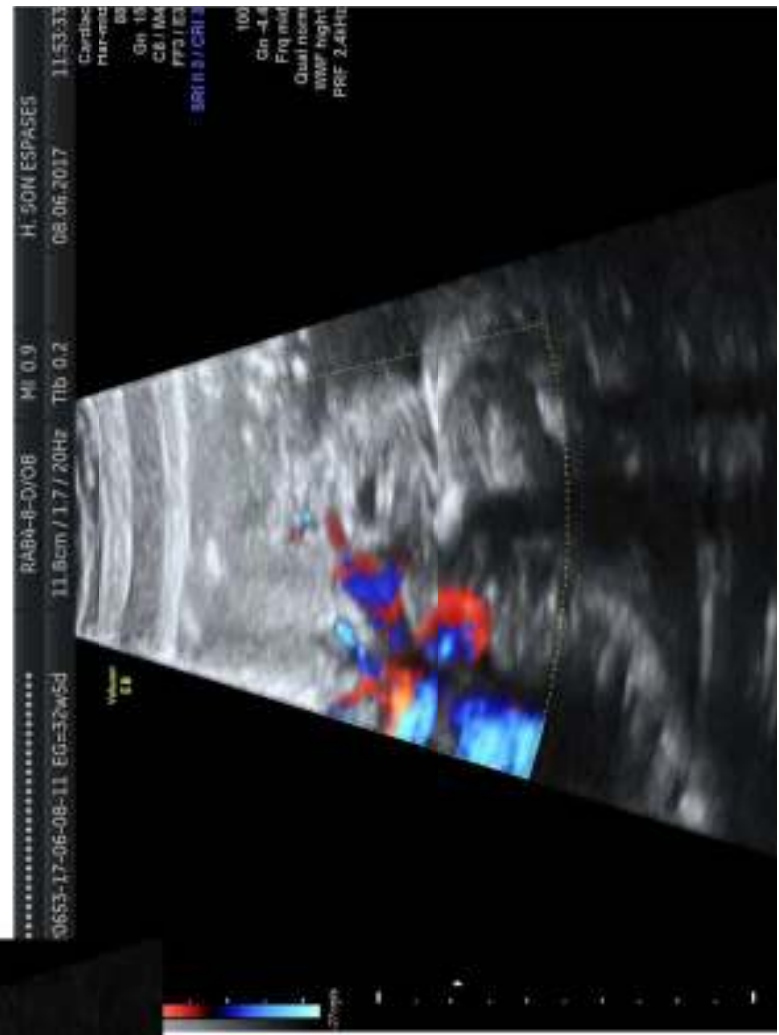
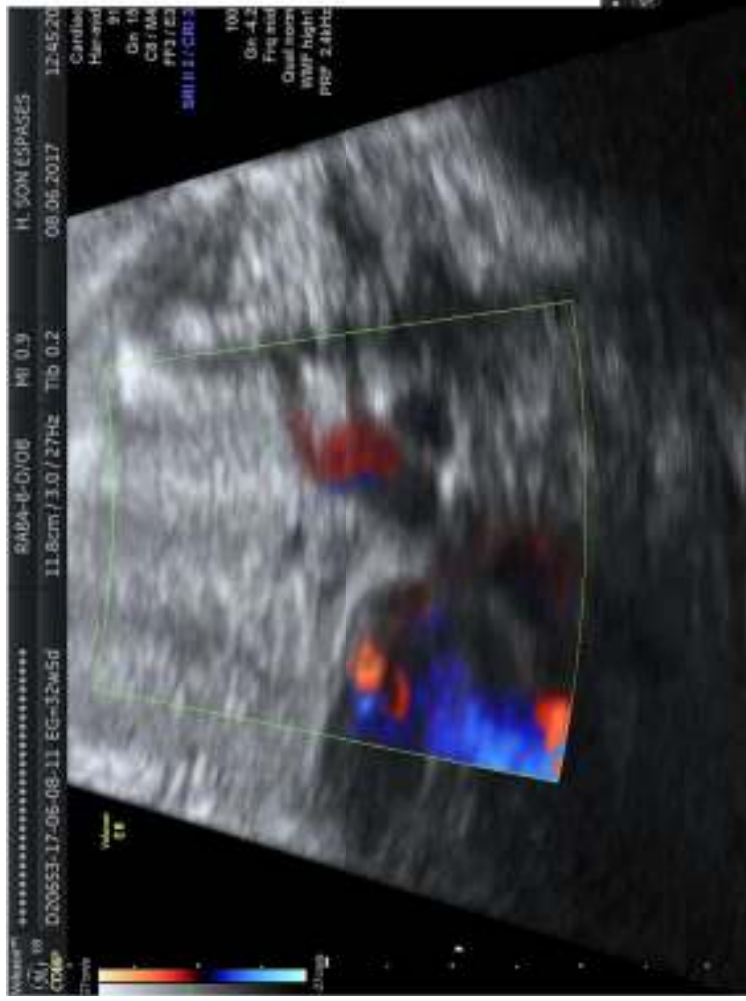left

duodens

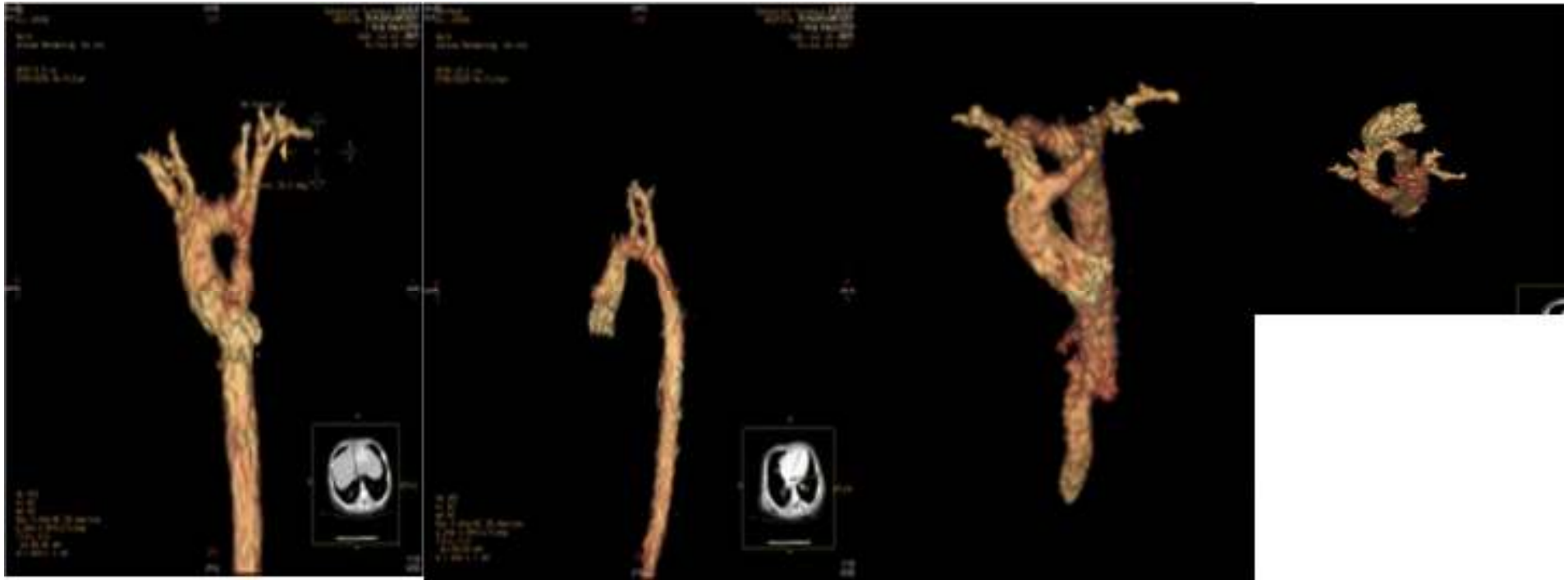spine

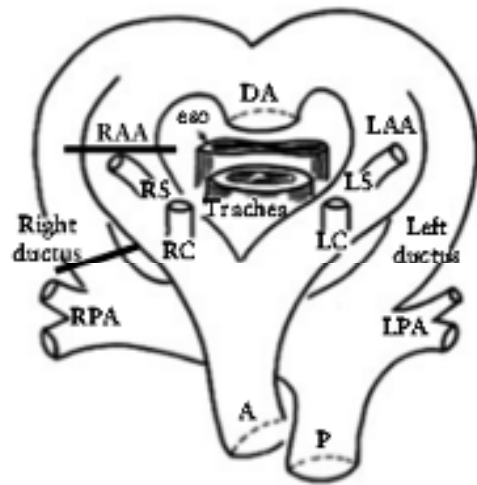
VolumeComp
 EF
 D20653-17-06-08-11 EG=32w5d
 RABA-8-D/OB MI 0.8
 H. SON ESPASES
 08.06.2017
 13.6cm / 1.7 / 26Hz Tib 0.2
 12:16:32
 Cardiac
 Har-mid
 91
 Gn 15
 C8 / M4
 FF3 / E3
 100
 Gn -4.4
 Frq mid
 Dual norm
 WMP high1
 PRF 2.4kHz



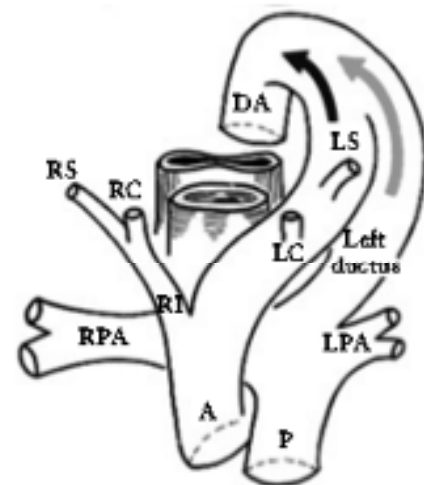


Angio-TAC

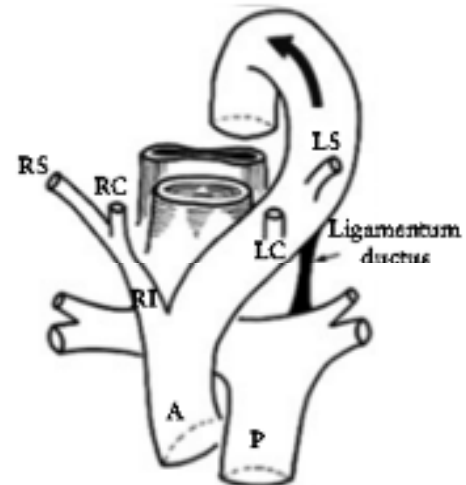




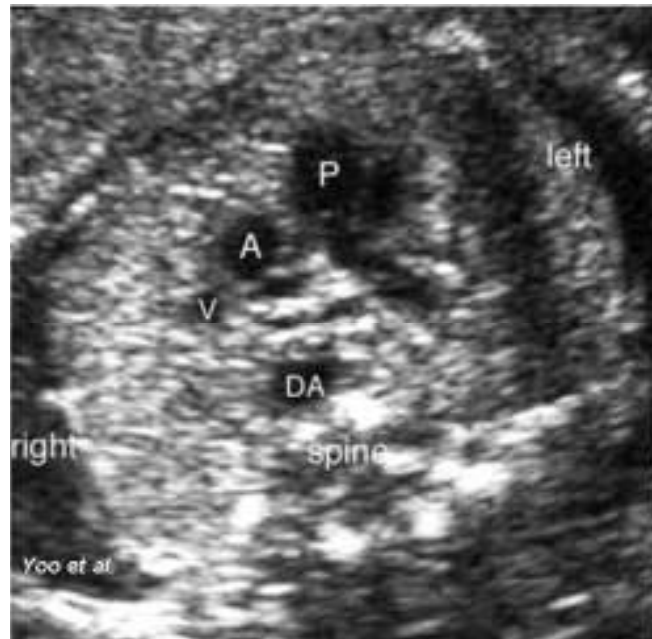
Hypothetical model



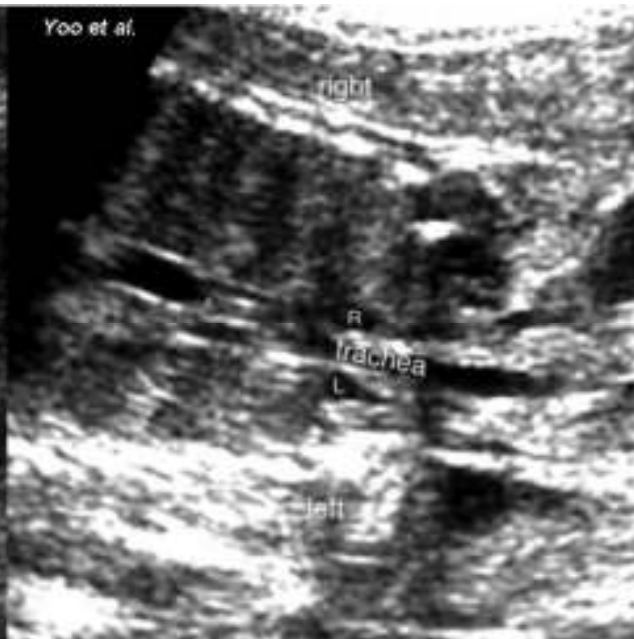Fetal circulation



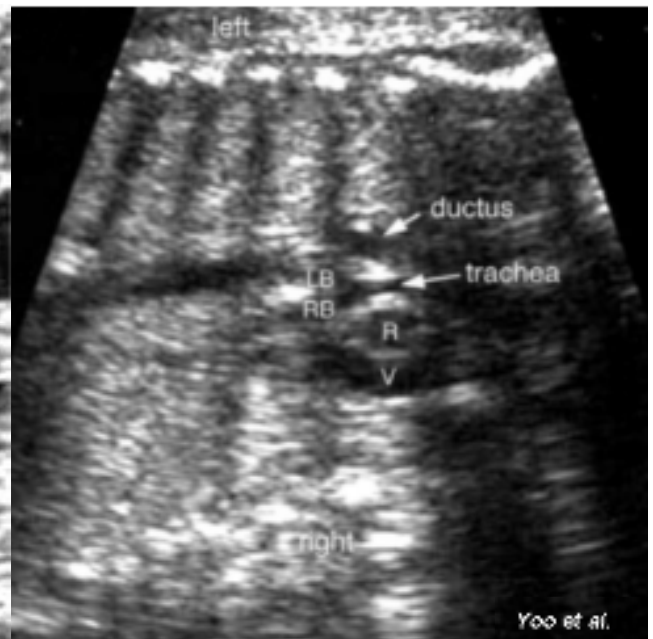Postnatal circulation *Yoo et al.*



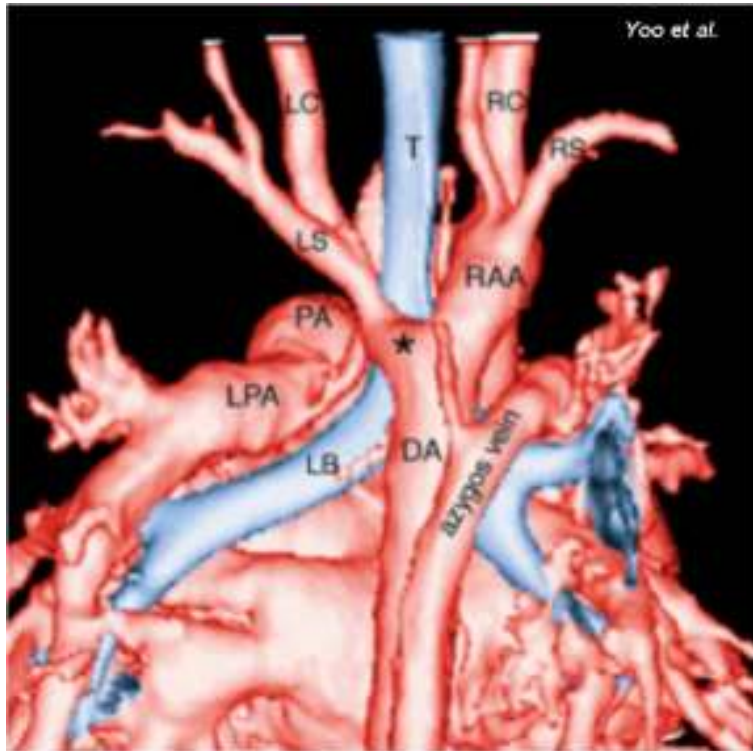
Yoo et al.



Yoo et al.

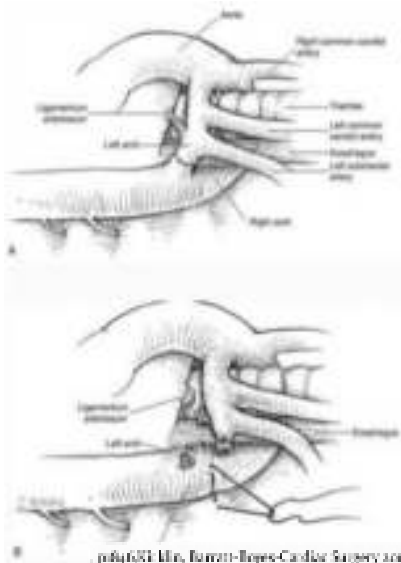


Yoo et al.



- Anomalies en la posició o en el patró de branques
- **Clínica:** Assintomàtic / Simptomàtic (estridor bifàsic, dificultat respiratòria/deglució)
- **Pronòstic**

- **Incidència anells vasculars : 0.086% (global)²**
- **Doble arc aòrtic: 3,7% anells vasculars²**
- **20% Associació a cardiopaties congènites**



**Tractament:
secció
quirúrgica arc
aòrtic menor +
desplaçament
lateroposterior**

¹S.-J. Yoo, J.-Y. Min, Y.-H. Lee, K. Roman, E. Jaeggi, J. Smallhorn Fetal sonographic diagnosis of aortic arch anomalies. In: *Ultrasounds in Obstetrics and Gynecology*. Obstetrics and Gynecology. 2003

² Shengli Li, Guoyang Luo, Errol R. Norwitz, Chenhong Wang, Shuyuan Ouyang, Yuan Yao, Congying Chen, Huaxuan Wen, Xiulan Chen, Jingru Bi. Prenatal diagnosis of congenital vascular rings and slings: sonographic features and perinatal outcome in 81 consecutive cases. *Prenatal Diagn.* 2011 Apr;31(4):334-46. doi: 10.1002/pd.2678. Epub 2011 Jan 30.