

# Translucència intracranial

## Cal incorporar-la en la rutina del 1er trimestre?



Albert Guarque,  
Montserrat Inglès, Montserrat Monclús, Begoña Muñoz, Pere Cavallé

## Pacient

30 anys

NAMC, no IQ ni altres AP d'interès

TPAL 0.0.0.0

Embaràs de risc baix

A Positiu, CI negatiu.

Hemograma normal.

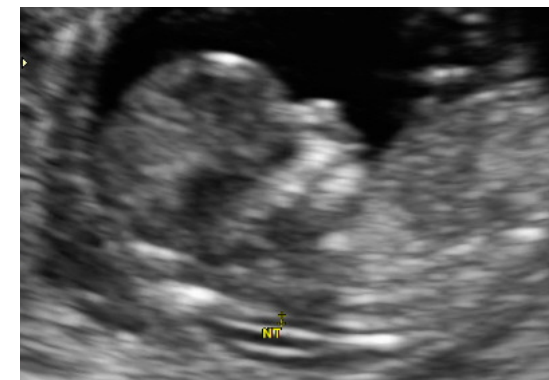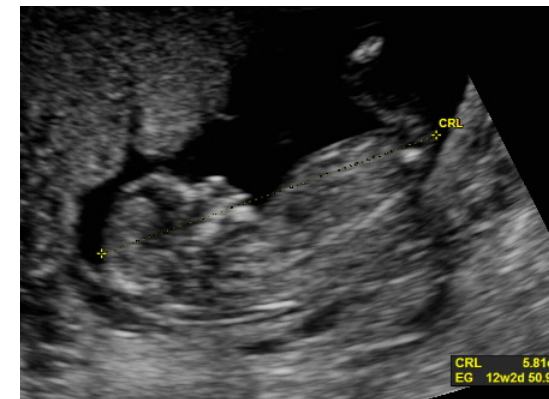
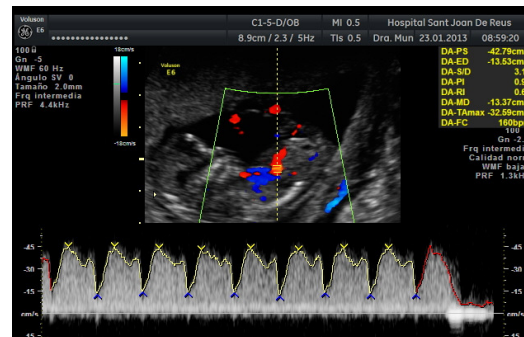
Rubeola immune.

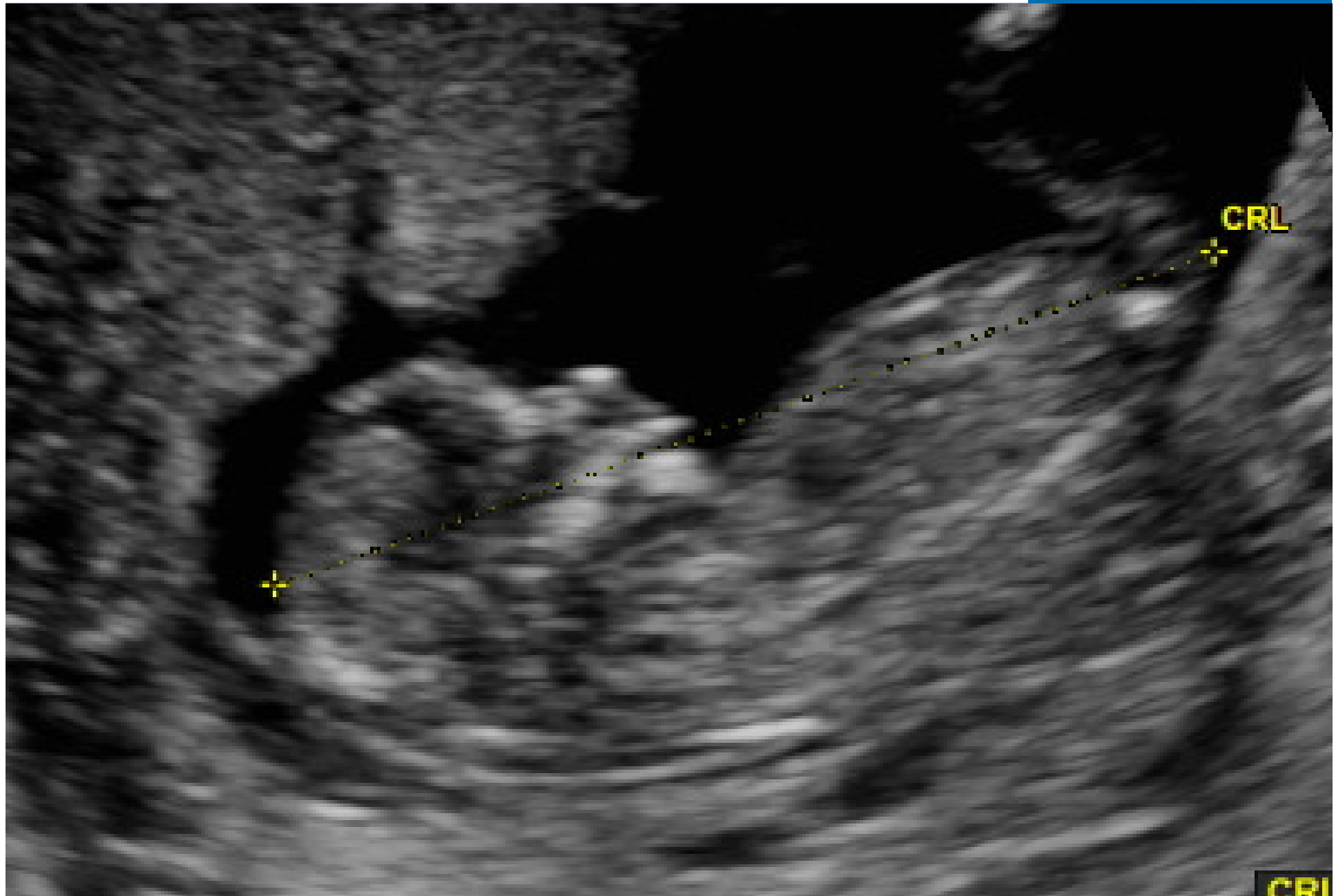
Toxoplasmosi no immune.

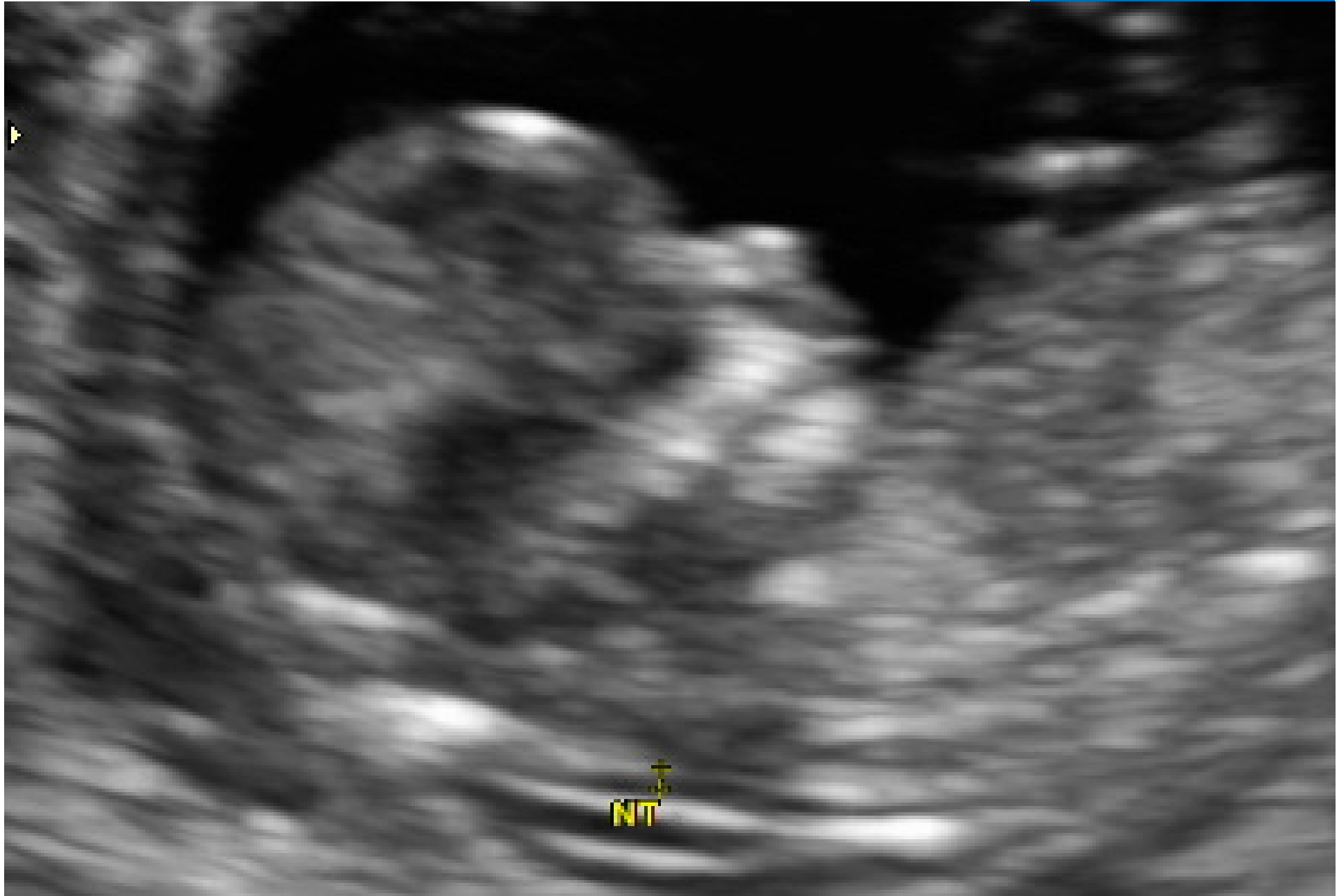Sífilis negativa.

HIV negatiu.

Screening analític i ecogràfic per  
aneuploidies en setmana 12: Baix  
Risc









EG=15s1d

RAB 4-8L/OB

10.1cm / 25Hz

MI 1.2

TIs 0.1

H. U. SANT JOAN DE REUS

13.02.2013

09:45:27 AM

1. Trim.

Har-Alto

Pot 100 %

Gn 11

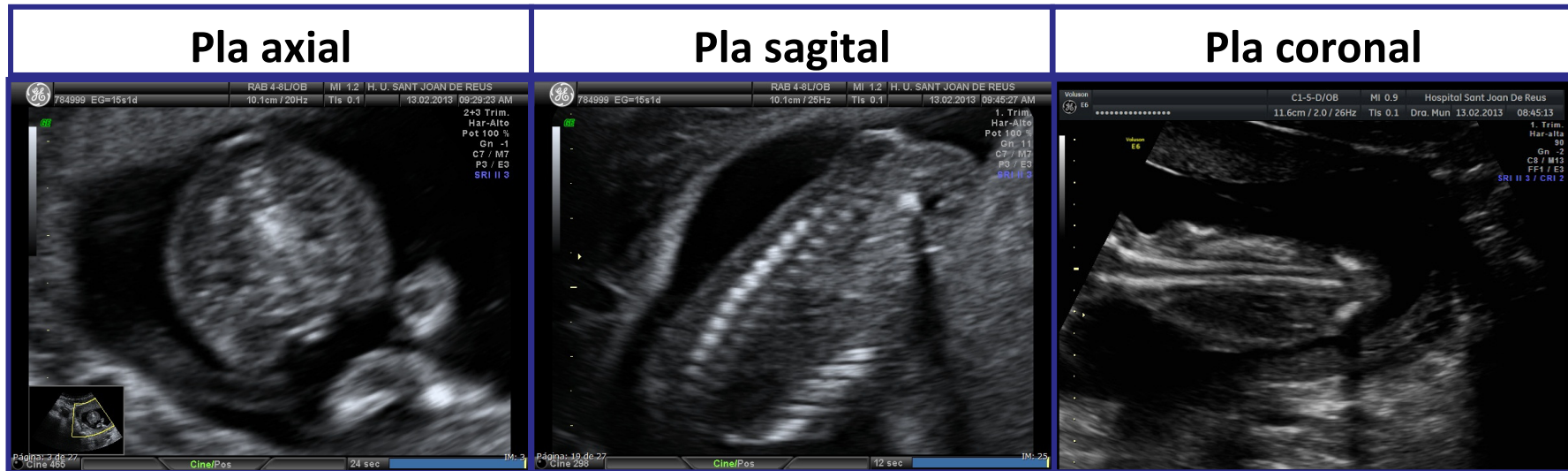C7 / M7

P3 / E3

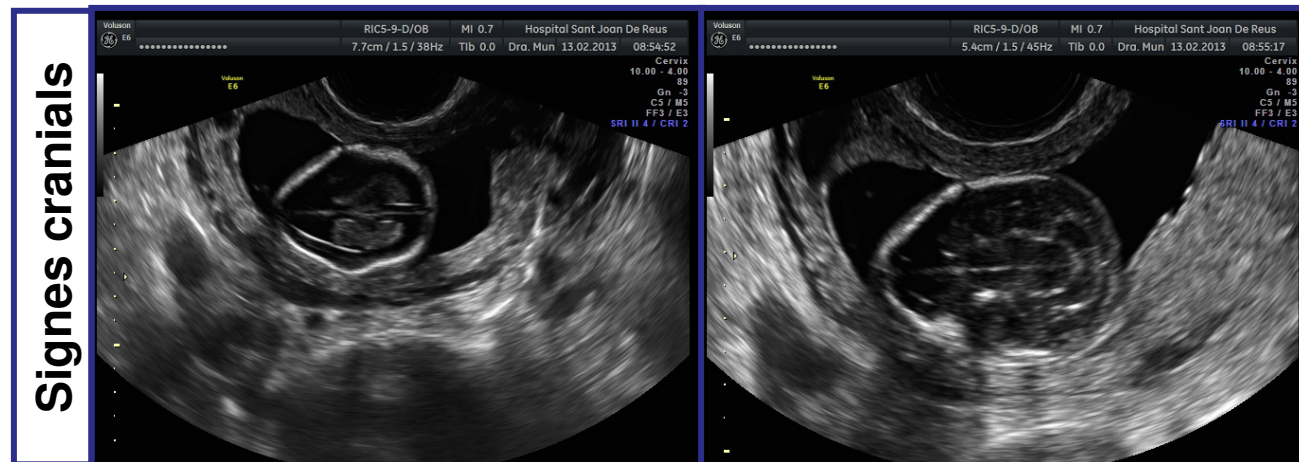
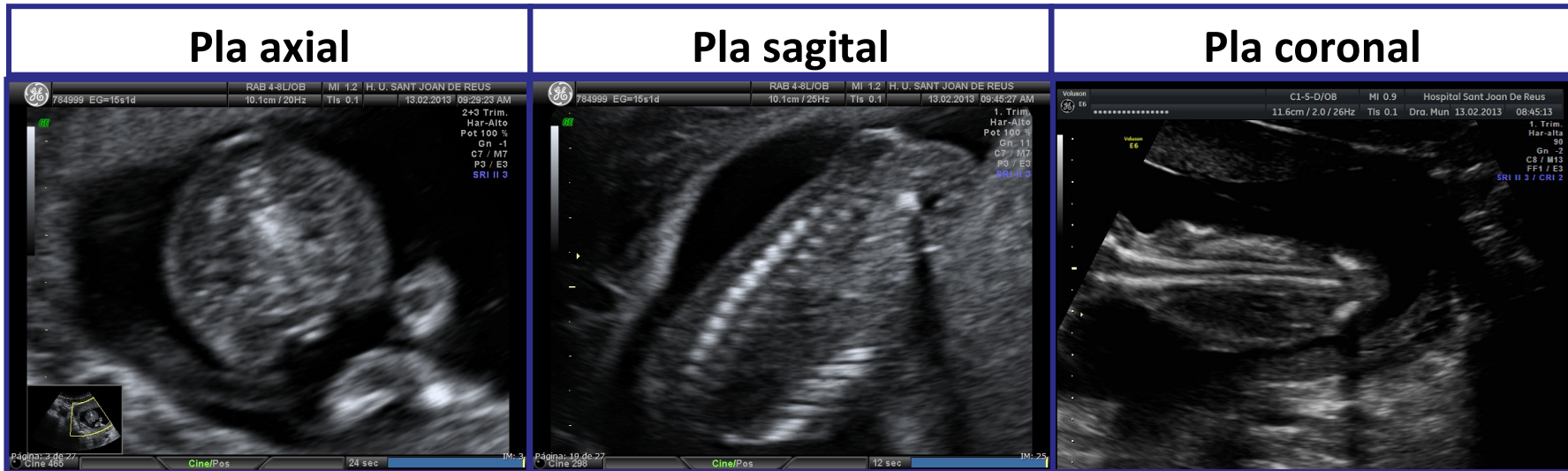SRI II 3

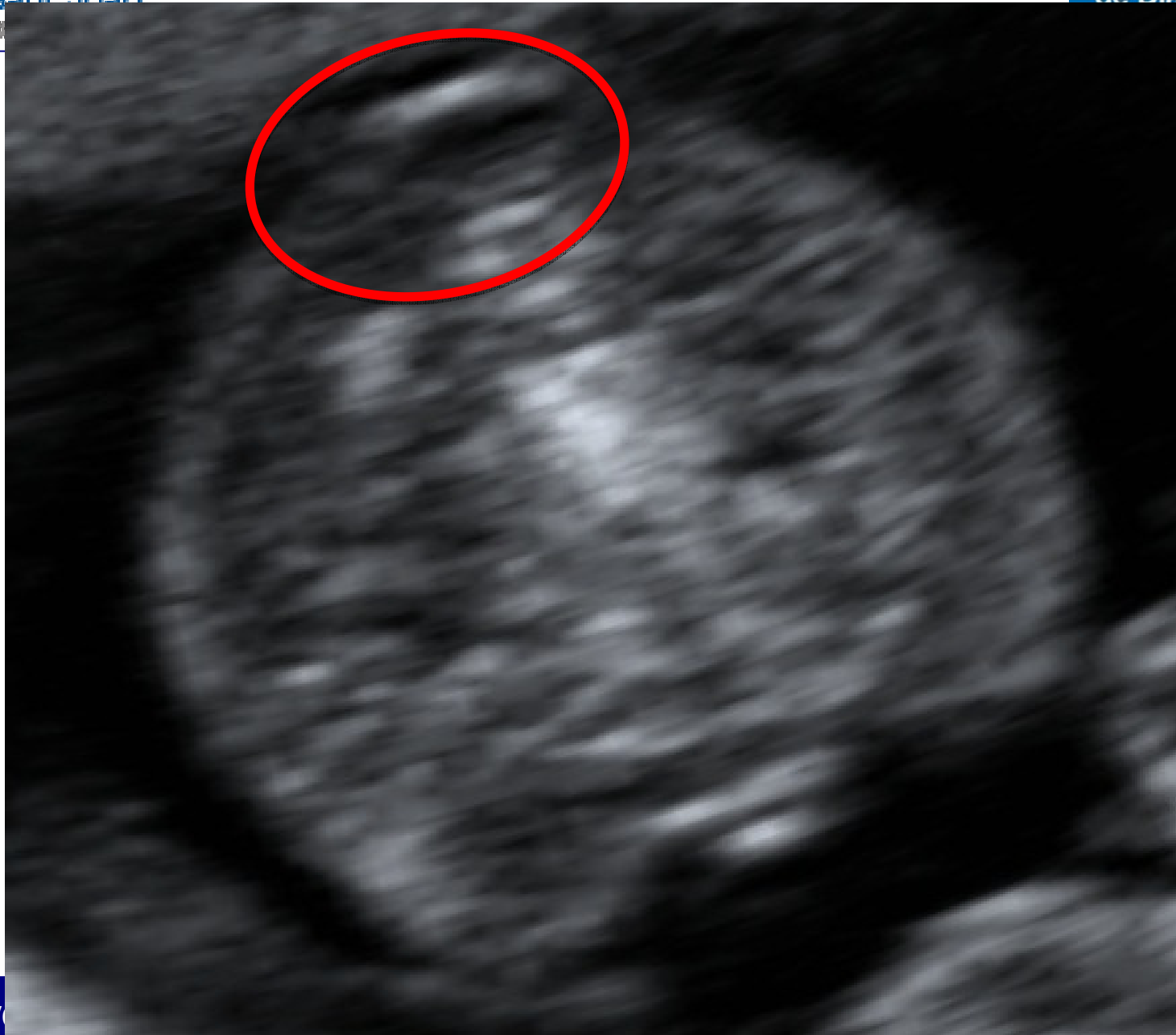

GE

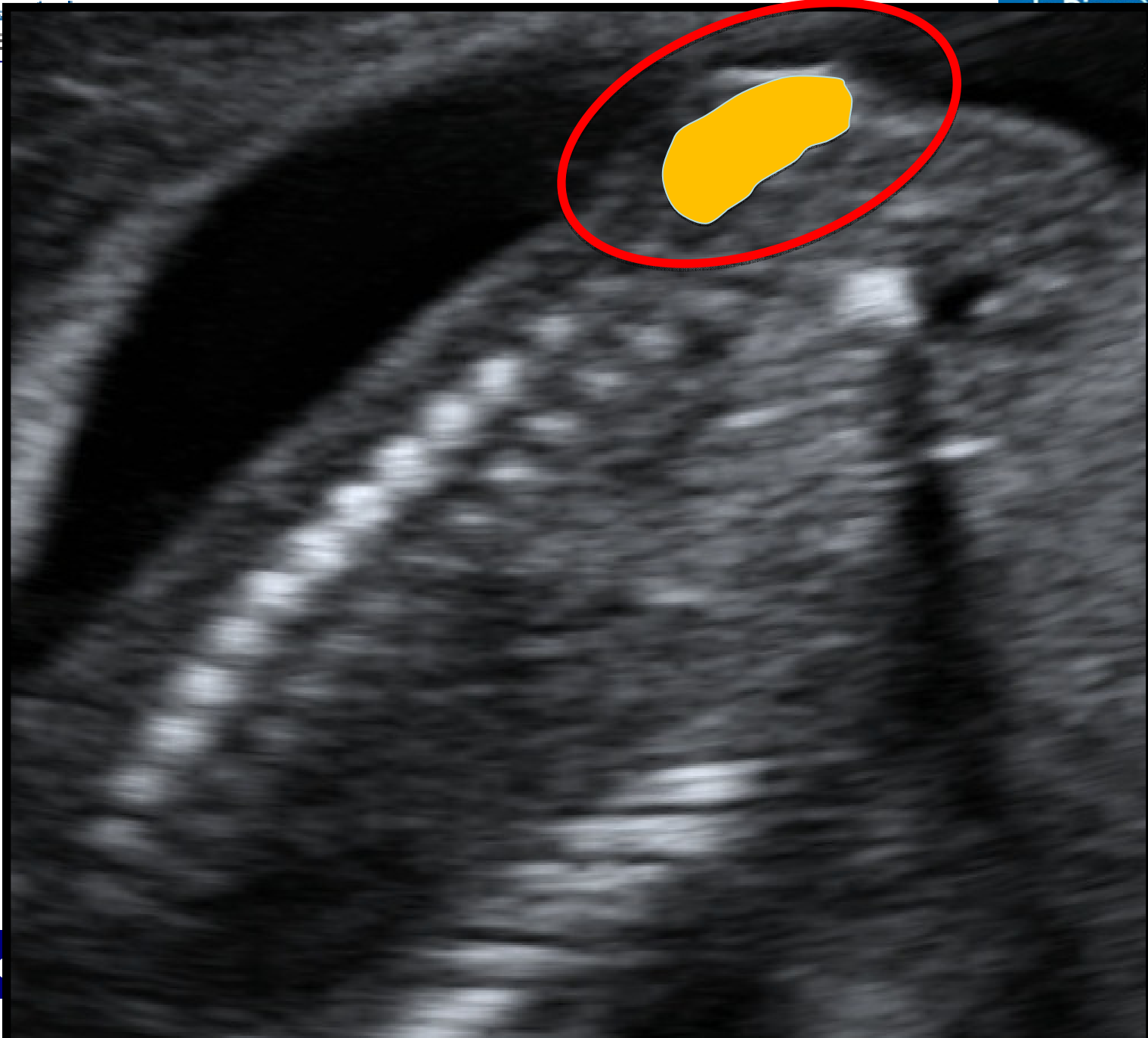

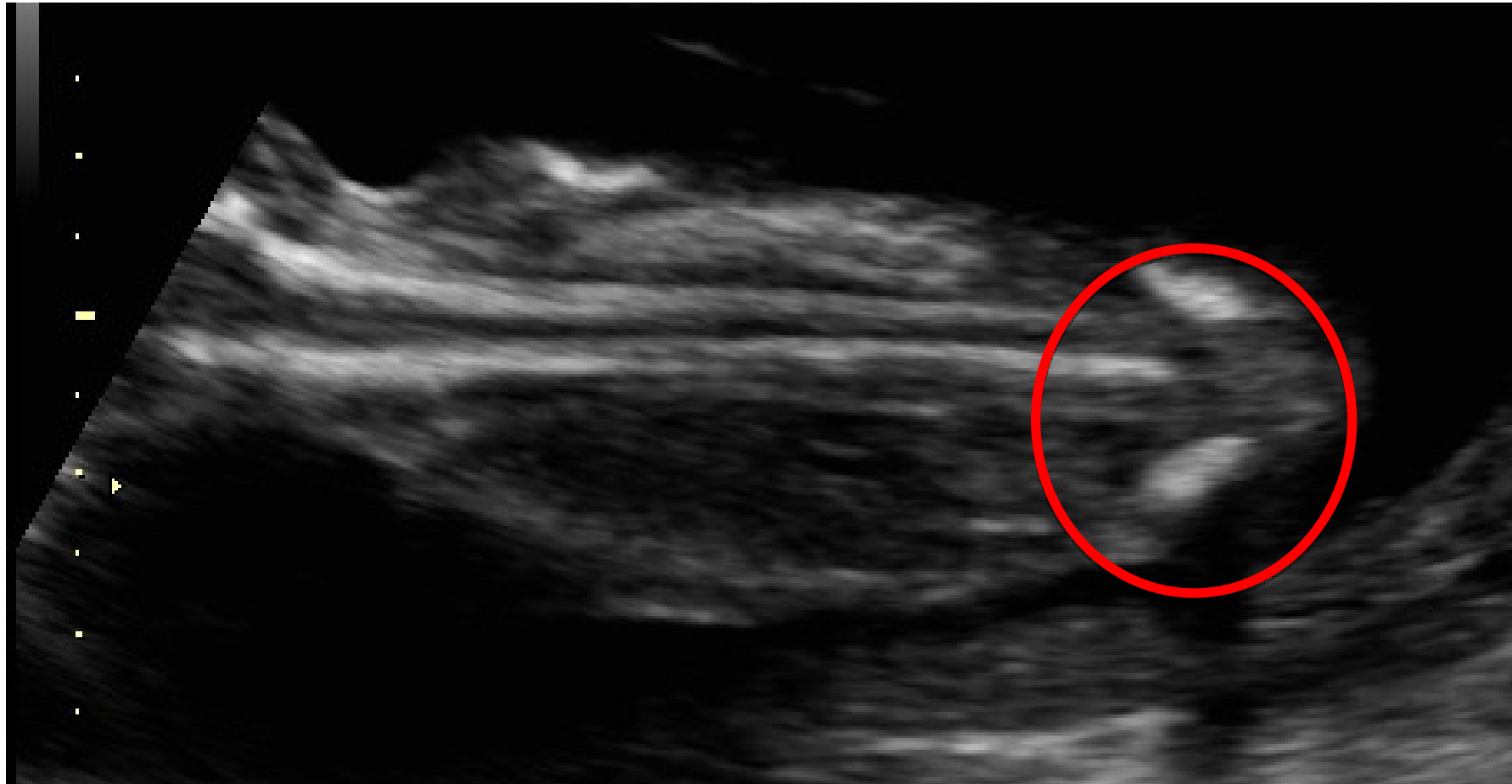


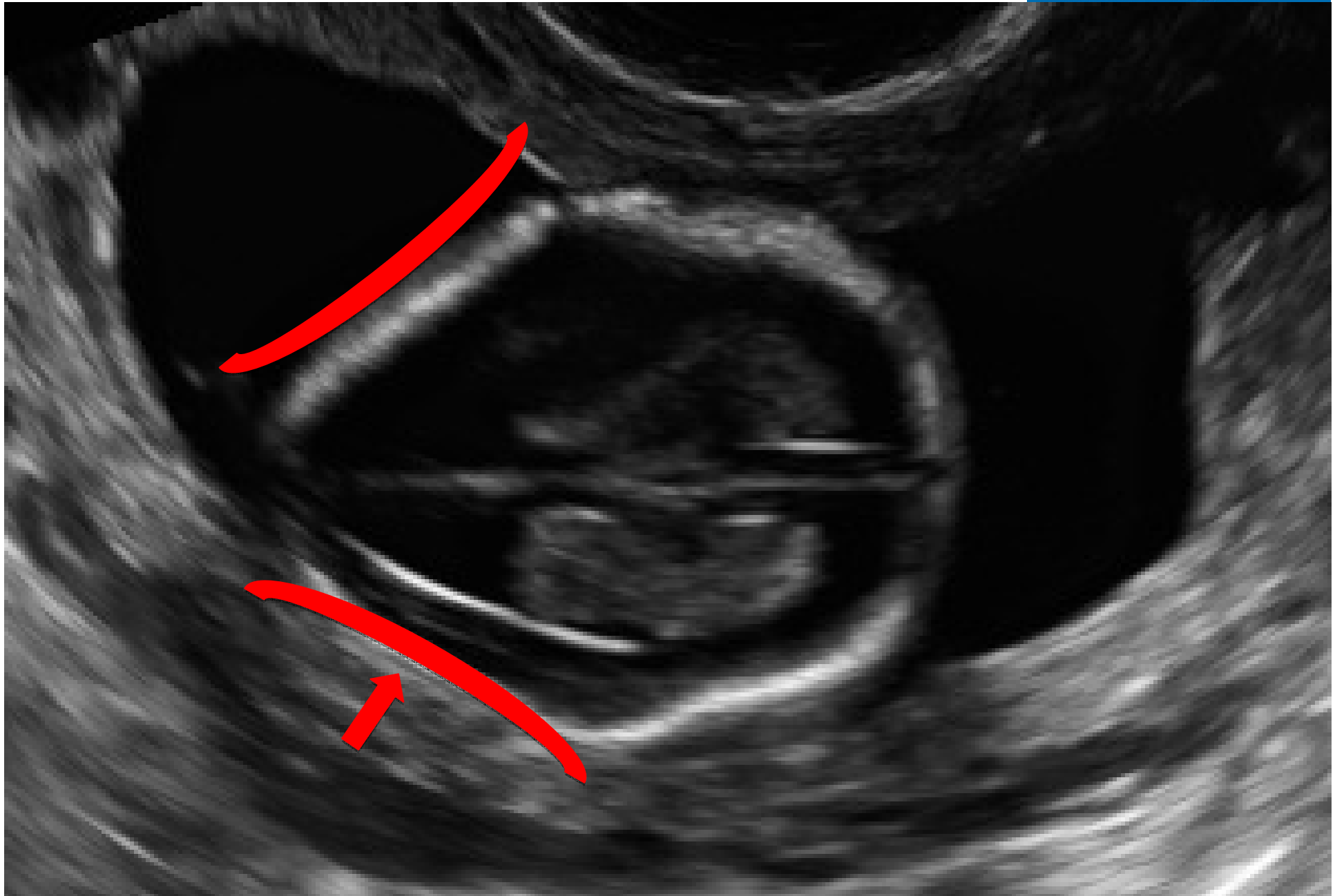


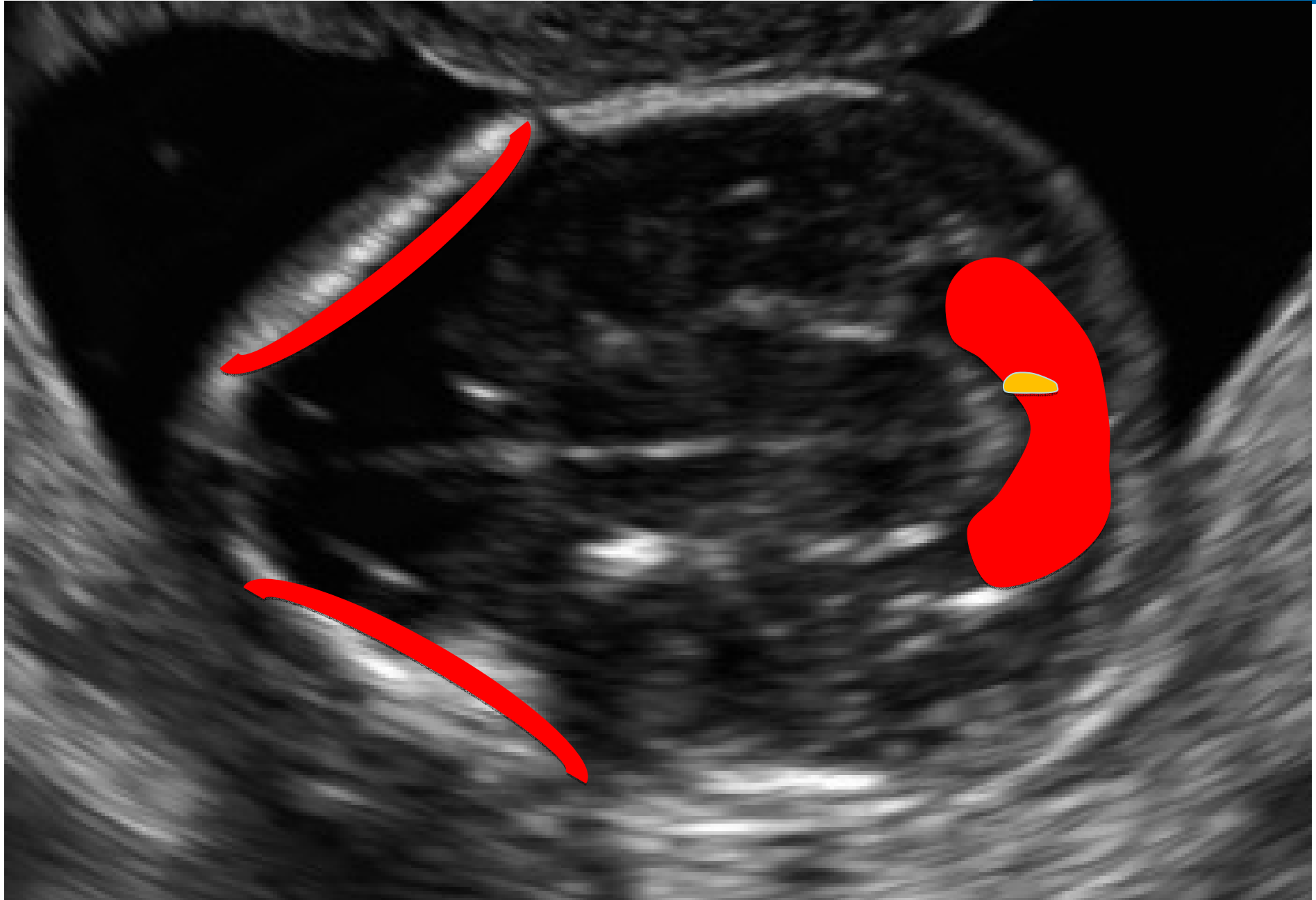



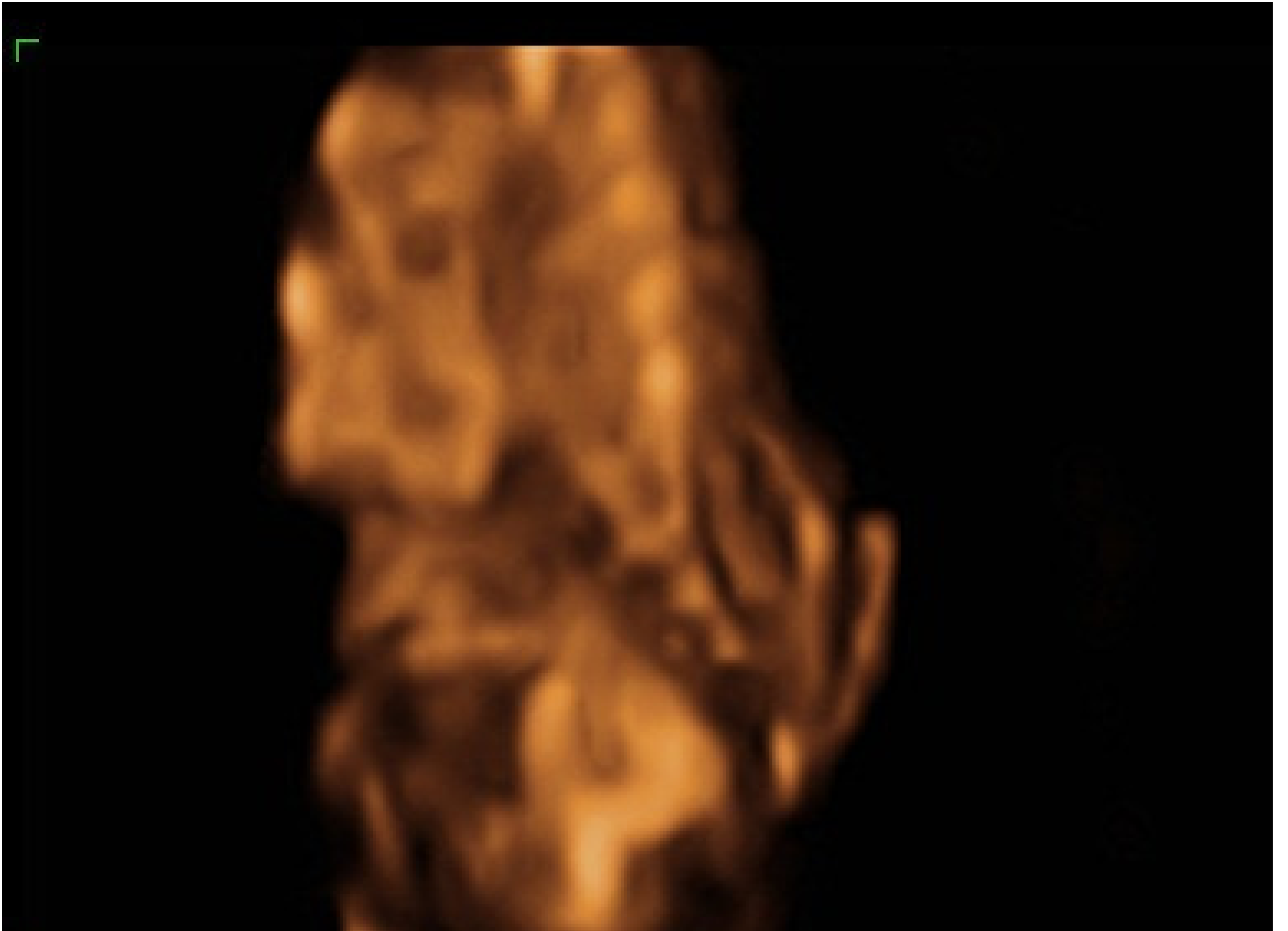


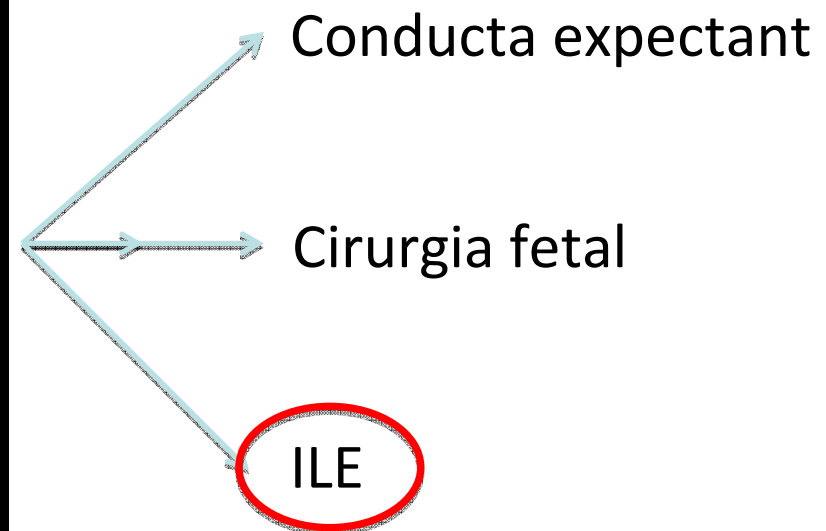


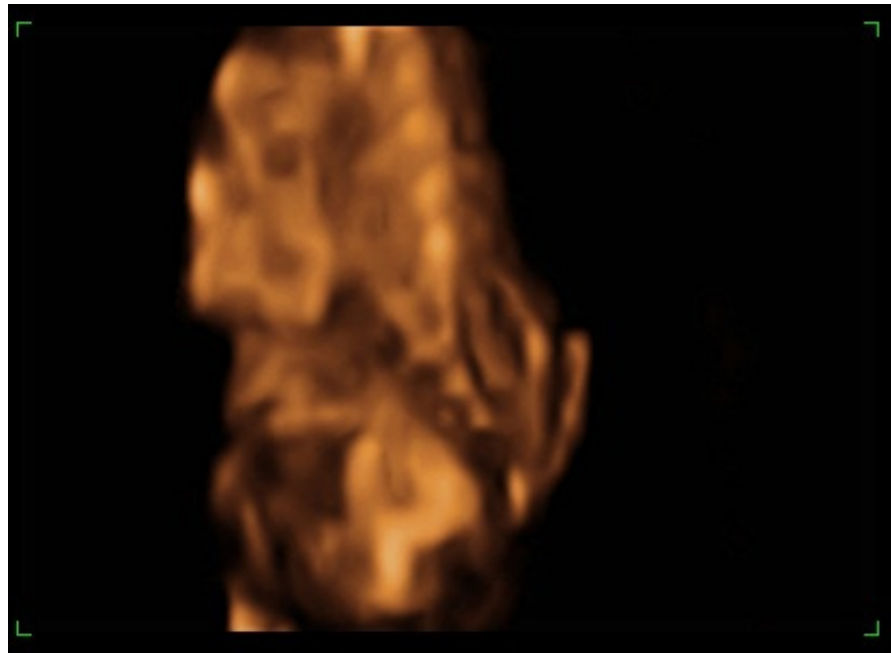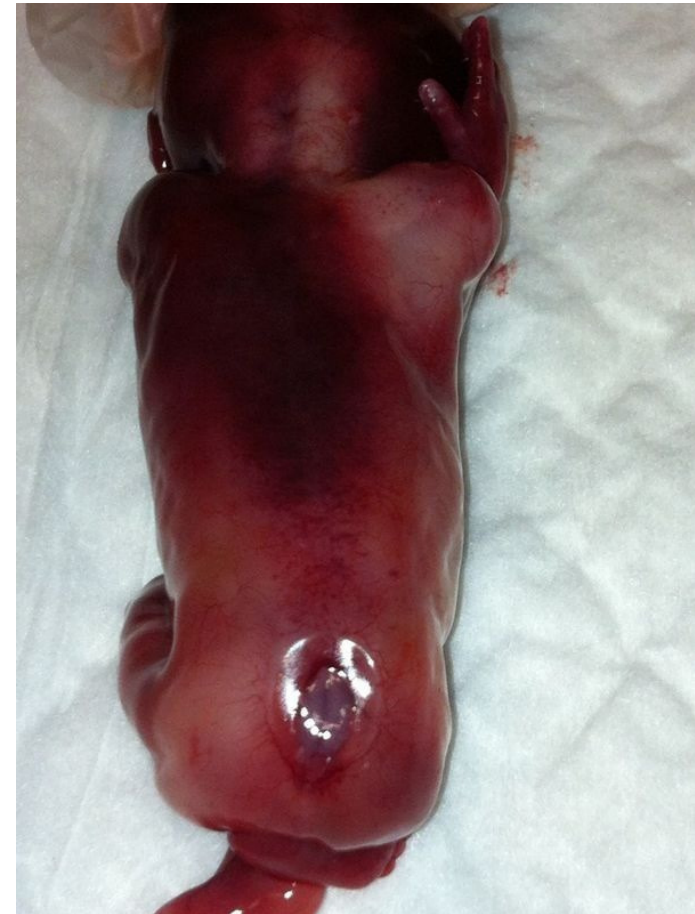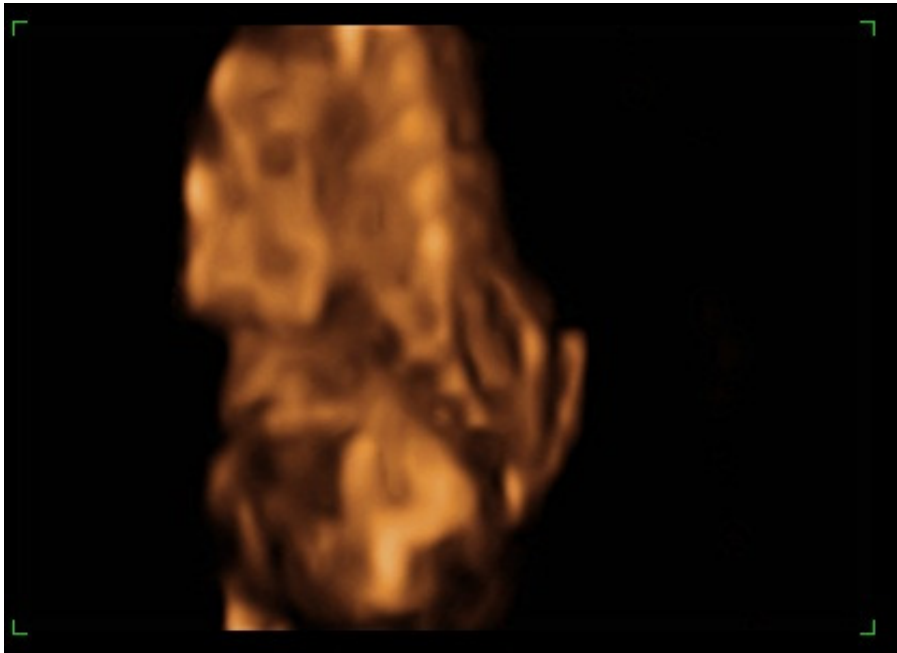


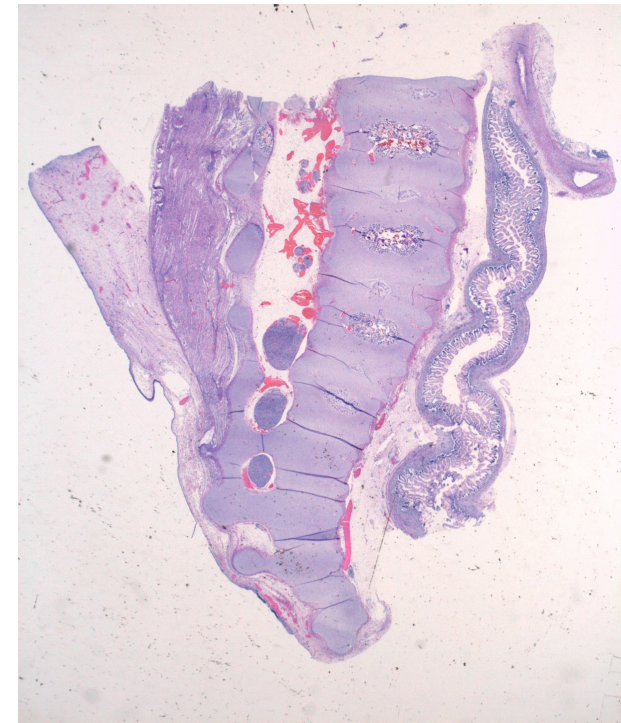
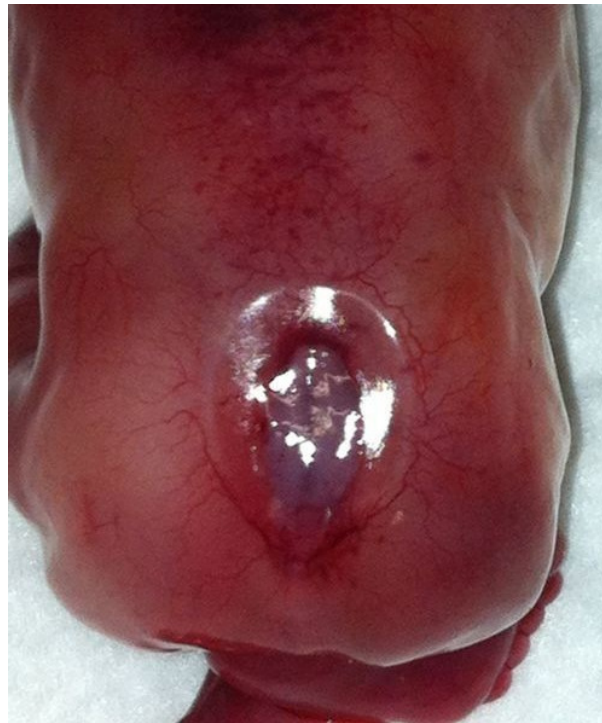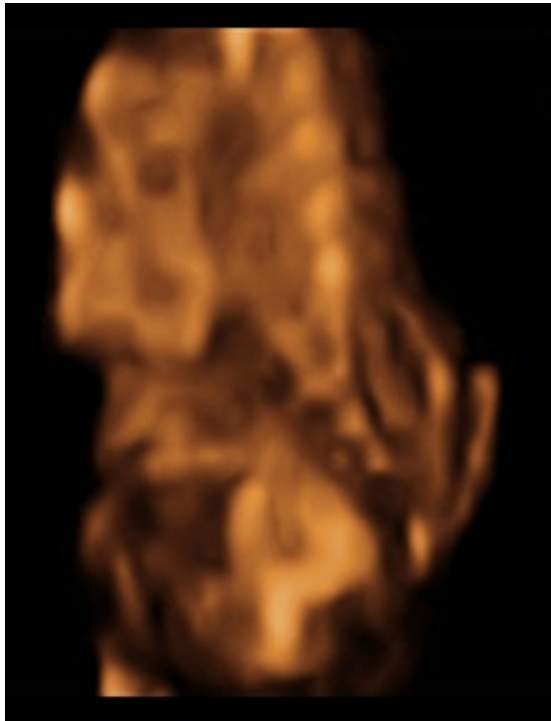






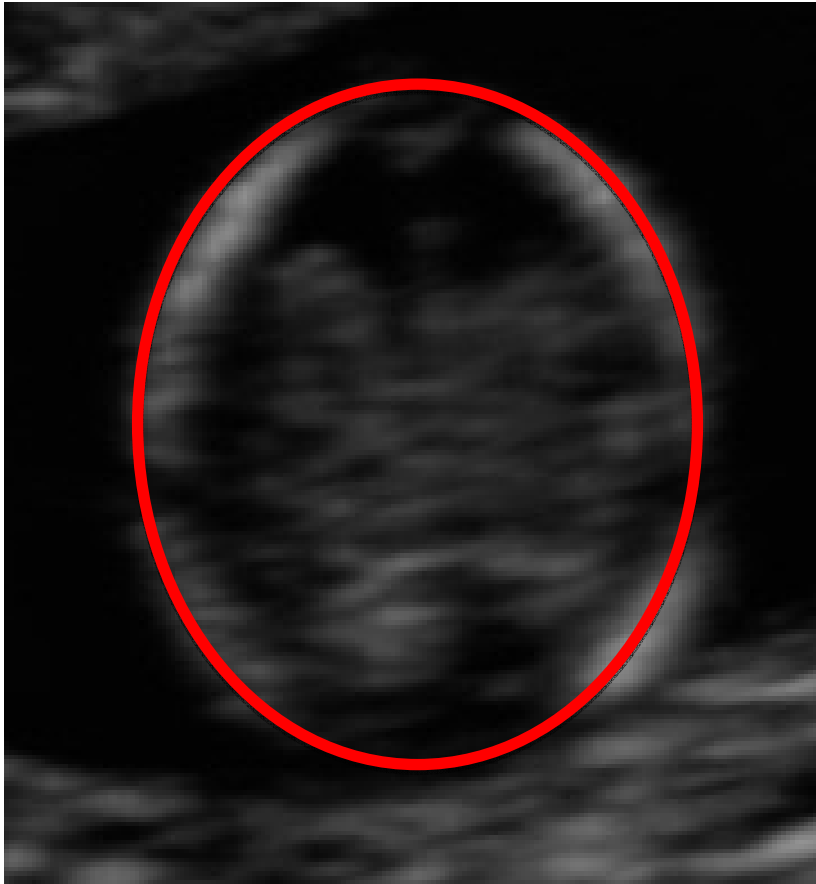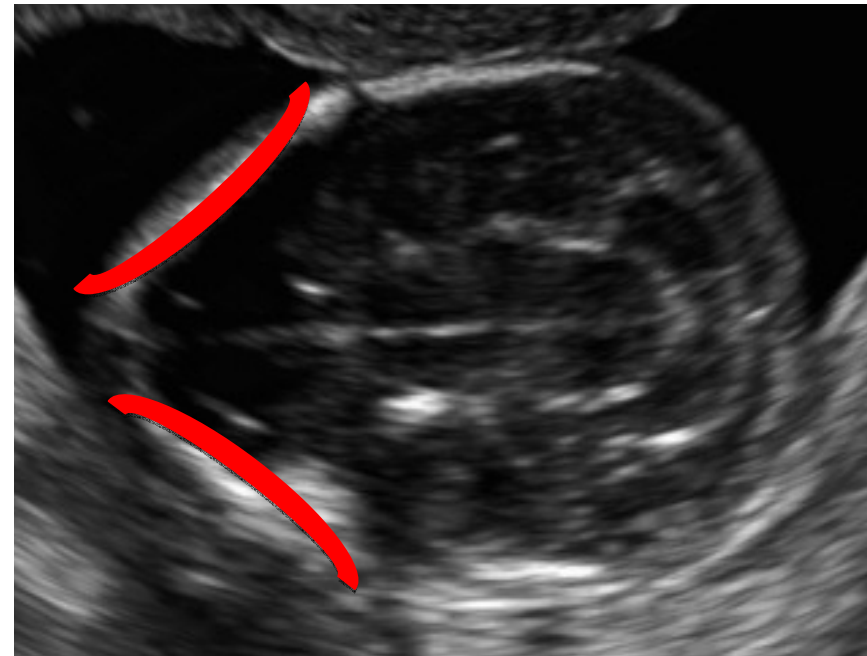




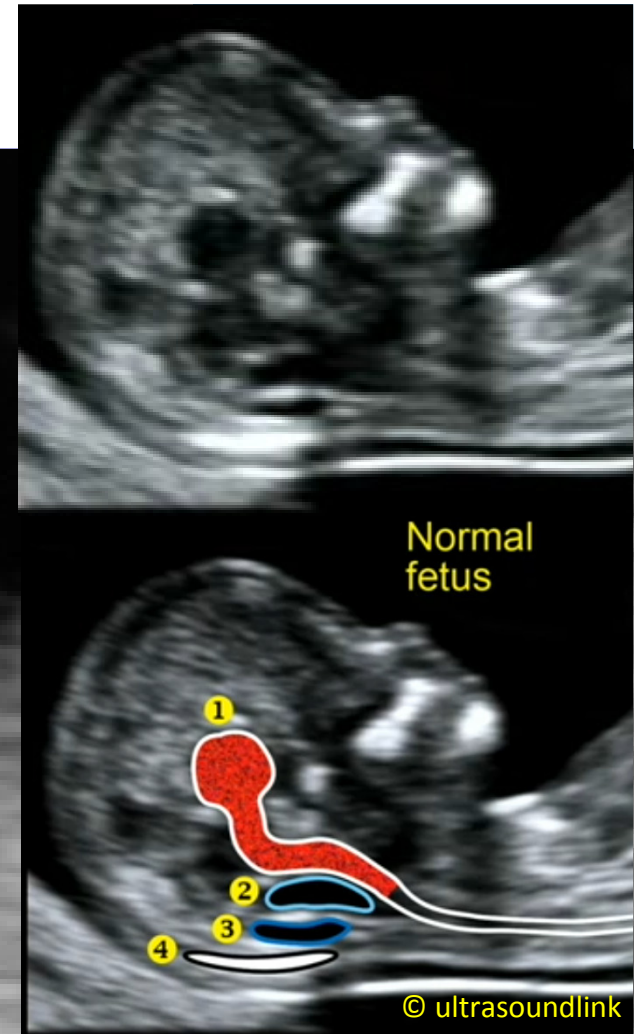
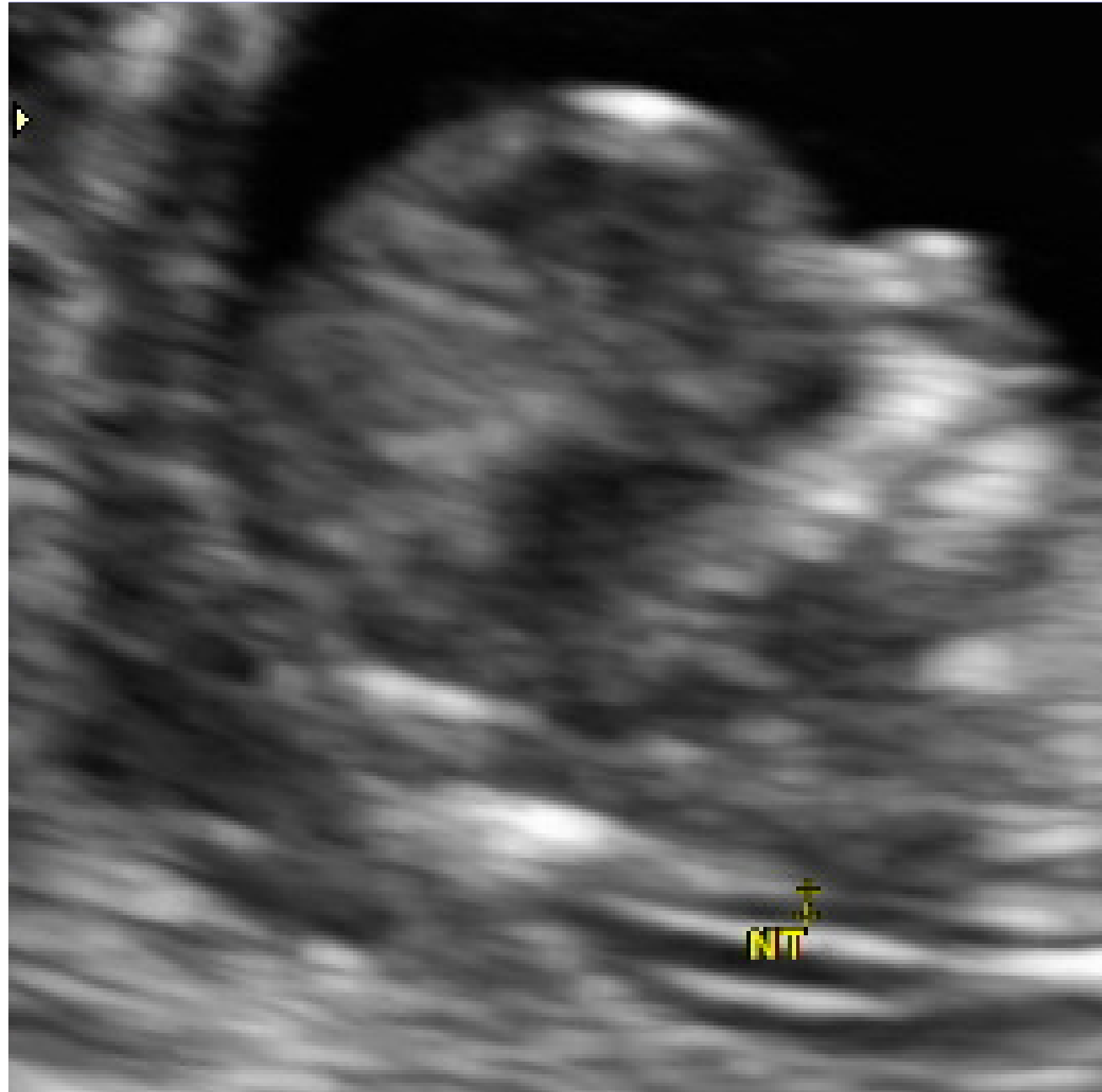




**12+2 SG**

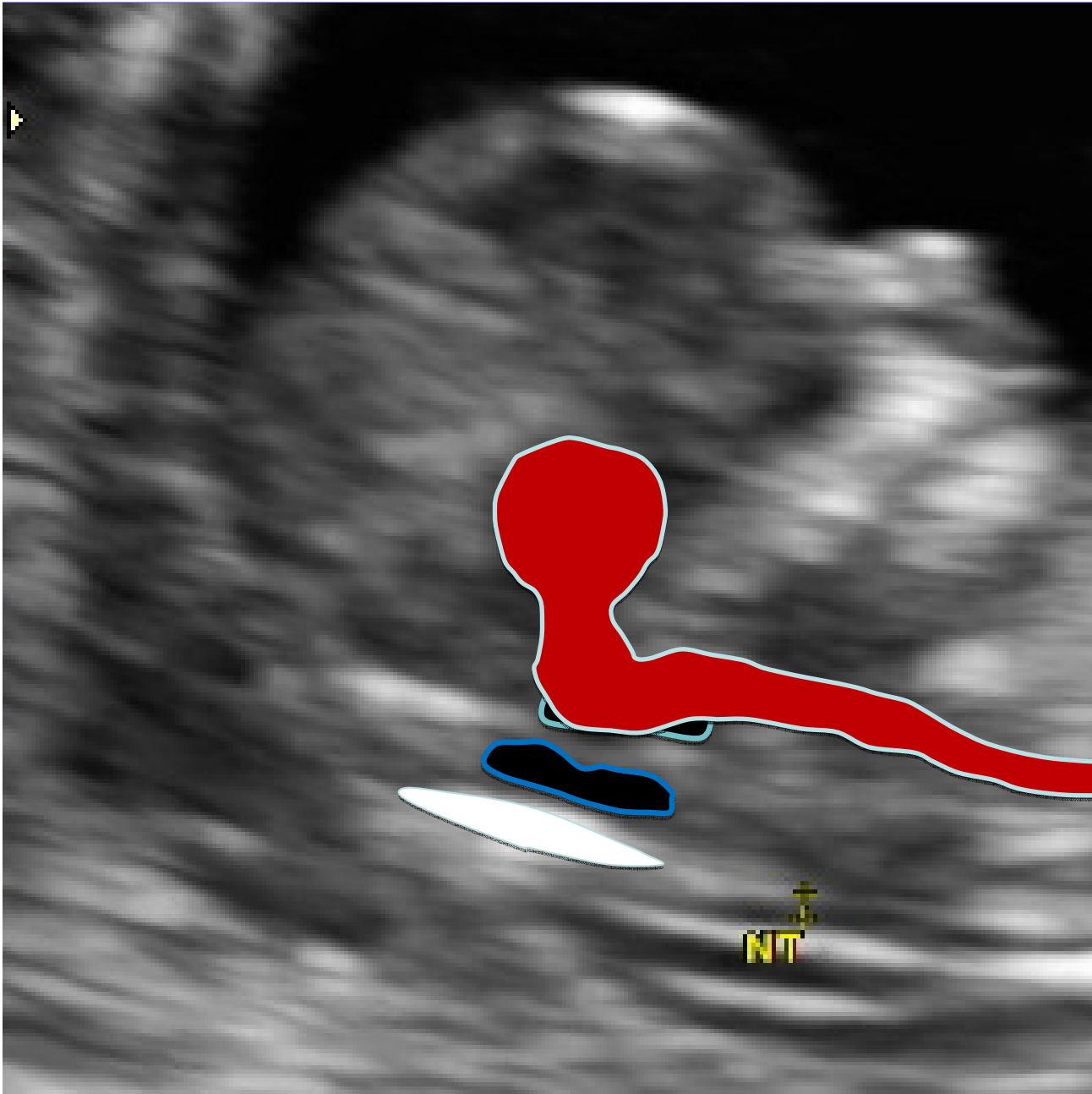
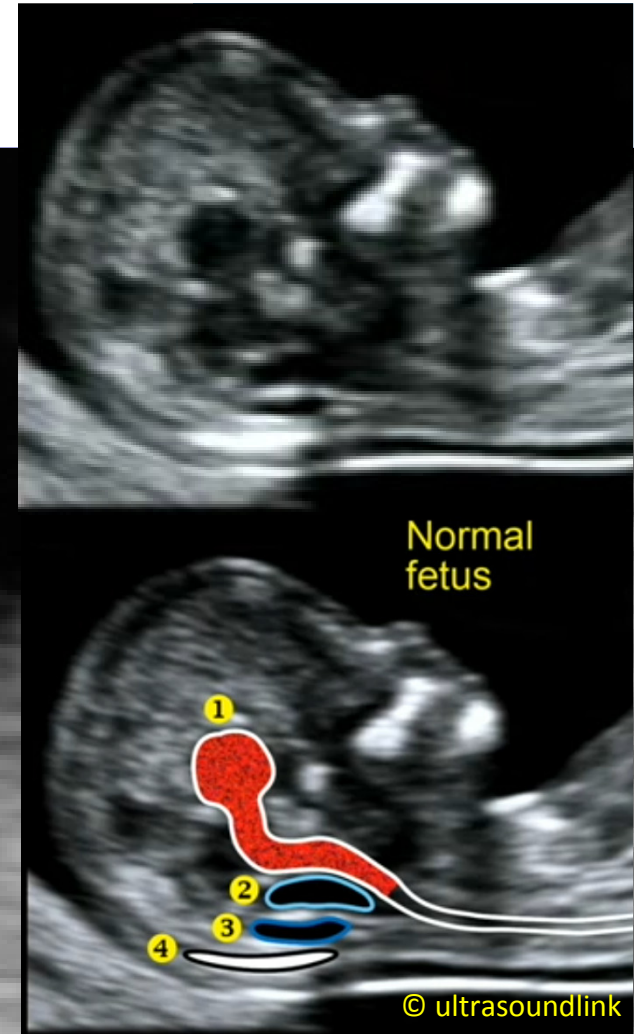


**15+1 SG**



- 1 Tronc de l'encèfal
- 2 IV ventricle
- 3 Cisterna magna
- 4 Occipital





- 1 Tronc de l'encèfal
- 2 ~~IV ventricle~~
- 3 Cisterna magna
- 4 Occipital