


# Ventriculomegalia Recidivant

## A propòsit d'un cas



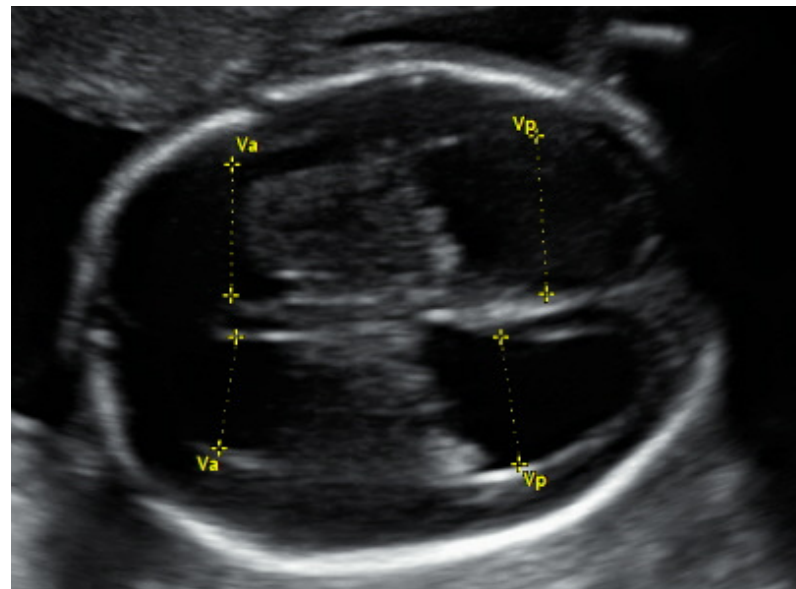
Yanira Romero,  
José de La Cruz, Begoña Muñoz, M. Montero, A.Zugazaga, Pere Cavallé

### Dona 38 anys

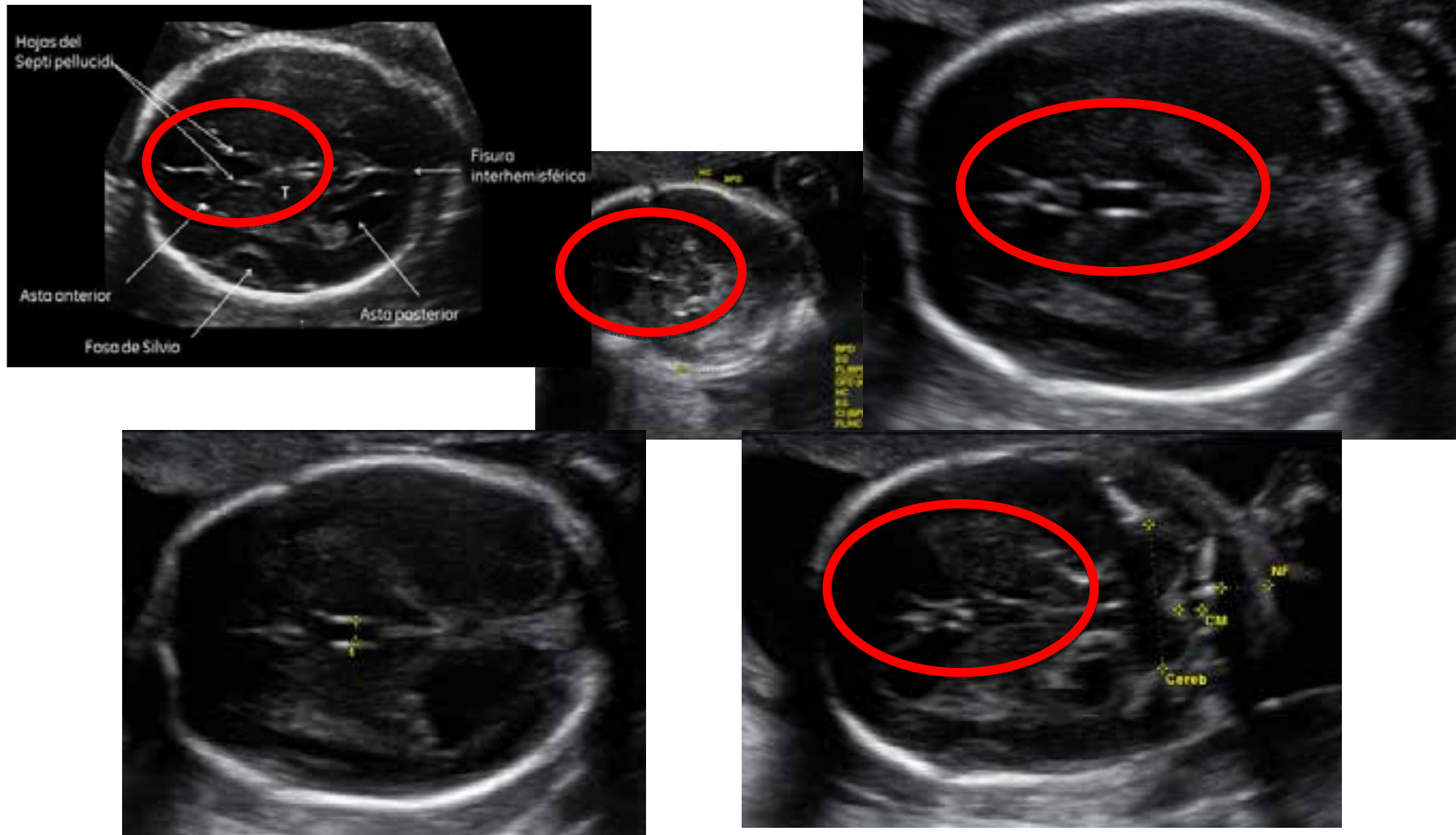
- Magrebí
- TPAL 3103
- Antecedent d'òbit fetal en tercera gestació. Ventriculomegalia amb placenta d'aspecte hipertròfic . Cariotip normal. Doppler uterines patològic. RCIU sever a les 22 , òbit a les 25 set).

### Gestant de 21 setmanes

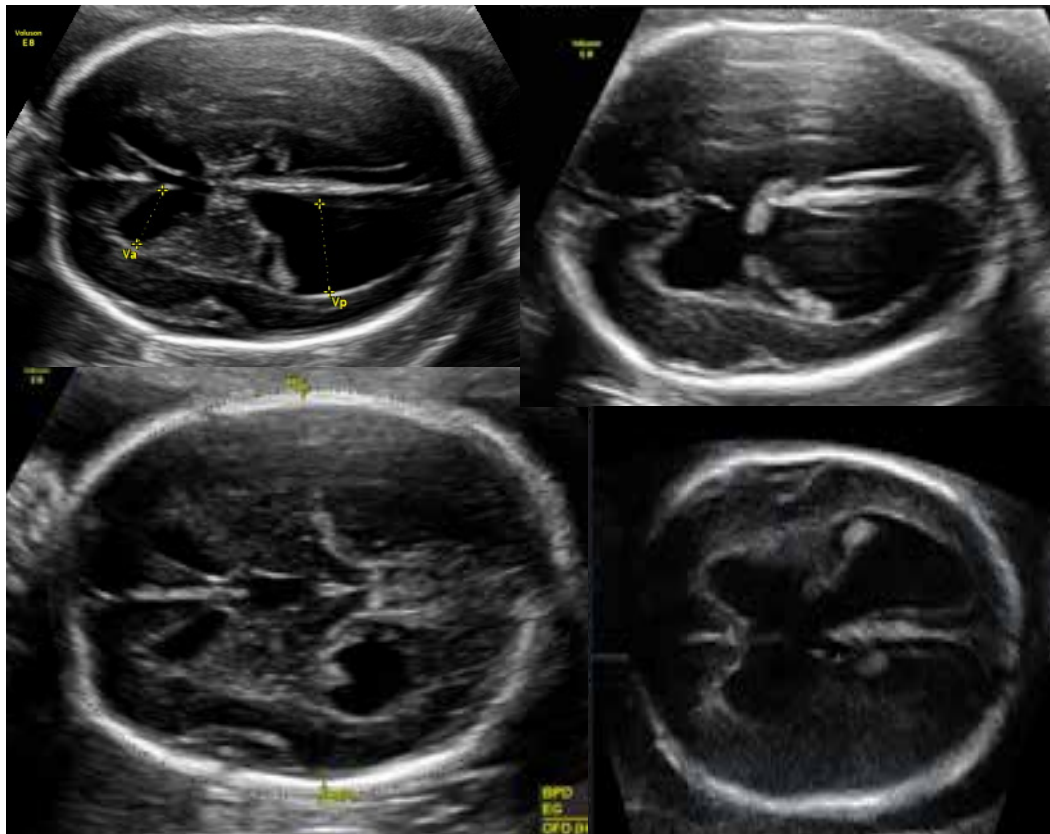
- Control ASSIR fins setmana 20. ( dins normalitat )
- A Positiu, CI negatiu.
- Hemograma normal.
- Rubeola immune.
- Toxoplasmosi immune.
- Sífilis negativa.HIV negatiu.



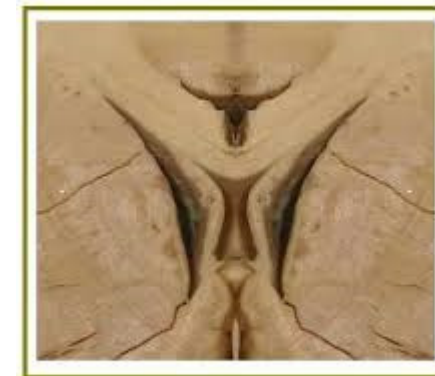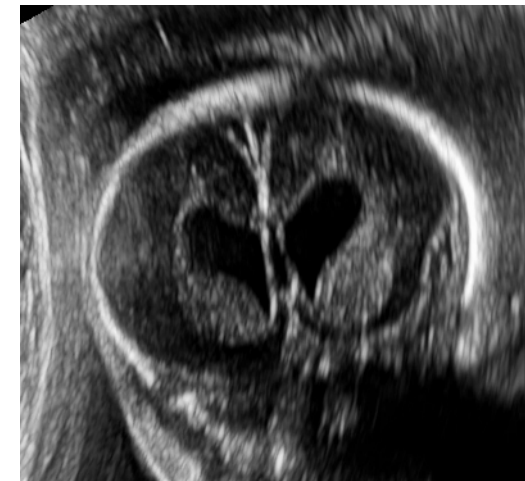**Pla axial**



### Pla axial

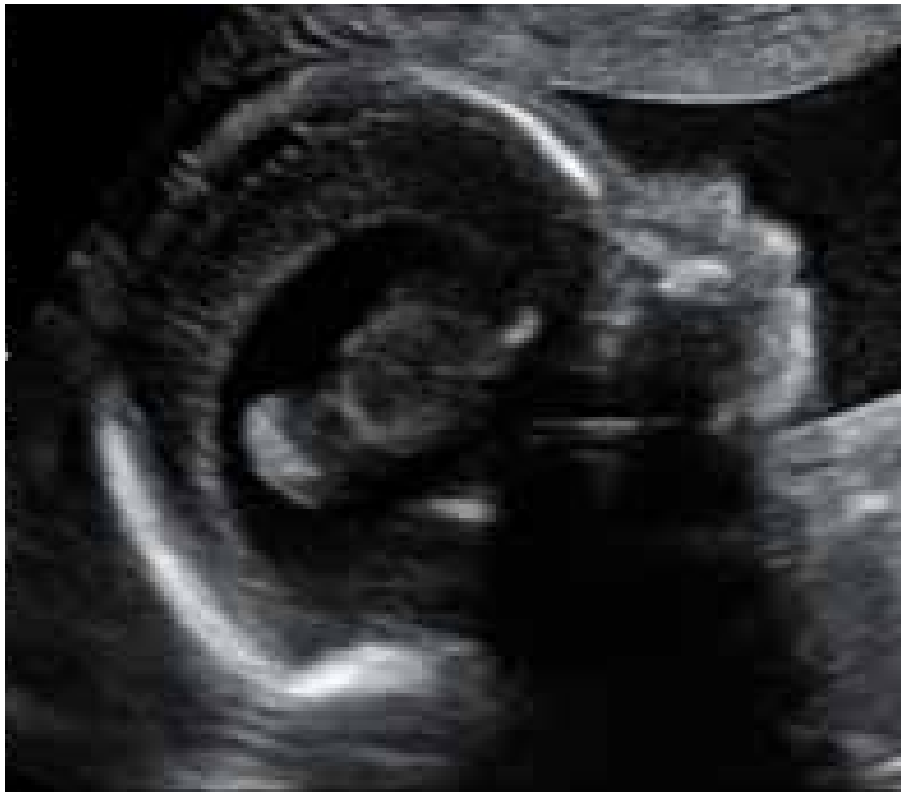

### Pla coronal

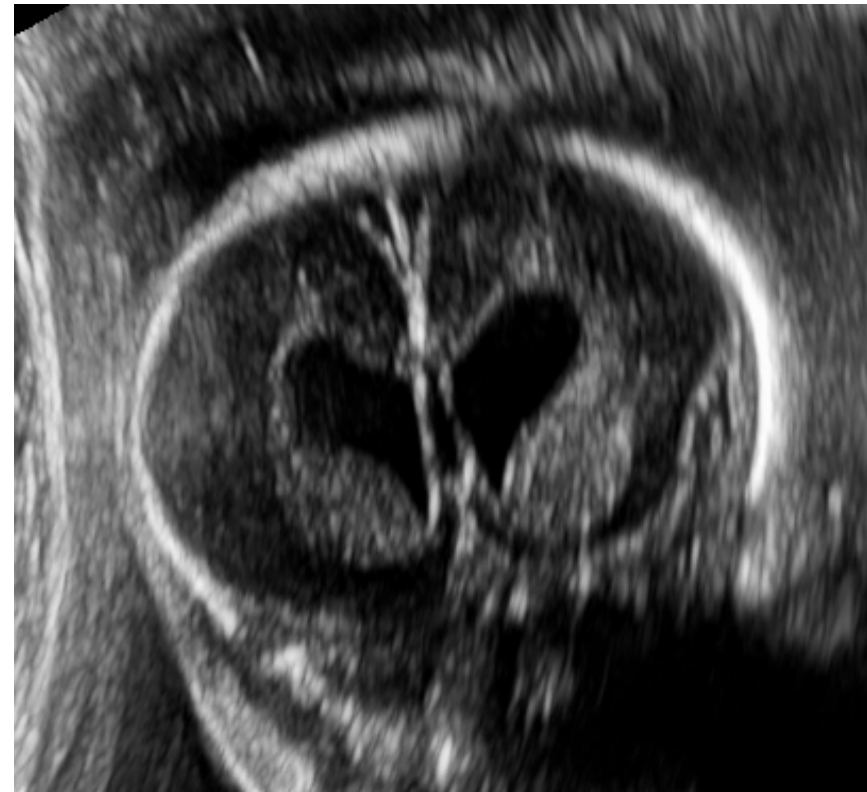

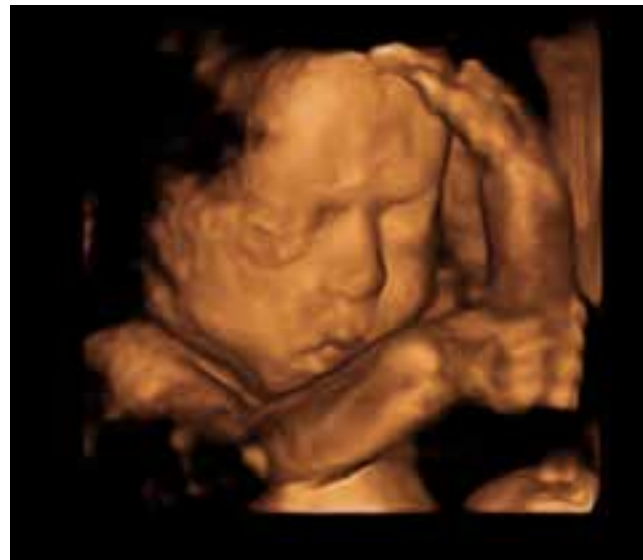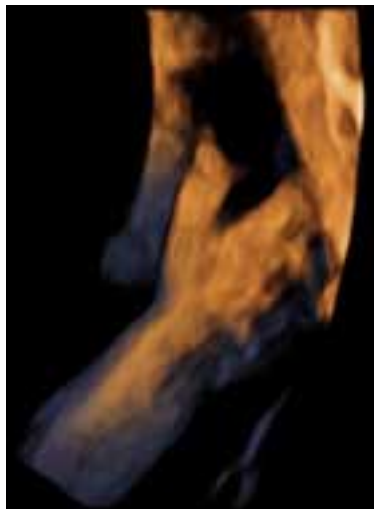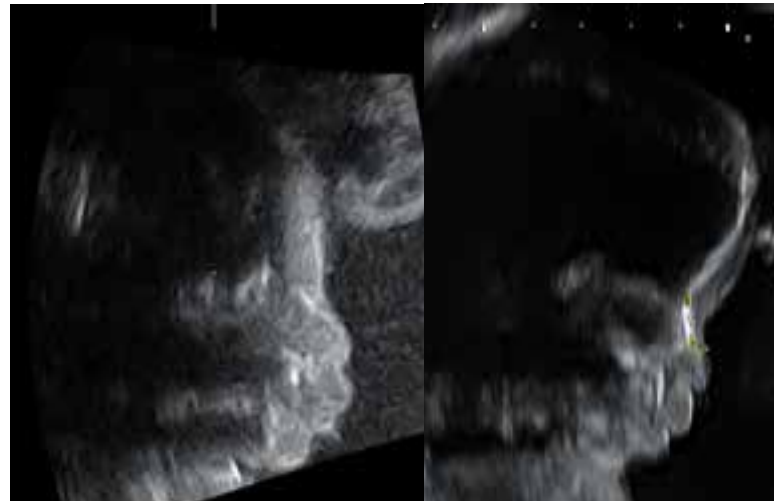
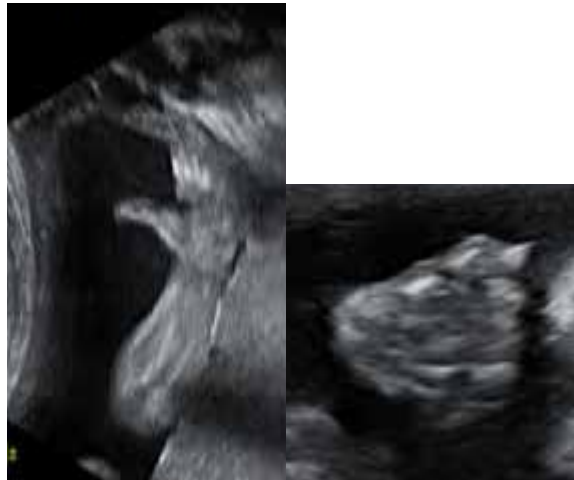*Notese la presencia de una cavidad entre las  
hojas del septum pellucidum denominada  
CAVUM.*

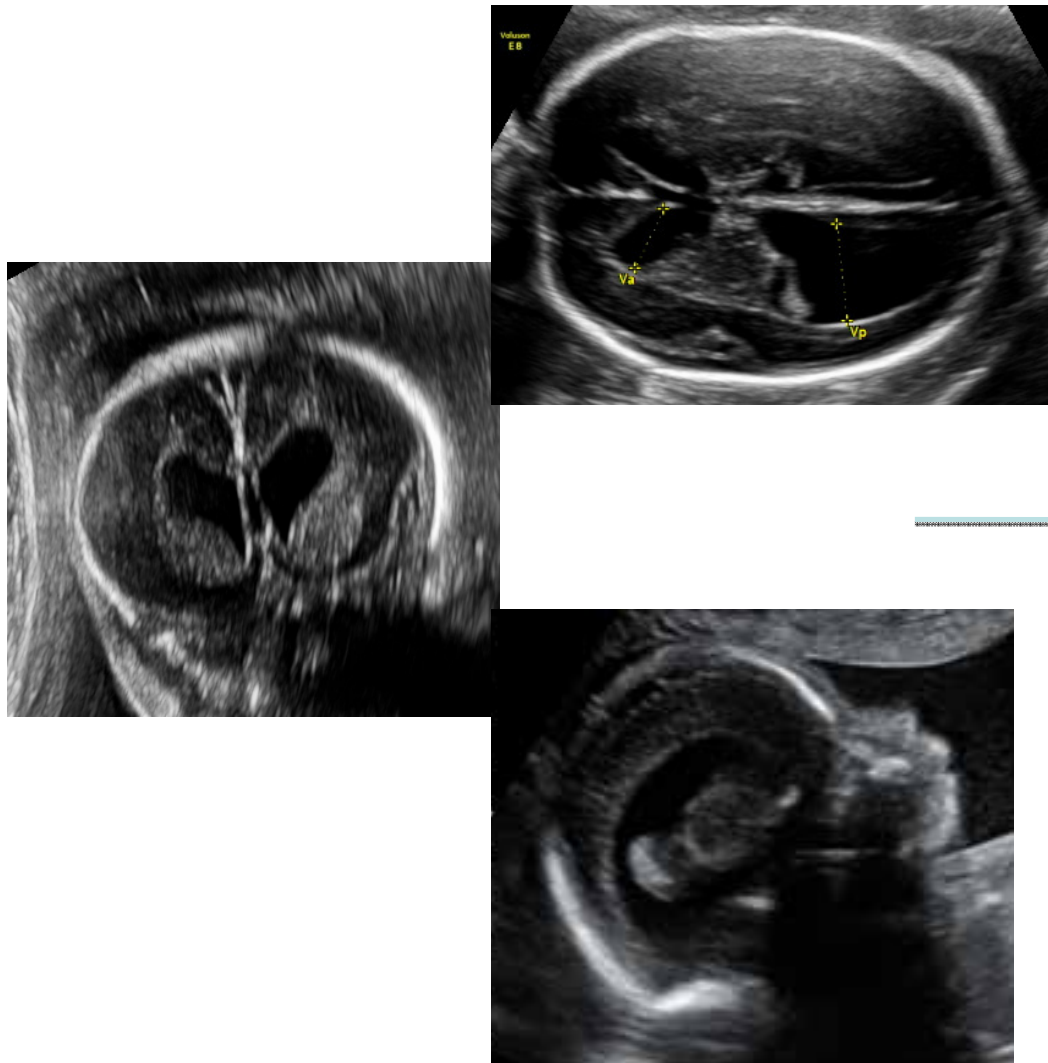
**Pla sagital**



**Pla coronal**







→ Ventriculomegalia bilateral

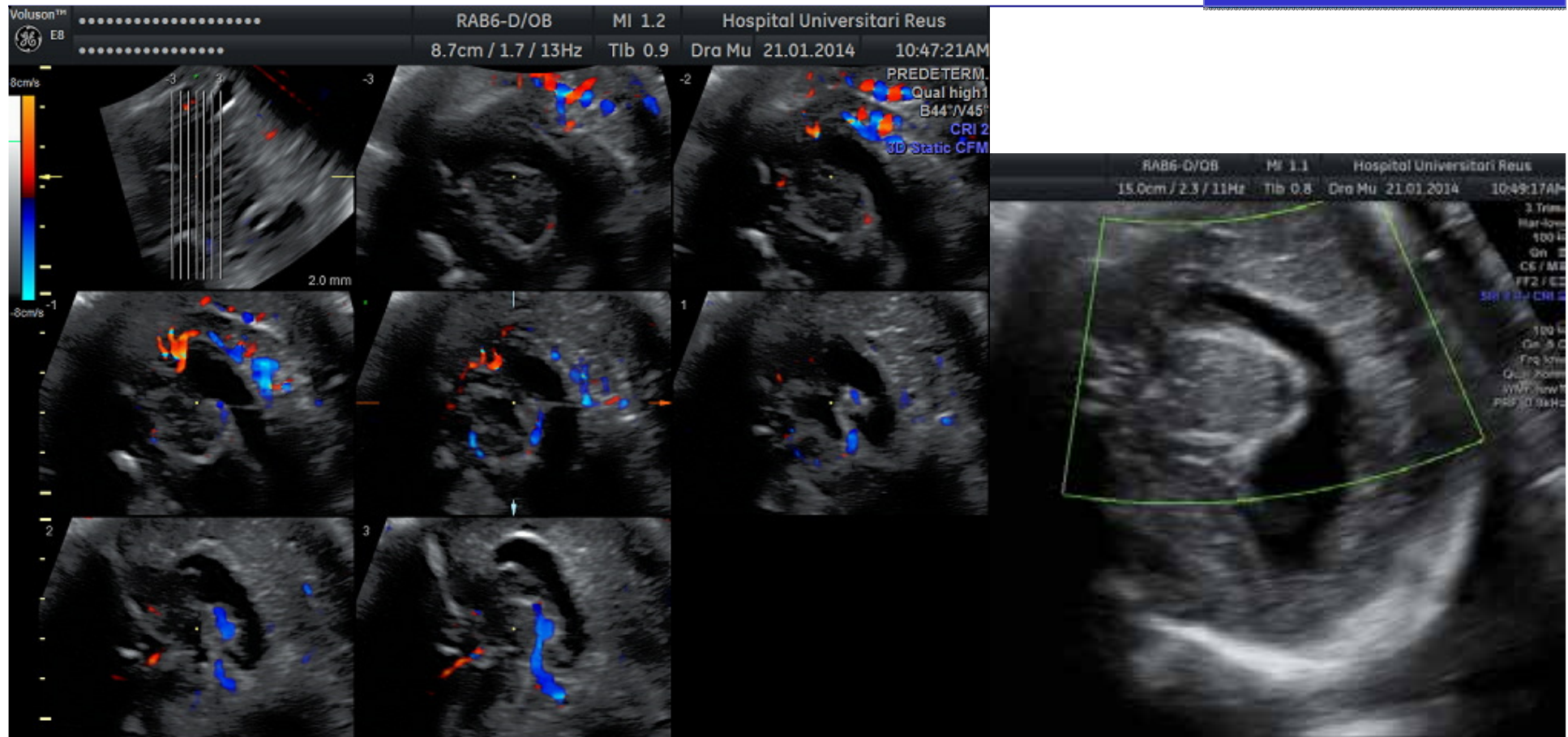
→ Anomalia del cavum septum pellucidum

→ Agenèsia –hipoplàsia cos callós

Cariotip fetal

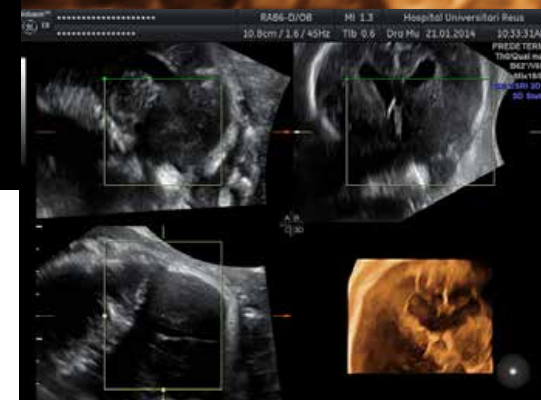
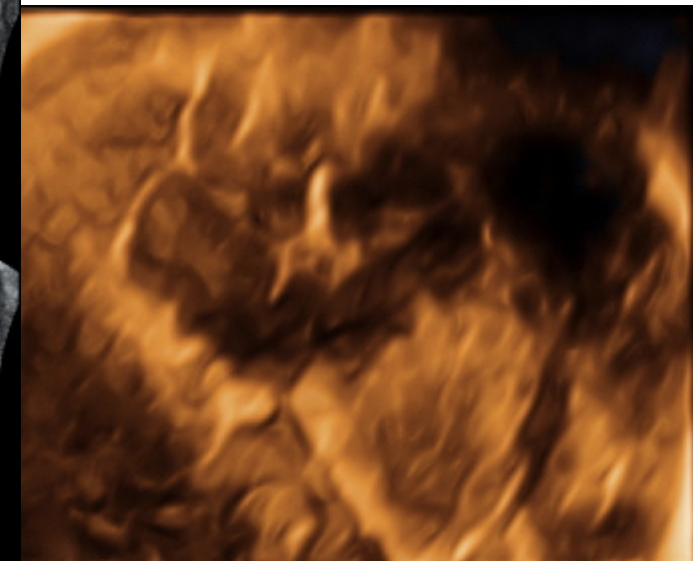
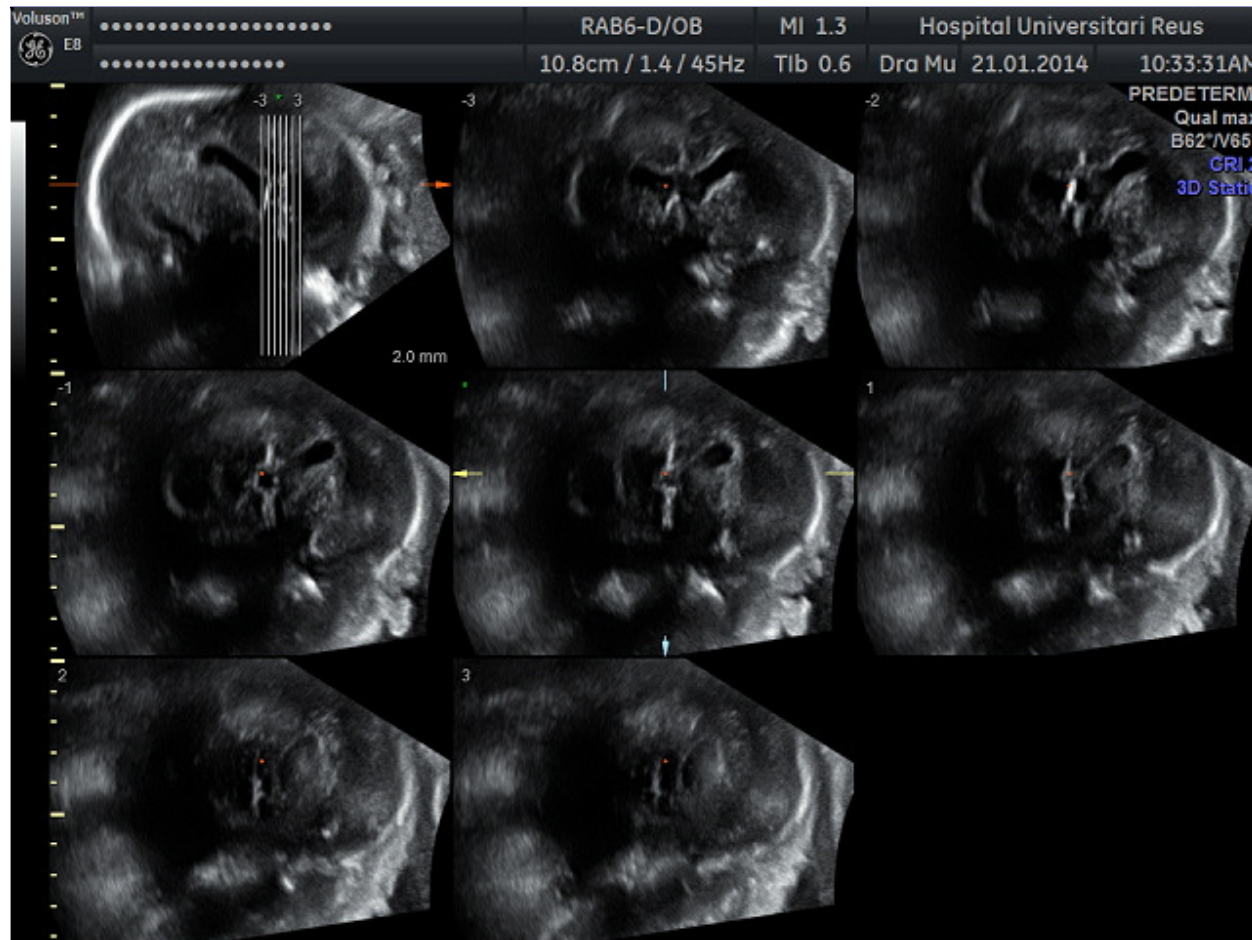Assessorament  
pronòstic fetal

Possibilitat ILE

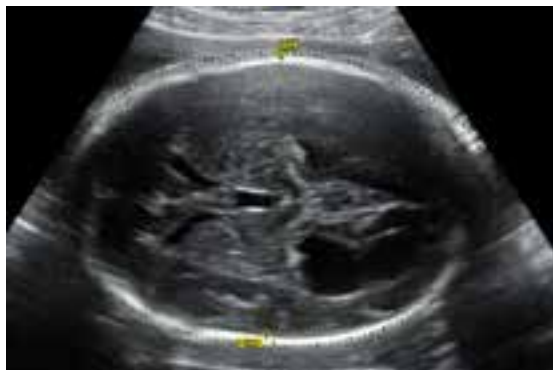
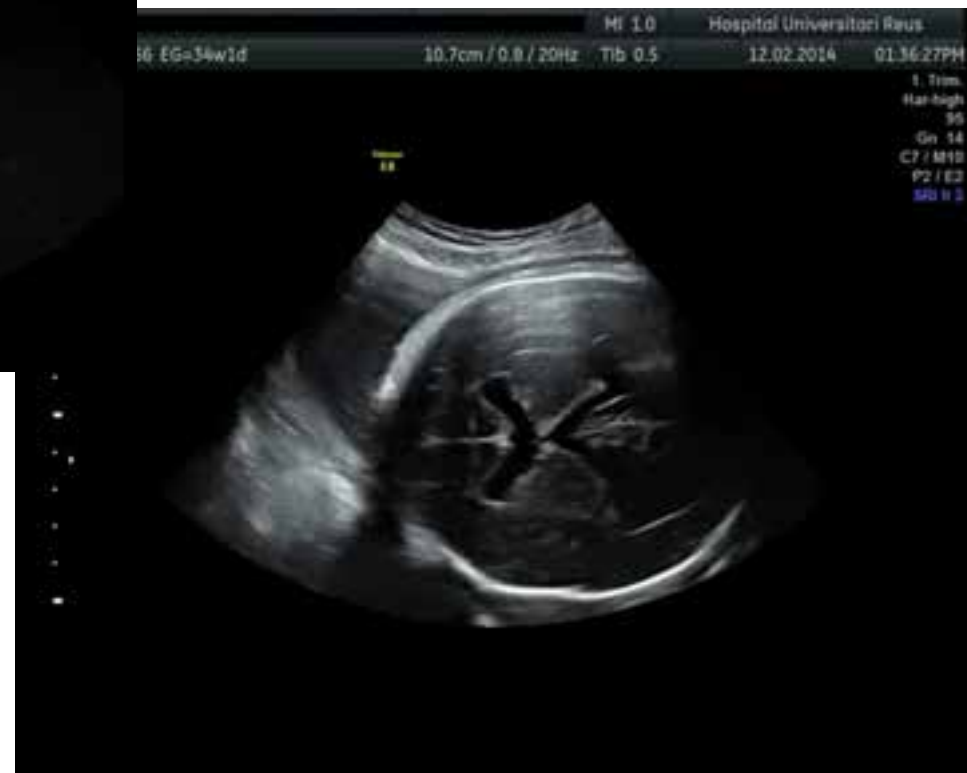
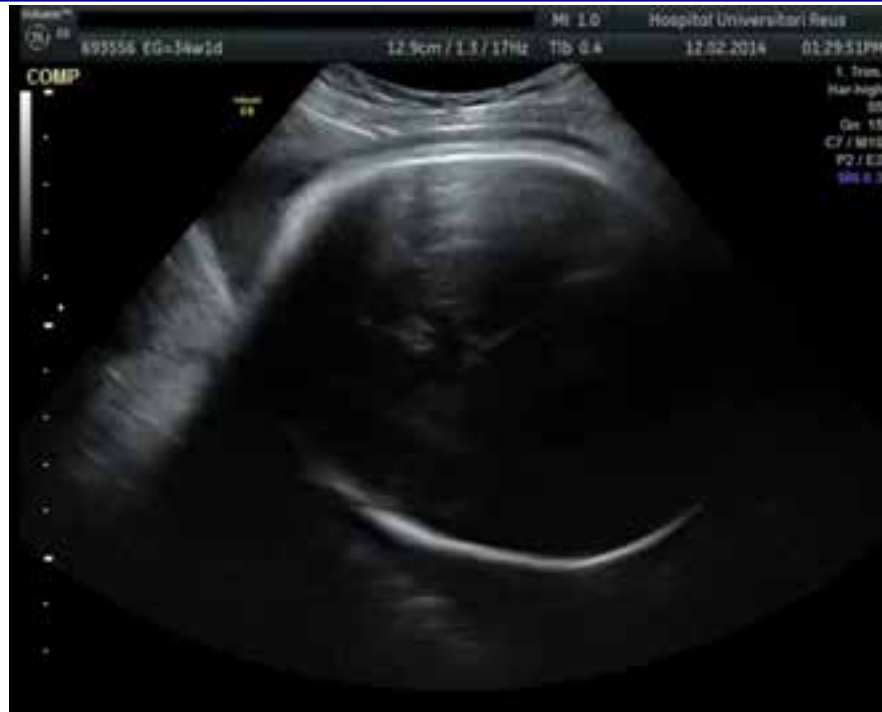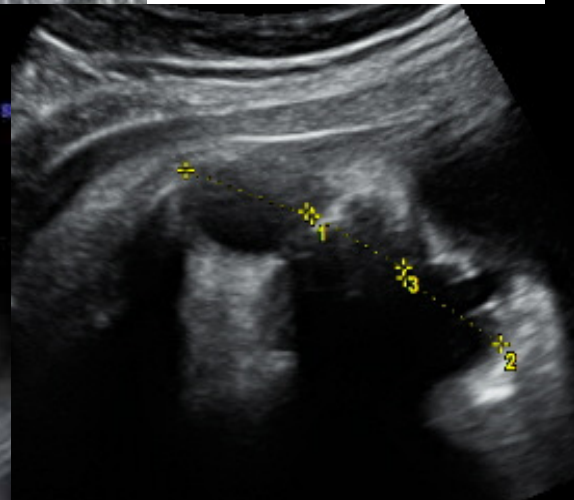
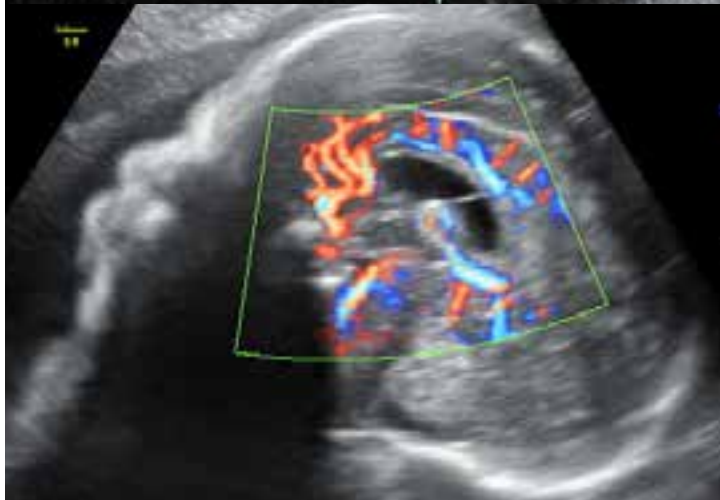
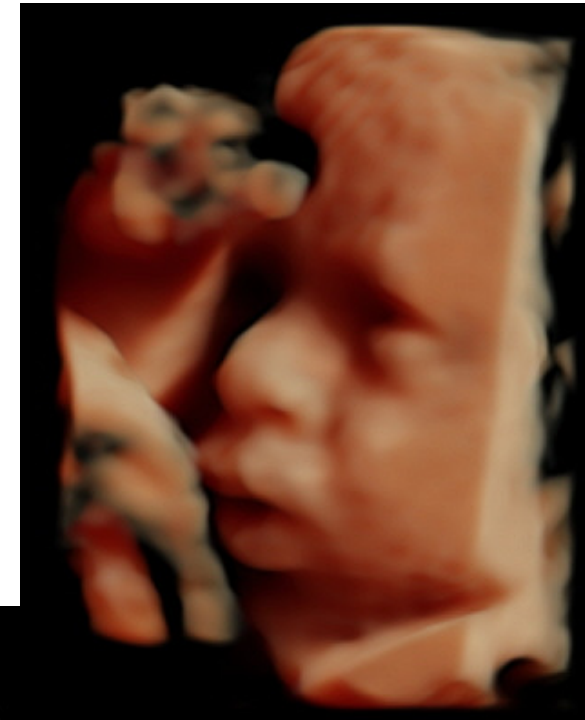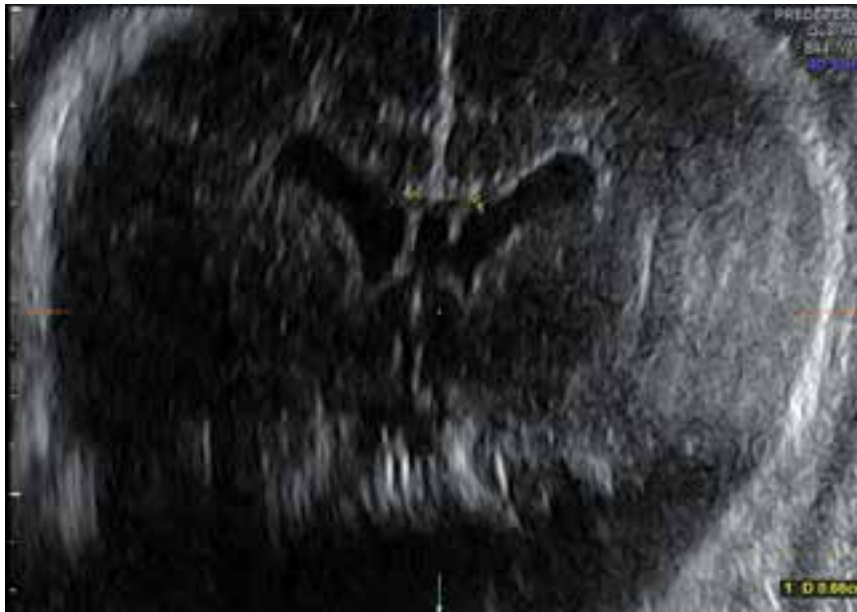
Agènèsia parcial - hipoplàsia cos callós



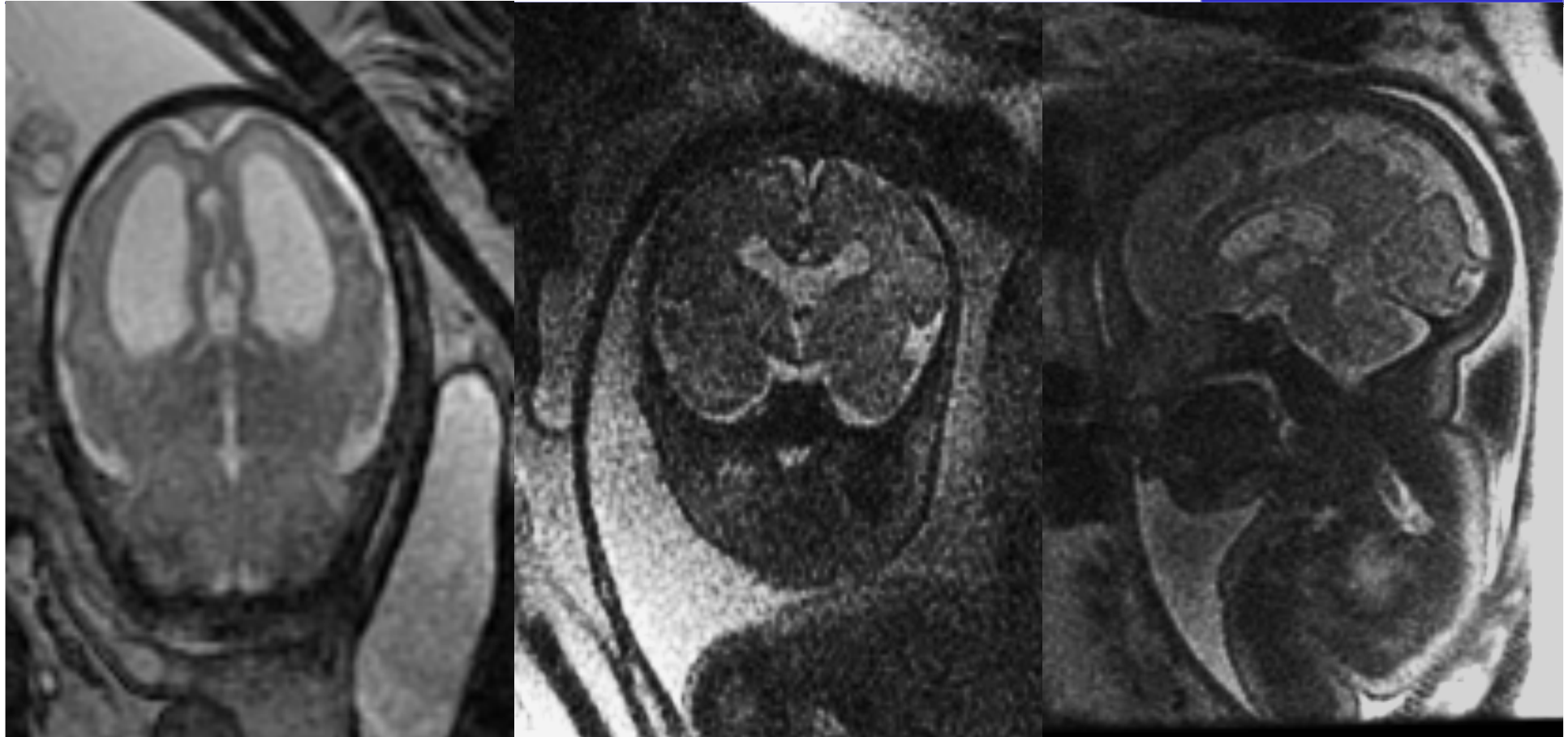


Anomalia del cavum septum pellucidum





Se sol·licita RNM



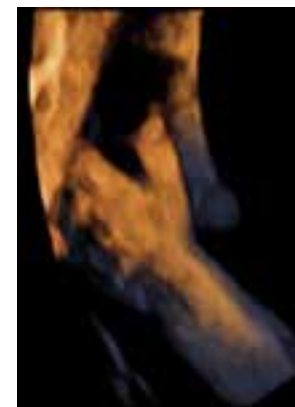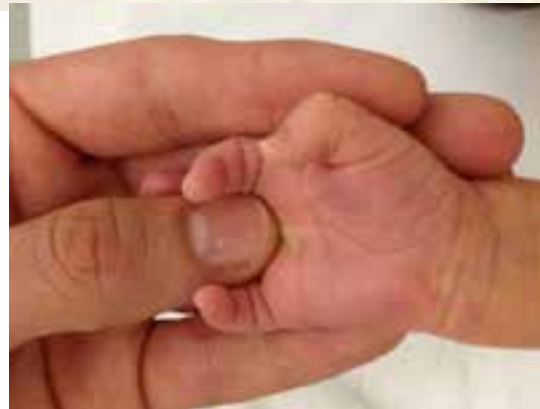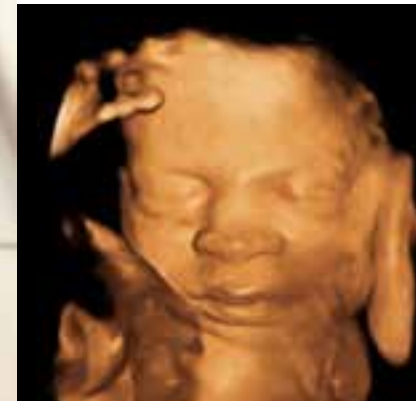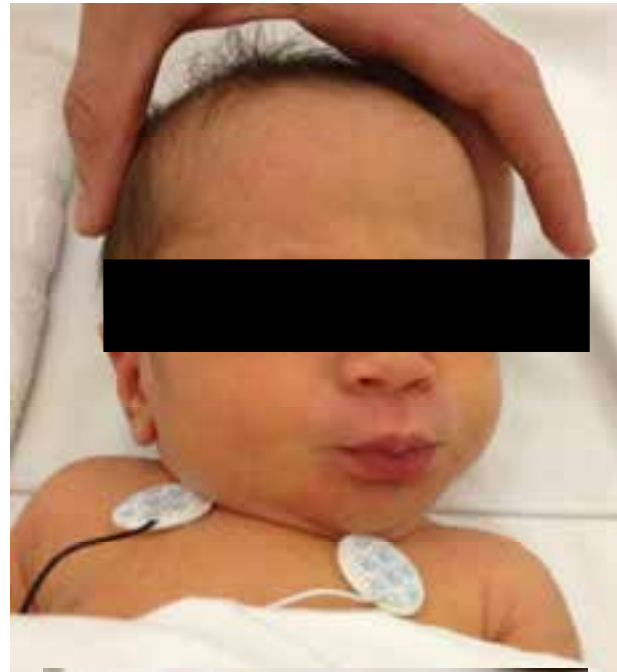Pla axial

Pla coronal

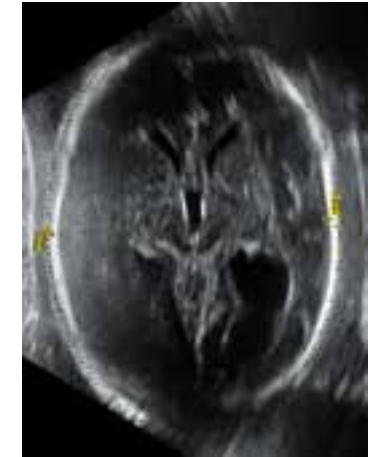
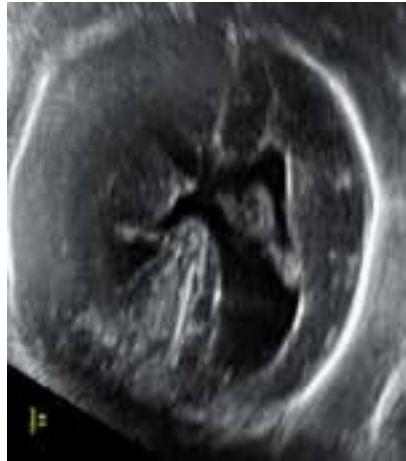Pla sagital

RNM Fetal

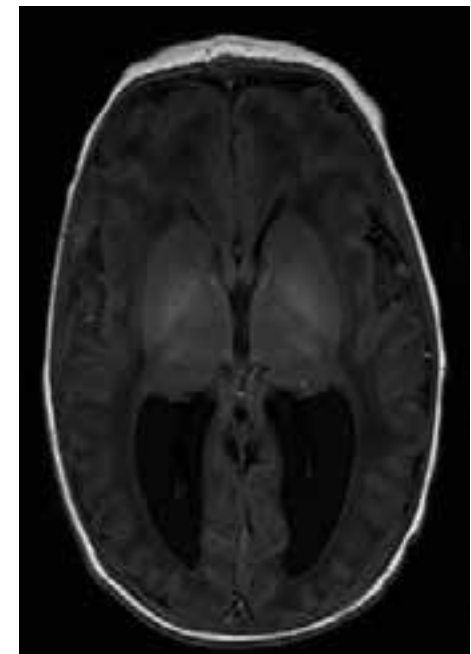
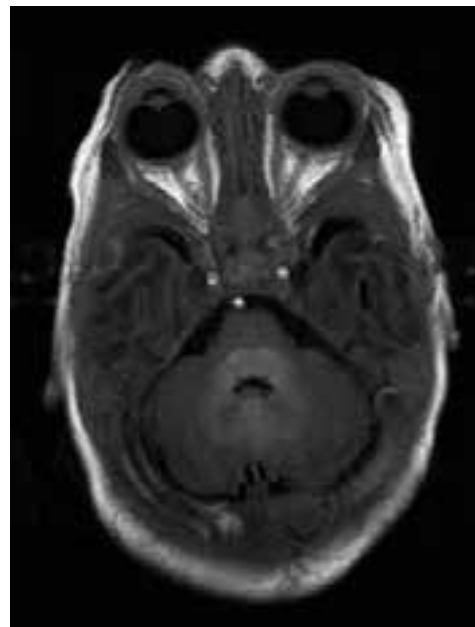
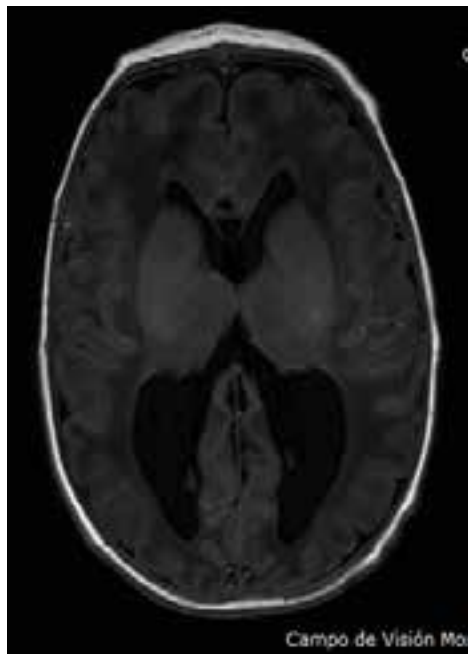
Part Eutòcic  
36,3  
Apgar 9/10/10  
Pes 3240 gr



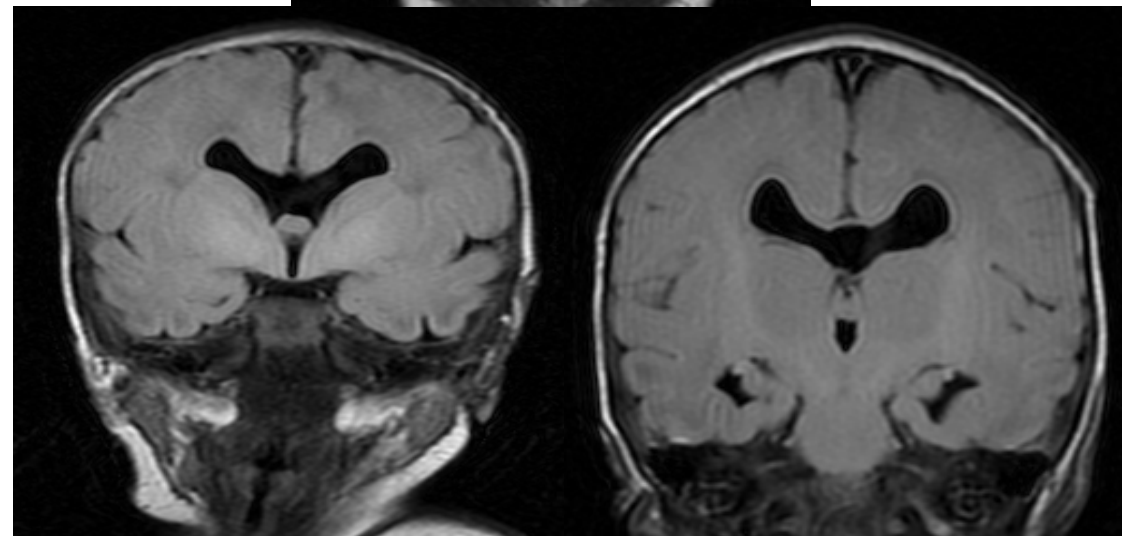
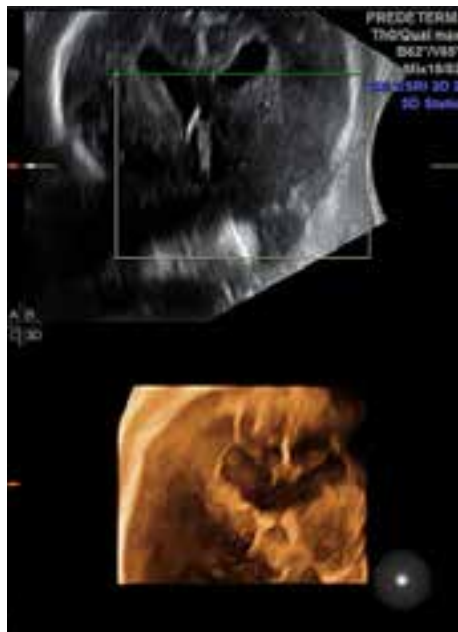
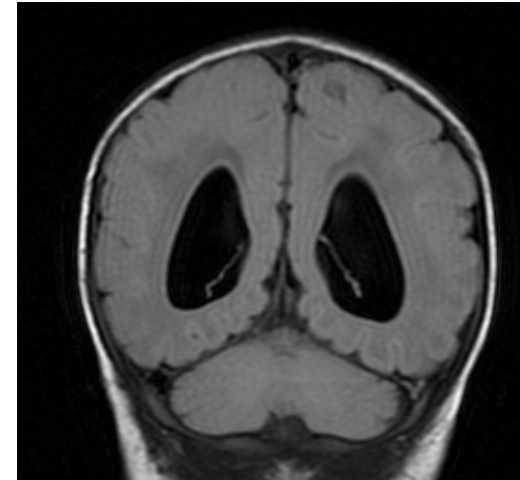
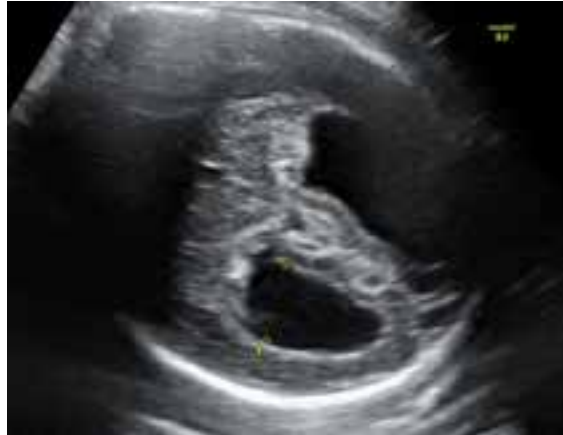Pla axial

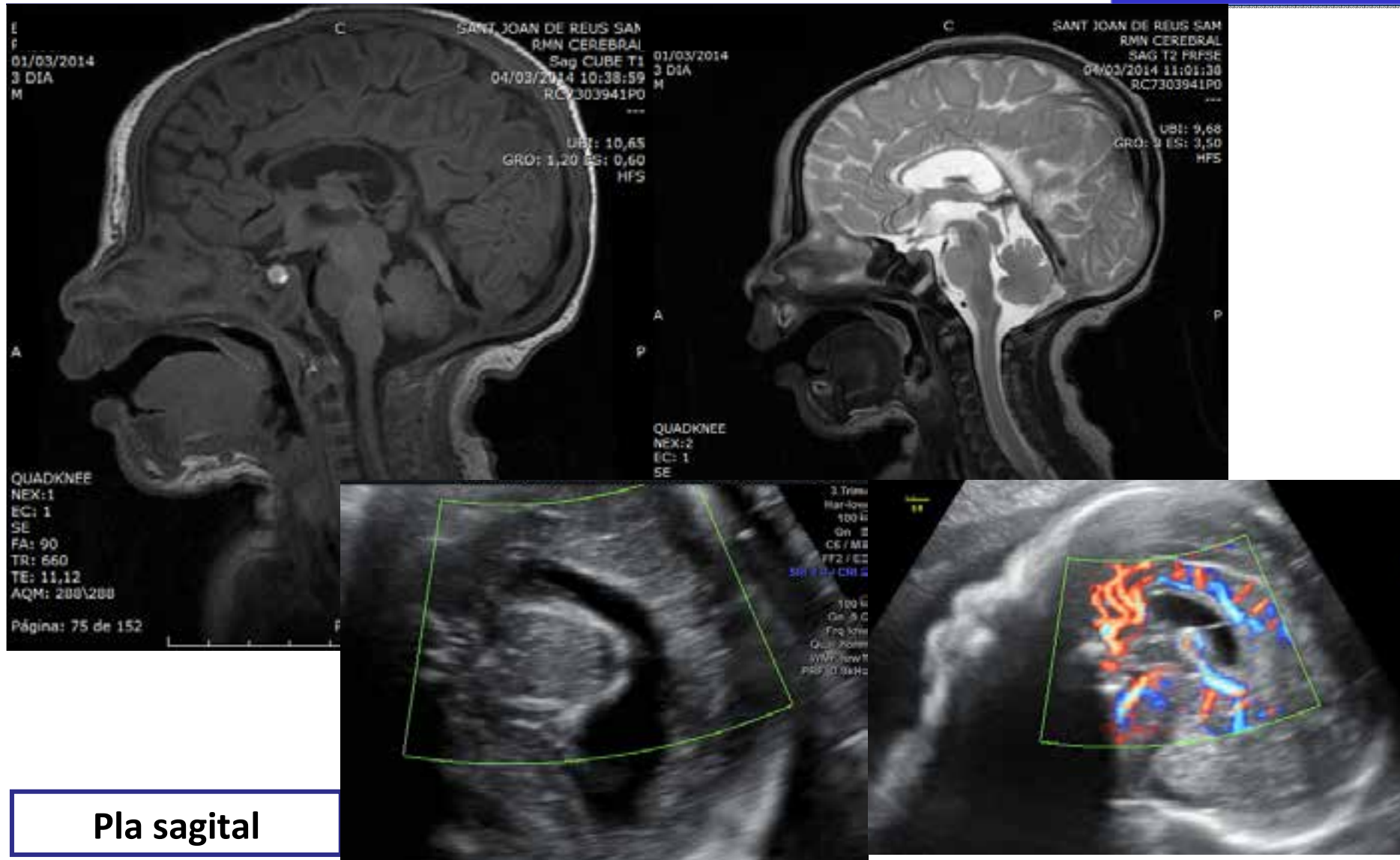


RNM postnatal



Pla coronal



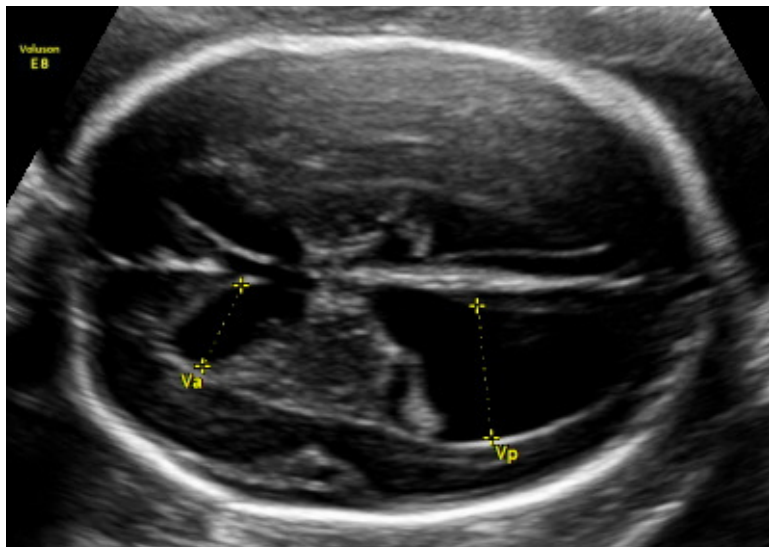


Pla sagital

Servei de Ginecologia i Obstetrícia



- TPAL 4104
- Antecedent d'òbit fetal en tercera gestació. Ventriculomegalia amb placenta d'aspecte hipertròfic . Cariotip normal. Doppler uterines patològic. RCIU sever a les 22 , òbit a les 25 set).



- Ventriculomegalia bilateral
- Absència quasi completa del cavum septum pellucidum
- Hipoplàsia cos callós



**Moltes gràcies per la vostra atenció**

**Servei de Ginecologia i Obstetrícia**